



Making the World a Healthier Place

THE SWISS BIOHEALTH CONCEPT®

2020

SWISS 
BIOHEALTH®
ACADEMY



- 1991** Youngest dentist in Germany to establish a purely private practice
- 1991** Dissertation on "Amalgam invasion in teeth"
- 1992** First fully ceramic inlays
- 1996** Certification as dentist specializing in naturopathy
- 1998** Certification as dentist specializing in implantology
- 1998** First fully ceramic zirconia crowns
- 1999** Establishment of Bodensee Zahnklinik AG and Bodensee Dentaltechnik AG
- 2000** Establishment of Medical Masters AG
- 2000** Development of first zirconia ceramic implants
- 2001** Establishment of Tagesklinik Konstanz
- 2003** Establishment of Z-Systems GmbH
- 2004** First CE certification for a ceramic implant
- 2004 -2012** Development of the first SDS2.0 two-part reversibly screw-retained ceramic implant
- 2006** Insertion of first implants with ultrasound using polylactide welding
- 2007** Establishment of SDS Swiss Dental Solutions AG
- 2008** Development of sonic weld membrane welding for GBR technology
- 2012 - 2014** Development of the SDS1.1 hybrid implant
- 2014** Chairman of the International Society of Metal-Free Implantology (ISMI)
- 2014** Development of the Dr. Volz SCC Short Cut Concept
- 2015** Formulation of the Dr. Volz Biological Dentistry concept
- 2016** Establishment of the SWISS BIOHEALTH CLINIC and development of the ALL IN ONE concept
- 2017** Establishment of the SWISS BIOHEALTH EDUCATION CENTER
- 2018** Establishment of SWISS BIOHEALTH VITAL and SDS Swiss Dental Solutions USA, Inc.
- 2019** Establishment of the SWISS BIOHEALTH ACADEMY and the SWISS BIOHEALTH STORE & CAFÉ
- 2020** Establishment of the SDS ACADEMY

Table of contents

| | | | |
|---|-----------|---|-----------|
| Changes in our environment | 4 | Single Shots | 40 |
| Chronic diseases | 4 | BTP Infusion | 40 |
| Mobile radio and electromagnetic fields | 5 | DAILY USE | 41 |
| | | Intestinal rehabilitation and amino acids | 41 |
| The correlation between dental stress and chronic diseases | 7 | Detoxification | 41 |
| The Heart Rate Variability | 7 | Additional measures | 41 |
| Sympathetic nervous system - | 8 | References | 43 |
| Parasympathetic nervous system | 8 | | |
| Stress | 8 | The importance of vitamin D | 47 |
| The importance of chronic inflammation | 8 | References | 51 |
| References | 10 | | |
| Some mechanisms of oral disturbances | 14 | Restoration | 56 |
| Silent inflammation | 14 | Restoration Sequence | 56 |
| Autoimmune diseases | 14 | Metal restoration | 57 |
| Retrograde axonal transport | 14 | Detoxification protocol | 57 |
| Allergies and intolerances | 14 | Amalgam removal | 57 |
| Root canal treatments | 15 | Removal of metal inlays | 58 |
| The meridian system | 16 | Explantation of titanium implants | 58 |
| What are interference fields? | 17 | FDOK | 58 |
| Interference field diagnostics | 17 | Wisdom teeth | 58 |
| Meridian system for self - analysis | 18 | Empty jaw sections | 62 |
| | | Ankylotic root-canal-treated teeth | 62 |
| Clinical diagnostics | 20 | Root canal treatment - extraction | 63 |
| Test - injection of 1% Procaine | 20 | Root infraction | 63 |
| OroTox® - Test | 20 | Densotomy | 63 |
| References | 21 | Separate removal of a cyst | 64 |
| | | Ozone treatment | 64 |
| Different materials with different effects on the body | 24 | PRGF, A-PRF, I-PRF | 65 |
| Amalgam | 24 | Ceramic implants | 67 |
| Dental metal alloys | 25 | Immediate implantation | 68 |
| Titanium implants or screws | 26 | Late implantation | 70 |
| References | 28 | Bone augmentation measures | 71 |
| | | Systemic conditions | 73 |
| Biological Dentistry | 32 | Local conditions | 73 |
| Biological dentistry versus | | Final restoration | 75 |
| holistic / naturopathic dentistry | 33 | Dental hygiene | 77 |
| The SWISS BIOHEALTH CONCEPT | 33 | References | 78 |
| The ALL IN ONE CONCEPT | 34 | | |
| MY BIOHEALTH WEEK | 35 | | |
| Diagnostics | 36 | | |
| Vitamin D3 | 37 | | |
| Vitamin K2/mk7 | 37 | | |
| The BASIC IMMUNE Protocol | 38 | | |
| Vitamin C | 38 | | |

Changes in our environment

If we take a conscious look at the global changes occurring in our environment, we notice some trends running in parallel: On the one hand, an exponential increase in the loss of intact ecosystems and the species they harbor. On the other, an exponential increase in chronic diseases and a similarly exponential increase in the strain on our immune systems. This is, however, being met by an exponential increase in organic nutritional and behavioral concepts.

Chronic diseases

Chronic diseases, such as cancer, Lyme disease, ALS, Alzheimer's disease, Parkinson's disease, MS, Crohn's disease, diabetes mellitus, bronchial asthma and chronic fatigue syndrome, are increasing at an explosive rate, and the extrapolation of the curves shows that within a few years, everyone living in the Western world will be affected by at least one of these diseases⁽¹⁾. Numbers among children are also on the rise, with one in every 59 eight-year-olds suffering from autism⁽²⁾.

Multiple sclerosis

In Germany alone, for example, the incidence of MS increased from around 100,000 cases per year to approximately 150,000 cases per year from 2004 to 2009. The annual incidence rate (number of new cases) in Germany is eight cases for every 100,000 inhabitants. Women are three times more frequently affected than men⁽⁴⁾. In the United States, with the introduction of copper amalgam in 1976, its incidence escalated from one year to the next, from about 8,000 new cases per year to 123,000 new cases⁽⁵⁾. Subsequently, the incidence rate for every 100,000 US citizens rose from 34.8 in 2001 to 46.3 in 2014⁽⁶⁾. In Norway, the incidence of MS rose from 1.9 to 8.0 for every 100,000 inhabitants, while the prevalence (number of sufferers) increased tenfold. Vitamin D deficiency is considered a risk factor⁽⁷⁾.

Amyotrophic lateral sclerosis (ALS) was virtually unknown 20 years ago. Today, its incidence worldwide has already increased to 2.6 individuals, with a prevalence of six, for every 100,000 inhabitants.⁽⁸⁾ Around 6,000 American citizens are diagnosed with ALS every year⁽⁹⁾. Northern countries are more severely affected, which could be indicative of the correlation with vitamin D3 deficiency. The number of deaths caused by ALS increases by 60% each decade. Most patients are given a life expectancy of two to five years⁽¹⁰⁾.

Comparing the rise in the ALS death rate^(Fig. 2) with the increase in root canal treatments reveals an alarming parallelism: Around one million root canal procedures were carried out in the US in 1975. It is estimated that the number of root canal procedures carried out in the US in 2006 was around 22.3 million and that more than 41,000 root canal treatments are still performed each day^(12,13). In Germany, around 7 million teeth were endodontically treated under public health insurance in 2017⁽¹⁴⁾.

Widespread chronic diseases also include autoimmune diseases. At present, an estimated 23.5 million Americans suffer from these diseases. In Germany, they affect around 5% of the population. Autoimmune diseases compromise almost every system in our body. They can affect the nervous system and mind (autism, depression), our joints, muscles, skin, hormonal glands, heart and other organs. The increasing burden posed by germs, environmental toxins, allergens, stress and poor diet are considered to be the cause⁽¹⁵⁾.

Thankfully, with the prevalence of chronic diseases veritably exploding, people are forced to adjust their mindsets and strive for a healthier, "organic" way of life: In standard supermarkets, organic products are, proportionally speaking, the best-selling products, with specialist organic shops such as "Alnatura" in Germany or "Whole Foods" in the US sprouting up left, right and center. Ever more restaurants' menus feature gluten-free dishes or dishes recognized as being healthy and free from additives. The reduction of harmful substances in textiles, the conservation of natural resources and success stories of the likes of Tesla's electric cars and many other examples all send a clear message. Even for the cigarette, a product quite obviously detrimental to our health, there is now an "organic" version of each brand. Just a few years ago, "American Spirit™" was the only brand in this segment.

What is interesting is that, nowadays, the profile of the "organic consumer" spans both the "esoteric environmentalist" and the social elite. Could it be that Darwin's principle of natural selection is once again at play? Unfortunately, with certain factors in our environment posing an increasingly acute threat to our health, this change in mindset is a matter of urgency. These threats include increasing electromagnetic radiation in the form of high gigahertz frequencies used in mobile communications, WLAN and DECT technology. The radioactive burden is also steadily increas-

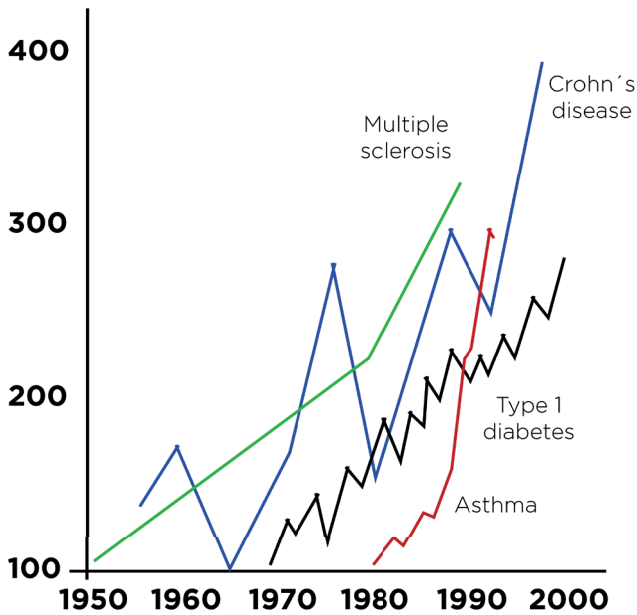


Figure 1: Increase in the incidence of immune disorders⁽¹⁾

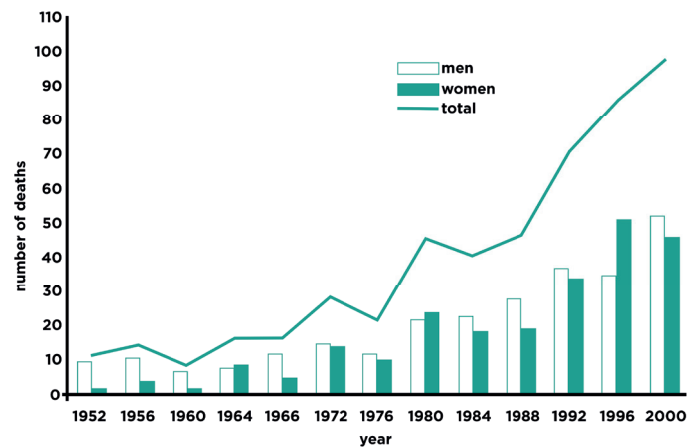


Figure 2: ALS deaths per year⁽¹¹⁾

ing, surging exponentially in the aftermath of accidents like Fukushima. Furthermore, the addition of titanium oxide (E171) to medicines, cosmetics, sunscreen, oral contraceptives, toothpaste, chewing gum and even food products, such as yoghurt, mozzarella, instant soup and sweets, is rendering titanium intolerance more widespread—a substance still widely used in implantology and traumatology^(16, 17). Yet, even in its purest form, “grade 1 titanium”, this chemical element still contains up to 0.20% iron⁽¹⁸⁾. It may also contain traces of nickel⁽¹⁹⁾. This is an alarming fact when you consider that, in Europe alone, around 65 million citizens are allergic to nickel⁽²⁰⁾. Nickel causes the greatest number of contact allergies. The 2007 REACH regulation attempted to protect the European population from high degrees of nickel exposure. Nonetheless, some 8–18% of citizens still incur allergic reactions to nickel. Women are more frequently affected than men⁽²¹⁾.

The alarming rise of chronic diseases is based on one common cause: the overwhelming increase in stress, which causes our immune system to shut down (Parasympathetic nervous system)^(22–24).

Apart from emotional stress, triggered by negative emotions in relationships, in work environments and our increasingly hectic lives, in which technology is omnipresent and we are expected to be permanently available, the second major factor is the exponential rise of artificial electromag-

netic fields (EMF). A study conducted in Swiss doctors' practices shows that the majority of chronic diseases were decreasing until the point of nationwide mobile network coverage, but have been increasing more and more ever since.

Mobile radio and electromagnetic fields

Children are especially vulnerable to mobile communications radiation and electromagnetic fields^(26–32). Exposure to electromagnetic radiation has been linked to all manner of illnesses including tumors of the brain and other organs, compromised sperm quality and oxidative stress^(33–44). The WHO also classifies high-frequency electromagnetic fields as potentially carcinogenic among humans⁽⁴⁵⁾.

The dangers of the 5G mobile communications network, set to be introduced in 2020 despite widespread criticism from scientists, are impossible to estimate. According to the current state of scientific knowledge, the German Federal Office for Radiation Protection (Bundesamt für Strahlenschutz, BFS) “does not anticipate negative health effects but does see some open questions”⁽⁴⁶⁾. The BFS bases its observations on just a few research results and highlights the need for additional research. On its website, the BFS warns against the possible effects on the skin and eyes of high-frequency electromagnetic fields in the milli- or centimeter-wave range, i.e. close to the body surface. It

seems no negative repercussions for inner organs are expected⁽⁴⁶⁾, although many studies have found evidence to suggest 5G, which is 1000 times stronger than 4G, will cause damage⁽⁴⁷⁻⁵²⁾.

The third stress factor—the major one for chronically ill patients—is the oral cavity and the teeth acting as a bioreactor for viruses, bacteria and fungi, and a source of toxins and inflammation mediators. Heavy metals in amalgam fillings and other dental alloys as well as allergens from plastic and alloy components may also have a pathogenic effect. This is exacerbated by the antenna effect of metal prosthetics, which can amplify the negative impact of electromagnetic fields—in immediate proximity to our central nervous system⁽⁵³⁾!

Cardiologist Dr. Thomas E. Levy, too, highlights the threat posed by dental nidi for the organism in its entirety. He sees increased intracellular oxidative stress as the cause of all illness. He considers chronic diseases to be most readily caused by infections (with the oral cavity accounting for over 95% of infections, and the sinuses, nasopharynx and upper respiratory tract being additional infection sites, plus bronchitis, appendicitis, ulcers, etc.), chronic pathogenic bacterial colonizations (e.g. of the sinuses or the pharynx), toxic burdens (e.g. heavy metals and pesticides), toxic iron levels, poor diet or digestion and hormonal imbalances.

Germs from the oral cavity are a burden on the whole organism. Several studies have demonstrated the pathogenic effect of the parodontal marker germ *Porphyromonas gingivalis* in the event of gastrointestinal, oral cavity and pancreas carcinomas⁽⁵⁴⁻⁵⁶⁾. This and other oral pathogenic germs have also been connected to cardiovascular diseases. They have been found in the breast tissue of women suffering from malignant diseases as well as Alzheimer's patients' brains⁽⁵⁷⁻⁶³⁾.

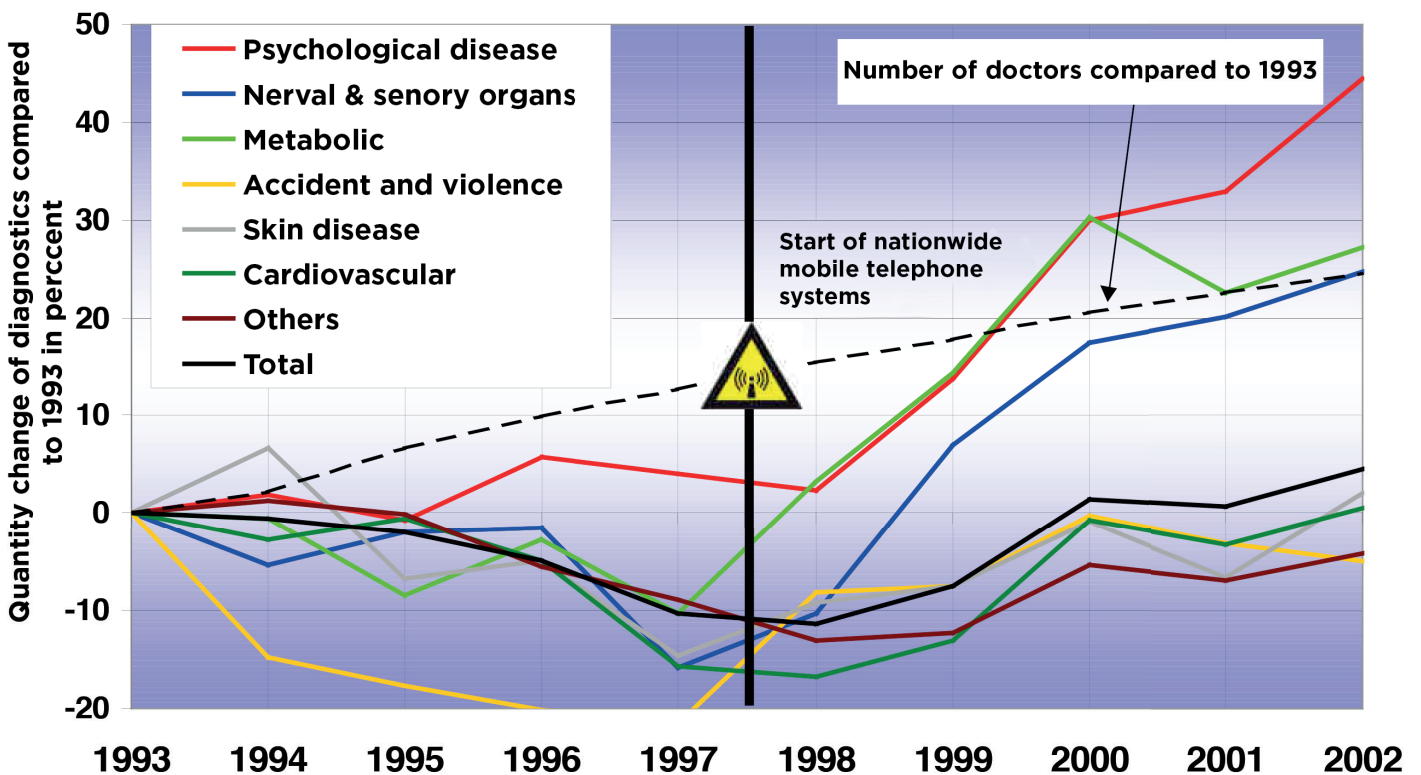


Figure 3: Diagnoses in Swiss doctors' practices⁽²⁵⁾

The correlation between dental stress and chronic diseases

The above insights demonstrate that our altered way of life calls for new concepts in dentistry and medicine. This includes reducing the surface area susceptible to interference from environmental factors by removing any dental metal and significantly relieving the burden on our body's ability to self-regulate through restoration and healing any chronic inflammation of the masticatory system. In the author's experience, consistently abiding by these principles will result in an improvement of health for almost every patient. Patients very often feel the benefits whilst still in the dentist's chair at the end of a treatment session (see testimonials on www.swiss-biohealth.com). When the last bit of metal has been removed, patients very often say that they feel as if a "helmet has been taken off" or that a "thick piece of glass has been removed from in front of their face". After nidi of chronic inflammation, such as osteitis of the jaw, cysts, or root-canal-treated teeth have been removed, patients very often experience an immediate improvement in their musculoskeletal system. For example, they may suddenly be able to move their arm without pain.

The Heart Rate Variability

Heart rate variability (HRV) is a key marker of the vegetative nervous system. It describes the heart's ability to vary the interval between one heartbeat and another, adapting to continuously changing challenges. As early as 300 A.D., Wang Shuhe, a doctor, recognized the following: "If the heartbeat gets as regular as the knocking of the woodpecker or the dripping of the rain on the roof, the patient will die within four days"⁽⁶⁴⁾. A high HRV indicates good adaptability and health. A low HRV is correlated with various physical and psychological pathologies, such as cardiovascular diseases, carcinomas, stroke, diabetes, nephritis, neuropathy and chronic stress⁽⁶⁴⁻⁶⁶⁾. Patients at our clinic are routinely HRV tested before and after each treatment. We usually see an improvement in HRV as soon as the interference fields have been eliminated.

How can these correlations be explained?

A manifest chronic disease presents itself as a structural disorder (growth of tumor tissue, changes in vessels, changes in tissue chronically susceptible to inflammation, bone or cartilage anomalies, muscular atrophy, etc.). This constitutes a pathological anatomical change. The structural disorder, however, is always preceded by a functional disturbance (impaired cell division, deficiency or surplus

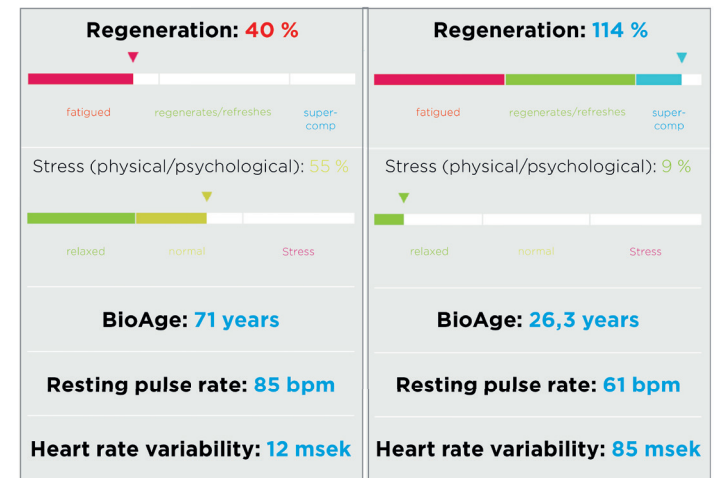


Figure 4: The Heart Rate Variability (HRV) measurement taken prior to and after surgery removing multiple dental sources of disturbance shows an impressive reduction in stress and significant improvement in regeneration and the patient's biological age.

states within cells, poor/compensatory posture), which, in turn, is triggered by a regularization disturbance (due to hyperacidity, cellular stress, oxygen deficiency, vitamin and nutrient deficiency, inflammation, toxins, bacteria, allergens, etc.). Clearly, a treatment that tackles the end of this chain cannot promise a great deal of success, because the functional and preceding regularization disturbances are maintained and will even be put under additional strain if the structure is operated on (e.g. immune suppression in the event of in an operation). The main problem lies in the fact that our lifestyles and contemporary environmental burdens result in such multi-layered stress that our immune and regeneration systems are hugely compromised⁽⁶⁷⁾. Not only does stress block these systems, but also, it consumes large additional quantities of nutrients and vital substances, further exacerbating the deficiencies we have: A vicious circle if ever there was one^(23,68). The underlying mechanism is an imbalance in the regulation of the vegetative, autonomic nervous system. The aforementioned stress factors lead to a dominance of the sympathetic nervous system to the detriment of healing processes, which may become blocked entirely.

Sympathetic nervous system - Parasympathetic nervous system

The stress response controlled by the sympathetic nervous system is a vital physiological reaction of the autonomic nervous system (which we cannot consciously control) that serves to keep us alive. The release of adrenaline, noradrenaline and cortisol triggers our flight-fight-freeze response within fractions of a second, as the amount of oxygen and nutrients in our blood and tissue increase within the skeletal musculature. Our heart rate rises, blood vessels narrow and blood pressure increases. Breathing is intensified to gain more oxygen. Our body is supplied with energy thanks to the release of fatty acids from our fatty tissue and of glucose from our glycogen reserves. To compensate, the digestive and immune systems need to be inhibited: The intestinal muscles are relaxed and digestion repressed, and the thymus gland, the spleen and the lymph nodes decrease antibody production.

Tissue inflammation is inhibited, benefitting pathogen distribution the longer the situation persists. Our core body temperature is increased and sweat production concomitantly stimulated in order to counteract overheating. Our pupils dilate as this expands the field of vision by around 10%, making it easier to perceive enemies or means of escape. Our kidneys retain water, while the salivary glands (dry mouth) and sex organs are inhibited. Our entire metabolism and physiology are focused upon a single objective: to bring the acutely life-threatening situation to an end as quickly and successfully as possible⁽⁶⁹⁻⁷¹⁾.

If these useful physiological mechanisms caused by the activation of the sympathetic nervous system are sustained for a longer period than evolution intended, this results in huge regularization disturbances, which, in turn, lead to functional disturbances and also, in the long term, to structural disorders. When cells are deprived of oxygen and hyperacidic, we incur cellular and tissue damage and may even develop cancer. In 1931, Otto Warburg won the Nobel Prize for proving the cellular mechanisms underlying cancer development, which dictate that a cancer cell cannot survive in an alkaline, oxygen-rich environment⁽⁷²⁾. It is not until the period of stress is over, switching the vegetative nervous system into the parasympathetic nervous mode, that the immune and regeneration systems can resume their physiological activities and healing mechanisms can be reactivated. Hence, the most important part of compli-

cation-free healing after surgery is that patients do everything they can to activate the parasympathetic nervous mode. This includes taking a "digital sabbatical" of at least five days after surgery.

Stress

Unfortunately, in addition to the genuine stress evolution has accommodated for, which usually only lasts for a very short time and can nowadays be triggered by an accident or an attack, we also experience longer-lasting stress. This kind of stress was foreign, or at least very rarely encountered, by the humans of the past, which is why our physiological system simply is not prepared for it. This includes physical (physiological/biochemical) stress: This can be caused by metals in the oral cavity, particularly heavy metals (e.g. mercury from amalgam fillings), toxins from root-canal-treated teeth and allergens from filling materials, but also by our diet (e.g. gluten)⁽⁷³⁻⁷⁶⁾. Being overweight or deficient in nutrients such as magnesium or vitamin D3, being unfit, having a generally poor diet, experiencing sleep deficiency and being exposed to electromagnetic fields (EMF) all increase such physical stress⁽⁷⁷⁻⁸⁰⁾. Psychological stress is stress we generate ourselves and arises as a result of fears and images in our brain: "I've lived through some terrible things in my life, some of which actually happened!" (Mark Twain). These psychological powers, however, can also be used to benefit our health⁽⁸¹⁾. Emotional stress and health issues are triggered by stressful relationships at home or at work, as well as by places and situations (traffic jams, loud noise, air pollution, etc.)^(67, 82, 83).

The importance of chronic inflammation

The immune system, along with its primary organs, the spleen and lymphatic systems, works locally and systemically with the help of immune cells and neurotransmitters that are dispersed via our blood and lymphatic vessels. Its functions are influenced and precisely regulated not least by the autonomic nervous system (sympathetic and parasympathetic nervous systems). The immune system is designed to react to pathological processes and pathogens like bacteria with acute inflammation, which overcomes these as quickly and effectively as possible. This also inhibits autoimmune processes. Energy is made available as glucose and fat, and a catabolic state is triggered in order to regulate the inflammation process down again as quickly as possible. The entire inflammation process is steered by the

autonomic nervous system on the one hand, and hormonally via the hypothalamic-pituitary-adrenal axis (HPA axis) on the other. Acute inflammation is accompanied by increased systemic sympathetic nervous system and reduced parasympathetic nervous system activity⁽⁸⁴⁾.

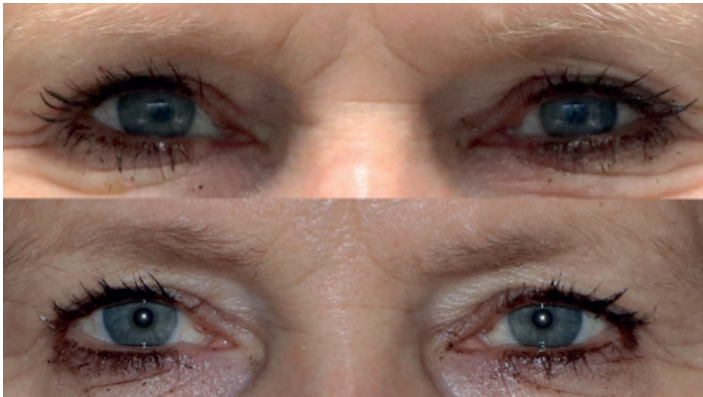

Figure 5: Eye area directly before and after eight-hour surgery: The eyes are much clearer and the pupils are smaller due to the impact on the parasympathetic nervous system.

A “healthy” acute inflammation reaction occurs as follows: Immunological processes, triggered by neurotransmitters, and the activated sympathetic nervous system have a proinflammatory effect in order to combat pathogens to the greatest extent possible, overcoming them entirely⁽⁸⁵⁾. If the inflammation reaction is successful in achieving this goal, the inflammation reaction is wound down locally and systemically and the catabolic process comes to an end. T helper cells also contribute to this thanks to their anti-inflammatory properties⁽⁸⁶⁾.

Chronic inflammation disrupts the carefully calibrated regulation performed by the autonomic nervous system. The sympathetic nervous system is activated over the long term. No local anti-inflammatory counterregulation ensues, proinflammatory immunological processes are activated over the long term and the catabolic process remains ongoing (“chronic inflammatory condition”)⁽⁸⁴⁾.

This is a vicious circle, because the inflammation reaction and sympathetic nervous system activity sustain one another. This may cause further illness, such as high blood pressure, insulin resistance, cardiovascular issues and dia-

betes. In cases of advanced cancer, it can lead to cachexia⁽⁸⁶⁾. At the same time, the parasympathetic nervous system’s activity is blocked, which in itself would otherwise have an anti-inflammatory effect. This was demonstrated in a study conducted by Koopman et al., in which the peripheral production of cytokines was inhibited by stimulating the vagus nerve. Significant inhibition of $\text{TNF-}\alpha$ and IL-6 production relieved symptoms among rheumatoid arthritis patients, even among some of those who had proven resistant to therapy⁽⁸⁷⁾.

In today’s world, the three factors most likely to cause stress, and therefore chronic disease, are burdensome relationships, EMFs and dental/oral interference fields. Several of these mechanisms, which pose a significant burden, are described in the following chapters.

References

1. Bach J-F. The effect of infections on susceptibility to autoimmune and allergic diseases. *N Engl J Med*. 2002;347(12):911-20. doi:10.1056/NEJMra020100
2. Baio J, Wiggins L, Christensen DL, Maenner MJ, Daniels J, Warren Z, Kurzius-Spencer M, Zahorodny W, Robinson Rosenberg C, White T, Durkin MS, Imm P, Nikolaou L, Yeargin-Allsopp M, Lee L-C, Harrington R, Lopez M, Fitzgerald RT, Hewitt A, Pettygrove S, Constantino JN, Vehorn A, She-nouda J, Hall-Lande J, van Naarden Braun K, Dowling NF. Prevalence of Autism Spectrum Disorder Among Children Aged 8 Years - Autism and Developmental Disabilities Monitoring Network, 11 Sites, United States, 2014. *MMWR Surveill Summ*. 2018;67(6):1-23. doi:10.15585/mmwr.ss6706a1
3. Bach J-F. The hygiene hypothesis in autoimmunity: the role of pathogens and commensals. *Nature Reviews Immunology*. 2017;18105 EP -. doi:10.1038/nri.2017.111
4. Kip M, Zimmermann A, Bleß H-H. Epidemiologie der Multiplen Sklerose. In: ; 2016. p. 13-21.
5. Huggins H. Root Canal Dangers: DNA Studies Confirm Dr. Weston Price's Century-Old Findings [Internet]. 2010. Available from: <http://www.westonaprice.org/holistic-healthcare/root-canal-dangers/>
6. Sharma K, Bittner F, Kamholz J. Epidemiology of multiple sclerosis in the United States (P1.140). *Neurology* [Internet]. 2018;90(15 Supplement). Available from: https://n.neurology.org/content/90/15_Supplement/P1.140
7. Grytten N, Torkildsen Ø, Myhr K-M. Time trends in the incidence and prevalence of multiple sclerosis in Norway during eight decades. *Acta Neurol Scand*. 2015;132(199):29-36. doi:10.1111/ane.12428
8. Talbott EO, Malek AM, Lacomis D. The epidemiology of amyotrophic lateral sclerosis. *Handb Clin Neurol*. 2016;138225-38. doi:10.1016/B978-0-12-802973-2.00013-6
9. ALStreatment.com. ALS incidence [Internet]. Unique Access Medical Pte Ltd. 2019 [cited 2019 Aug 19]. Available from: <https://alstreatment.com/amyotrophic-lateral-sclerosis-incidence/>
10. Mehta P, Kaye W, Raymond J, Punjani R, Larson T, Cohen J, Muravov O, Horton K. Prevalence of Amyotrophic Lateral Sclerosis - United States, 2015. *MMWR Morb Mortal Wkly Rep*. 2018;67(46):1285-9. doi:10.15585/mmwr.mm6746a1
11. VitaminDWiki. ALS [Internet]. 2019. Available from: <https://vitamindwiki.com/Incidence+of+30+health+problems+related+to+vitamin+D+has+doubled+in+a+decade>
12. American Association of Endodontics [Internet]. Available from: <https://www.aae.org/specialty/about-aae/newsroom/endodontic-treatment-statistics/>
13. Greater Washington Endodontics [Internet]. Available from: <https://va-rootcanal.com/dental-facts/>
14. KZBV. Jahrbuch 2018: Statistische Basisdaten zur vertragszahnärztlichen Versorgung [Internet]. 2018.
15. Dr. Susan Blum. Autoimmunerkrankungen erfolgreich behandeln: 2.Auflage. Kirchzarten: VAK Verlags GmbH; 2015.
16. Carina Rehberg. Titandioxid - Ein Stoff, den Sie meiden sollten [Internet]. 2019. Available from: <https://www.zentrum-der-gesundheit.de/titandioxid-verursacht-krebs-170204010.html>
17. Grande F, Tucci P. Titanium Dioxide Nanoparticles: a Risk for Human Health? *Mini Rev Med Chem*. 2016;16(9):762-9.
18. Metalcor GmbH. Datenblatt Ti1 [Internet]. 2019 [updated 2019 Aug 16]. Available from: <http://www.metalcor.de/datenblatt/121/>
19. Harloff T, Hönle W, Holzwarth U, Bader R, Thomas P, Schuh A. Titanium allergy or not? „Impurity“ of titanium implant materials. *Health*. 2010;02(04):306-10. doi:10.4236/health.2010.24045
20. Universität Gießen. Entstehung der Nickel-Allergie aufgeklärt: Metall aktiviert Rezeptor des angeborenen Immunsystems [Internet]. 2010. Available from: <https://www.sci-nexx.de/news/biowissen/entstehung-der-nickel-allergie-aufgeklaert/>
21. Ahlström MG, Thyssen JP, Menné T, Johansen JD. Prevalence of nickel allergy in Europe following the EU Nickel Directive - a review. *Contact Derm*. 2017;77(4):193-200. doi:10.1111/cod.12846
22. Head KA, Kelly GS. Nutrients and botanicals for treatment of stress: adrenal fatigue, neurotransmitter imbalance, anxiety, and restless sleep. *Altern Med Rev*. 2009;14(2):114-40.
23. Schneiderman N, Ironson G, Siegel SD. Stress and health: psychological, behavioral, and biological determinants. *Annu Rev Clin Psychol*. 2005;1607-28. doi:10.1146/annurev.clinpsy.1.102803.144141
24. Tracey KJ. The inflammatory reflex. *Nature*. 2002;420(6917):853-9. doi:10.1038/nature01321
25. Information Medical Statistics AG. Diagnosen in Schweizer Arztpraxen 1993 - 2002 [Internet]. Cham I-IHH. Available from: www.interpharma.ch
26. Gandhi OP, Morgan LL, Salles AA de, Han Y-Y, Herberman RB, Davis DL. Exposure limits: the underestimation of absorbed cell phone radiation, especially in children. *Electromagn Biol Med*. 2012;31(1):34-51. doi:10.3109/15368378.2011.622827
27. Hardell L. Effects of Mobile Phones on Children's and Adolescents' Health: A Commentary. *Child Dev*. 2018;89(1):137-40. doi:10.1111/cdev.12831
28. Redmayne M. International policy and advisory response regarding children's exposure to radio frequency electromagnetic fields (RF-EMF). *Electromagn Biol Med*.

2016;35(2):176–85. doi:10.3109/15368378.2015.1038832

29. Sage C, Burgio E. Electromagnetic Fields, Pulsed Radio-frequency Radiation, and Epigenetics: How Wireless Technologies May Affect Childhood Development. *Child Dev.* 2018;89(1):129–36. doi:10.1111/cdev.12824

30. Salles AA de, Bulla G, Rodriguez CEF. Electromagnetic absorption in the head of adults and children due to mobile phone operation close to the head. *Electromagn Biol Med.* 2006;25(4):349–60. doi:10.1080/15368370601054894

31. Schoeni A, Roser K, Rössli M. Memory performance, wireless communication and exposure to radiofrequency electromagnetic fields: A prospective cohort study in adolescents. *Environ Int.* 2015;85:343–51. doi:10.1016/j.envint.2015.09.025.

32. Chiu C-T, Chang Y-H, Chen C-C, Ko M-C, Li C-Y. Mobile phone use and health symptoms in children. *Journal of the Formosan Medical Association.* 2014;114. doi:10.1016/j.jfma.2014.07.002

33. Fejes I, Závaczki Z, Szöllosi J, Koloszar S, Daru J, Kovács L, Pál A. Is there a relationship between cell phone use and semen quality? *Arch Androl.* 2005;51(5):385–93. doi:10.1080/014850190924520

34. Balci M, Devrim E, Durak I. Effects of mobile phones on oxidant/antioxidant balance in cornea and lens of rats. *Curr Eye Res.* 2007;32(1):21–5. doi:10.1080/02713680601114948

35. Bortkiewicz A, Gadzicka E, Szymczak W. Mobile phone use and risk for intracranial tumors and salivary gland tumors - A meta-analysis. *Int J Occup Med Environ Health.* 2017;30(1):27–43. doi:10.13075/ijomeh.1896.00802

36. Jenaro C, Flores N, Gómez-Vela M, González-Gil F, Caballo C. Problematic internet and cell-phone use: Psychological, behavioral, and health correlates. *Addiction Research & Theory.* 2007;15(3):309–20. doi:10.1080/16066350701350247

37. Kivrak EG, Yurt KK, Kaplan AA, Alkan I, Altun G. Effects of electromagnetic fields exposure on the antioxidant defense system. *J Microsc Ultrastruct.* 2017;5(4):167–76. doi:10.1016/j.jmau.2017.07.003

38. Kocaman A, Altun G, Kaplan AA, Deniz ÖG, Yurt KK, Kaplan S. Genotoxic and carcinogenic effects of non-ionizing electromagnetic fields. *Environ Res.* 2018;163:71–9. doi:10.1016/j.envres.2018.01.034

39. Nikolai Nikolaevich Kositsky, Aljona Igorevna Nizhelska. Influence of High-frequency Electromagnetic Radiation at Non-thermal Intensities on the Human Body (A review of work by Russian and Ukrainian researchers). *Newsletter of the Cellular Phone Taskforce Inc.* 2001;(Volume 3, Number 1).

40. Pall ML. Wi-Fi is an important threat to human health. *Environ Res.* 2018;164:405–16. doi:10.1016/j.envres.2018.01.035

41. Prasad M, Kathuria P, Nair P, Kumar A, Prasad K. Mobile phone use and risk of brain tumours: a systematic review of association between study quality, source of funding, and research outcomes. *Neurol Sci.* 2017;38(5):797–810. doi:10.1007/s10072-017-2850-8

42. Wang J, Su H, Xie W, Yu S. Mobile Phone Use and The Risk of Headache: A Systematic Review and Meta-analysis of Cross-sectional Studies. *Scientific Reports.* 2017;7(1):12595. doi:10.1038/s41598-017-12802-9

43. Wdowiak A, Mazurek PA, Wdowiak A, Bojar I. Effect of electromagnetic waves on human reproduction. *Ann Agric Environ Med.* 2017;24(1):13–8. doi:10.5604/12321966.1228394

44. La Vignera S, Condorelli RA, Vicari E, D'Agata R, Calogero AE. Effects of the exposure to mobile phones on male reproduction: a review of the literature. *J Androl.* 2012;33(3):350–6. doi:10.2164/jandrol.111.014373

45. Lennart Hardell. World Health Organization, radiofrequency radiation and health - a hard nut to crack (Review). 2017.

46. Bundesamt für Strahlenschutz. 5G [Internet]. Stand 2019. Available from: http://www.bfs.de/DE/themen/emf/mobilfunk/basiswissen/5g/5g_node.html

47. Di Ciaula A. Towards 5G communication systems: Are there health implications? *Int J Hyg Environ Health.* 2018;221(3):367–75. doi:10.1016/j.ijheh.2018.01.011

48. McClelland S, Jaboin JJ. The Radiation Safety of 5G Wi-Fi: Reassuring or Russian Roulette? *Int J Radiat Oncol Biol Phys.* 2018;101(5):1274–5. doi:10.1016/j.ijrobp.2018.04.051

49. Neufeld E, Kuster N. Systematic Derivation of Safety Limits for Time-Varying 5G Radiofrequency Exposure Based on Analytical Models and Thermal Dose. *Health Phys.* 2018. doi:10.1097/HP.0000000000000930

50. Russell CL. 5 G wireless telecommunications expansion: Public health and environmental implications. *Environ Res.* 2018;165:484–95. doi:10.1016/j.envres.2018.01.016

51. diagnose:funk. Schweiz reagiert auf Bürgerproteste gegen 5G BAFU bestätigt Risiken und fordert Vorsorge [Internet]. 2019 [cited 2019 Aug 16]. Available from: <https://www.diagnose-funk.org/publikationen/artikel/detail&new-sid=1443>

52. Betzalel N, Ben Ishai P, Feldman Y. The human skin as a sub-THz receiver - Does 5G pose a danger to it or not? *Scientific Reports.* 2018;16:3208–16. doi:10.1016/j.envres.2018.01.032

53. Lehmann I, Sack U, Lehmann J. Metal ions affecting the immune system. *Met Ions Life Sci.* 2011;8:157–85.

54. Zhou Y, Luo G-H. Porphyromonas gingivalis and digestive system cancers. *World J Clin Cases.* 2019;7(7):819–29. doi:10.12998/wjcc.v7.i7.819

55. Wei M-Y, Shi S, Liang C, Meng Q-C, Hua J, Zhang Y-Y, Liu J, Zhang B, Xu J, Yu X-J. The microbiota and micro-

- biome in pancreatic cancer: more influential than expected. *Mol Cancer*. 2019;18. doi:10.1186/s12943-019-1008-0
- 56.** Ha NH, Park DG, Woo BH, Kim DJ, Choi JI, Park BS, Kim YD, Lee JH, Park HR. Porphyromonas gingivalis increases the invasiveness of oral cancer cells by upregulating IL-8 and MMPs. *Cytokine*. 2016;8664-72. doi:10.1016/j.cyto.2016.07.013
- 57.** Mahendra J, Mahendra L, Kurian VM, Jaishankar K, Myhilli R. 16S rRNA-based detection of oral pathogens in coronary atherosclerotic plaque. *Indian J Dent Res*. 2010;21(2):248-52. doi:10.4103/0970-9290.66649
- 58.** Castellarin M, Warren RL, Freeman JD, Dreolini L, Krzywinski M, Strauss J, Barnes R, Watson P, Allen-Vercoe E, Moore RA, Holt RA. Fusobacterium nucleatum infection is prevalent in human colorectal carcinoma. *Genome Res*. 2012;22(2):299-306. doi:10.1101/gr.126516.111
- 59.** Tezal M, Sullivan MA, Reid ME, Marshall JR, Hyland A, Loree T, Lillis C, Hauck L, Wactawski-Wende J, Scannapieco FA. Chronic periodontitis and the risk of tongue cancer. *Arch Otolaryngol Head Neck Surg*. 2007;133(5):450-4. doi:10.1001/archotol.133.5.450
- 60.** Dominy SS, Lynch C, Ermini F, Benedyk M, Marczyk A, Konradi A, Nguyen M, Haditsch U, Raha D, Griffin C, Holsinger LJ, Arastu-Kapur S, Kaba S, Lee A, Ryder MI, Potempa B, Mydel P, Hellvard A, Adamowicz K, Hasturk H, Walker GD, Reynolds EC, Faull RLM, Curtis MA, Dragunow M, Potempa J. Porphyromonas gingivalis in Alzheimer's disease brains: Evidence for disease causation and treatment with small-molecule inhibitors. *Sci Adv*. 2019;5(1):eaau3333. doi:10.1126/sciadv.aau3333
- 61.** Guven DC, Dizdar O, Alp A, Akdoğan Kittana FN, Karakoc D, Hamaloglu E, Lacin S, Karakas Y, Kilickap S, Hayran M, Yalcin S. Analysis of Fusobacterium nucleatum and Streptococcus gallolyticus in saliva of colorectal cancer patients. *Biomark Med*. 2019;13(9):725-35. doi:10.2217/bmm-2019-0020
- 62.** Ott SJ, El Mokhtari NE, Musfeldt M, Hellmig S, Freitag S, Rehman A, Kühbacher T, Nikolaus S, Namsolleck P, Blaut M, Hampe J, Sahly H, Reinecke A, Haake N, Günther R, Krüger D, Lins M, Herrmann G, Fölsch UR, Simon R, Schreiber S. Detection of diverse bacterial signatures in atherosclerotic lesions of patients with coronary heart disease. *Circulation*. 2006;113(7):929-37. doi:10.1161/CIRCULATIONAHA.105.579979
- 63.** Hieken TJ, Chen J, Hoskin TL, Walther-Antonio M, Johnson S, Ramaker S, Xiao J, Radisky DC, Knutson KL, Kalari KR, Yao JZ, Baddour LM, Chia N, Degnim AC. The Microbiome of Aseptically Collected Human Breast Tissue in Benign and Malignant Disease. *Scientific Reports*. 2016;630751. doi:10.1038/srep30751
- 64.** Dr. med. Alfred Lohninger. Herzratenvariabilität: Das HRV-Praxis-Lehrbuch: facultas; 2017.
- 65.** Shaffer F, McCraty R, Zerr CL. A healthy heart is not a metronome: an integrative review of the heart's anatomy and heart rate variability. *Front Psychol*. 2014;51040. doi:10.3389/fpsyg.2014.01040
- 66.** Kemp AH, Quintana DS. The relationship between mental and physical health: insights from the study of heart rate variability. *Int J Psychophysiol*. 2013;89(3):288-96. doi:10.1016/j.ijpsycho.2013.06.018
- 67.** Golbidi S, Li H, Laher I. Oxidative Stress: A Unifying Mechanism for Cell Damage Induced by Noise, (Water-Pipe) Smoking, and Emotional Stress-Therapeutic Strategies Targeting Redox Imbalance. *Antioxid Redox Signal*. 2018;28(9):741-59. doi:10.1089/ars.2017.7257
- 68.** Neurologen und Psychiater im Netz. Chronischer Stress schwächt das Immunsystem [Internet]. 2012. Available from: <https://www.neurologen-und-psychiater-im-netz.org/psychiatrie-psychosomatik-psychotherapie/ratgeber-archiv/meldungen/article/chronischer-stress-schwaecht-das-immunsystem/>
- 69.** Thomas Karow RL-R. Allgemeine und Spezielle Pharmakologie und Toxikologie: vorlesungsorientierte Darstellung und klinischer Leitfaden für Studium und Praxis 23. Auflage. 2014.
- 70.** Wehrwein EA, Orer HS, Barman SM. Overview of the Anatomy, Physiology, and Pharmacology of the Autonomic Nervous System. *Compr Physiol*. 2016;6(3):1239-78. doi:10.1002/cphy.c150037
- 71.** Karemaker JM. An introduction into autonomic nervous function. *Physiol Meas*. 2017;38(5):R89-R118. doi:10.1088/1361-6579/aa6782
- 72.** Optimum.me. Dr. Otto Warburg und sein Medizin-Nobelpreis [Internet]. 2014-2016. Available from: <https://www.optimum.me/saeure-basen-haushalt/dr-otto-warburg-und-sein-medizin-nobelpreis>
- 73.** Dr. med. dent. Johann Lechner. Immunstress durch Zahnmetalle und Elektromog. *Raum&Zeit*;1995(74):5-13.
- 74.** Gomes C, Martinho FC, Barbosa DS, Antunes LS, Póvoa HCC, Baltus THL, Morelli NR, Vargas HO, Nunes SOV, Anderson G, Maes M. Increased Root Canal Endotoxin Levels are Associated with Chronic Apical Periodontitis, Increased Oxidative and Nitrosative Stress, Major Depression, Severity of Depression, and a Lowered Quality of Life. *Molecular Neurobiology*. 2018;55(4):2814-27. doi:10.1007/s12035-017-0545-z
- 75.** Reiffenstein RJ, Hulbert WC, Roth SH. Toxicology of hydrogen sulfide. *Annu Rev Pharmacol Toxicol*. 1992;32:109-34. doi:10.1146/annurev.pa.32.040192.000545
- 76.** Valko M, Rhodes CJ, Moncol J, Izakovic M, Mazur M. Free radicals, metals and antioxidants in oxidative stress-induced cancer. *Chem Biol Interact*. 2006;160(1):1-40.

doi:10.1016/j.cbi.2005.12.009

77. Saha SK, Lee SB, Won J, Choi HY, Kim K, Yang G-M, Dayem AA, Cho S-G. Correlation between Oxidative Stress, Nutrition, and Cancer Initiation. *Int J Mol Sci.* 2017;18(7). doi:10.3390/ijms18071544

78. Du J, Zhu M, Bao H, Li B, Dong Y, Xiao C, Zhang GY, Henter I, Rudorfer M, Vitiello B. The Role of Nutrients in Protecting Mitochondrial Function and Neurotransmitter Signaling: Implications for the Treatment of Depression, PTSD, and Suicidal Behaviors. *Crit Rev Food Sci Nutr.* 2016;56(15):2560–78. doi:10.1080/10408398.2013.876960

79. Dhas Y, Mishra N, Banerjee J. Vitamin D Deficiency and Oxidative Stress in Type 2 Diabetic Population of India. *Cardiovasc Hematol Agents Med Chem.* 2017;14(2):82–9. doi:10.2174/1871525714666160426150233

80. Belyaev I, Dean A, Eger H, Hubmann G, Jandrisovits R, Kern M, Kundi M, Moshhammer H, Lercher P, Müller K, Oberfeld G, Ohnsorge P, Pelzmann P, Scheingraber C, Thill R. EUROPAEM EMF Guideline 2016 for the prevention, diagnosis and treatment of EMF-related health problems and illnesses. *Rev Environ Health.* 2016;31(3):363–97. doi:10.1515/reveh-2016-0011

81. Lutgendorf SK, Costanzo ES. Psychoneuroimmunology and health psychology: an integrative model. *Brain Behav Immun.* 2003;17(4):225–32.

82. Di Yang, Yang X, Deng F, Guo X. Ambient Air Pollution and Biomarkers of Health Effect. *Adv Exp Med Biol.* 2017;101759–102. doi:10.1007/978-981-10-5657-4_4

83. Kotłęga D, Gołąb-Janowska M, Masztalewicz M, Ciećwież S, Nowacki P. The emotional stress and risk of ischemic stroke. *Neurol Neurochir Pol.* 2016;50(4):265–70. doi:10.1016/j.pjnns.2016.03.006

84. Pongratz G, Straub RH. Role of peripheral nerve fibres in acute and chronic inflammation in arthritis. *Nat Rev Rheumatol.* 2013;9(2):117–26. doi:10.1038/nrrheum.2012.181

85. Straub RH, Rauch L, Fassold A, Lowin T, Pongratz G. Neuronally released sympathetic neurotransmitters stimulate splenic interferon-gamma secretion from T cells in early type II collagen-induced arthritis. *Arthritis Rheum.* 2008;58(11):3450–60. doi:10.1002/art.24030

86. Pongratz G, Straub RH. The sympathetic nervous response in inflammation. *Arthritis Res Ther.* 2014;16(6):504. doi:10.1186/s13075-014-0504-2

87. Koopman FA, van Maanen MA, Vervoordeldonk MJ, Tak PP. Balancing the autonomic nervous system to reduce inflammation in rheumatoid arthritis. *J Intern Med.* 2017;282(1):64–75. doi:10.1111/joim.12626

Some mechanisms of oral disturbances

Bacteria or bacterial products in jaw inflammation or escaping from root-canal-treated teeth are released into the bloodstream (bacterial translocation) and are characterized by endotoxemia (increased endotoxin concentration in the blood)⁽¹⁾. This stress, sustained on a 24/7 basis, triggers low-level but chronic inflammatory processes in the body and is referred to as “silent inflammation”⁽²⁾.

Silent inflammation

In the long term, it can cause serious metabolic diseases, such as obesity or diabetes mellitus, as well as severe cardiovascular diseases (atherosclerosis, heart attacks, strokes) and cancer⁽³⁻⁵⁾. Endotoxins, components of lipopolysaccharides (LPSs) in the outer wall of Gram-negative bacteria, are released by bacteria directly or after their death. LPSs activate the cells of the immune system we are born with, which, in turn, induces the release of proinflammatory substances and initiates an inflammatory reaction. This can have a significant impact on the metabolism overall, resulting in metabolic or cardiovascular diseases. Macrophages are activated, causing intracellular NF-kappaB formation and the production of proinflammatory cytokines. Increased NF-kappaB-mediated gene activation leads to the formation of nitric oxide synthase, which initiates the expression of oxygen radicals and causes what is known as nitrosative stress and mitochondriopathies⁽¹⁾.

Autoimmune diseases

Each of our cells has a so-called “MHC code” (major histocompatibility complex) that tells our immune system that the cell belongs to us and is a “self cell”. You could also describe this as a uniform people wear to identify themselves as members of a particular group, which prevents them from being attacked by the other group members. However, if this MHC code is changed, it is somewhat like the cell changing its uniform and coming under attack by its own group’s “police force”, i.e. its own immune system. The “self cell” becomes a “non-self cell”. Toxins from jaw inflammation or root-canal-treated teeth, in particular, along with heavy metals from dental materials, primarily amalgam (consisting of over 50% mercury), bind to our cells and change the MHC code. If the cell in question is a muscle cell, this can result in fibromyalgia or MS. If it is a nerve cell, it can trigger ALS or Alzheimer’s disease. Various studies have proven the correlation between amalgam and MS, ALS and Alzheimer’s disease⁽⁸⁻¹⁰⁾.

Retrograde axonal transport

Endotoxins, which originate from bacteria or are released when bacteria die, can— similar to tetanus and botulinum toxins—be transported through axons (nerve fibers) and quickly reach the ganglia or the CNS⁽¹¹⁾. There, they can lead to blockages and failures of the trigeminal nerve, the abducens nerve or the facial nerve, for instance. Consequently, removing the lesion or the interference field and eliminating the endotoxin supply source can result in a sudden improvement in the innervation area of the respective nerve in what could be termed an “instantaneous effect”. This effect can be simulated, e.g. by injecting a local anesthetic⁽¹²⁾.

Allergies and intolerances

Plastics, especially methacrylate⁽¹³⁾, very frequently cause genuine type I allergies. Type IV allergies occur in response to dental alloys⁽¹⁴⁾. Titanium, on the other hand, triggers “particle-induced inflammation”, because the titanium particles in the tissue surrounding the implant are phagocytized by macrophages, which respond to this stimulus by releasing osteoresorptive, pro-inflammatory cytokines (TNF- α , IL-1 β)⁽¹⁵⁻¹⁷⁾. Therefore, titanium tolerance should be verified by way of the “titanium stimulation test” prior to the use of titanium (www.imd-berlin.de). The figure 1 clearly shows how the “titanium particle > activation of tissue macrophage > TNF- α und IL-1 β release > osteoclast activation” axis causes bone degradation around the implant⁽¹⁹⁾. The latest studies have now proven our long-time assumption, namely, that that so-called “peri-implantitis”, i.e. inflammatory bone loss around titanium implants, is nothing other than a sign of titanium intolerance^(19, 20).

This explains why the widespread method of treating peri-implantitis by grinding and polishing the implant surface or cleaning it with titanium brushes does not work. It releases massive amounts of titanium particles into the bone and tissue, adding fuel to the fire and leading to further bone loss. As a possible titanium peri-implantitis therapy, we recommend raising the amounts of bone building factors by supplementing with vitamins C and D3, vitamin K2/mk7, magnesium, zinc, omega-3⁽²¹⁻²⁹⁾ as well as inhibiting the bone-damaging osteoclasts by giving the patient vitamin C or D3^(30, 31) or acetylsalicylic acid. Disturbances and stress on the immune system play a role in all of the above-mentioned pathogenetic mechanisms, whether

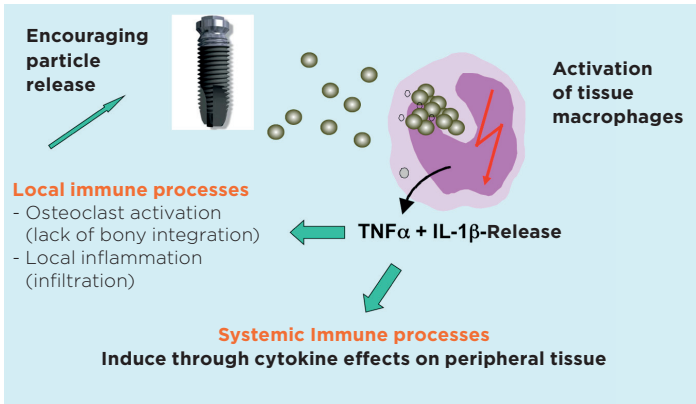


Figure 1: Titanium-particle-induced inflammatory response⁽¹⁸⁾

directly or indirectly. This should be seen in connection with the finding of one of the world's leading immunologists, Prof. Yehuda Shoenfeld, who observed that every second American suffers from a disease of the immune system⁽³²⁾. This underscores the need to look for disturbances in the oral cavity in the event of a chronic disease.

Root canal treatments

Endodontically treated teeth are dead teeth. A dead tooth, once an organ with its own nerve and blood supply, remains in the oral cavity as a dead pillar. Even the best micro-surgical endodontic treatment will never manage to clean out all bacteria and seal the root canal in a bacteria-tight manner. A cross-section of dentin shows that, owing to technical limitations, it is simply not possible to sufficiently clean and fill the 14,000–32,000 dentinal tubules per mm² of root dentin⁽¹³⁾. Accessory and side canals as well as the perio-endo connection via the dentinal tubules remain in place. They are colonized by different, partly unknown species of anaerobic, pathogenic bacteria, which decompose the remaining organic tissue and secrete harmful metabolic products (toxins)⁽³⁴⁾. Here, another, immunological limitation becomes apparent. It results from the fact that pathogens such as bacteria, which are 0.6–1 μm in diameter, can easily penetrate the dentinal tubules, which are up to 3 μm in width. Once they are inside the dentinal tubules, the macrophages, which measure approx. 25–50 μm ^(35–37), cannot reach and eliminate them. This situation is best illustrated by comparing it to a cat (macrophages) sitting in front of a mouse hole (dentinal tubules) that cannot reach the mice (bacteria). These pathogenic bacteria produce highly toxic and potentially carcinogenic hydrogen sulphide compounds (thioethers/mercaptans) from the amino acids cysteine and methionine as by-products of anaerobic metabolism⁽³⁸⁾. By means of irreversible inhibition at the active center of many vital endogenous enzymes, these toxins can cause a wide range of systemic and organic dis-

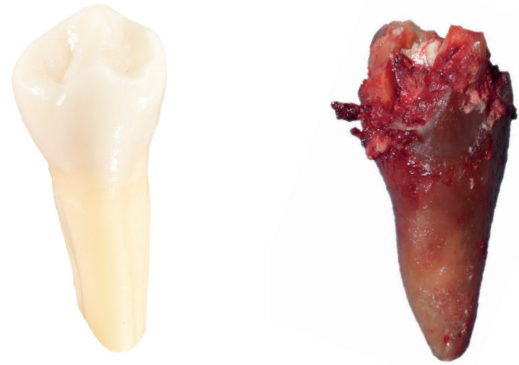

Figure 2: Comparison of a healthy tooth with an endodontically treated tooth

eases^(39–41). The inhibition of important enzymes in the respiratory chain of mitochondria has been proven⁽⁴²⁾ and is also demonstrated in lab tests in clinical practice⁽⁴³⁾. Whenever we chew, these bacteria, and especially their toxins, are released into the lymphatic system of the surrounding tissue, from where they enter the bloodstream (focal infection) and then the entire body.

A study conducted by Siqueira et al. found microorganisms in 19 out of 20 endodontically treated teeth with apical inflammation, which suggests chronic infection⁽⁴⁴⁾. A study conducted by Richardson et al. examined the microflora on teeth with apical periodontitis and demonstrated the presence of rods, cocci, filaments and spirochetes⁽⁴⁵⁾. If an inflammation of the root apex is visible on the X-ray, root canal treatment is significantly more likely to fail due to chronic infection. In principle, it can be said that, since the introduction of the use of three-dimensional radiographs (DVT) as standard, it has become apparent that virtually no root-treated tooth is free of apical inflammation.

Vital, healthy pulp—and thus an intact immune system—play a decisive role in fighting off these germs. Frequently, chronic infection caused by colonization with germs develops into chronic inflammation of the surrounding bone, permanently activating the immune system. The macrophages activated over the course of this unspecific immune reaction release so-called “inflammation mediators” (TNF- α , IL-1 β , growth factors, prostaglandins PGE2 and leukotrienes), which circulate in the bloodstream. These inflammatory mediators favor the onset or advancement of systemic chronic inflammation and autoimmune diseases⁽⁴⁶⁾. TNF- α has been shown to increase the risk of developing postmenopausal breast cancer^(47,48). Dr. Thomas Rau from the Paracelsus Clinic in Switzerland has been able to demonstrate a clear correlation between breast cancer and root-treated teeth. He found root canal treatments on one or more teeth on the stomach meridian that runs across

the breast in more than 96% of breast cancer patients, compared to only 35% in healthy patients⁽⁴⁹⁾. Many studies increasingly indicate a correlation between root-canal-treated teeth and general diseases^(39, 50, 51). They show that root-canal-treated teeth can be associated with cardiovascular disease, diabetes, depression, oxidative and nitrosative stress^(3-5, 41, 52, 53). A healthy organism's perfect defense against such an inflammation would be an abscess with a swollen cheek. Today, however, we only know this type of reaction from textbooks. We have not seen it in any of our patients for about 20 years, as immunological performance among the population of western industrial nations has declined massively. Over the past 50 years, immunoglobulin A levels, a yardstick for measuring the strength of the immune system, have decreased by more than 30% in these countries! Even a cyst with or without a fistula is evidence of a halfway intact immune system, but this too is becoming increasingly rare. In most cases, the only manifestation still present in the area of the root-treated teeth is an undefined diffuse osteonecrosis (IO/NICO)—a sign of the immune system's complete surrender! In addition to silent inflammation and autoimmune reactions that occur in root-treated teeth, allergic reactions to various highly allergenic substances, such as gutta-percha, silver, Peru balsam or paraformaldehyde, contained in root canal fillings are very common⁽⁵⁴⁾.

The meridian system and its correlation with organs

The entire surface of the body is covered with a network of energy channels (meridians), which appear through the muscle fascia at certain switching points (acupuncture points) as small, anatomically proven neurovascular bundles. The transmission of information along the meridians has also been demonstrated by injecting radioactively labeled substances at the acupuncture points. Each of these meridians traverses a specific tooth or tooth group and is associated with certain anatomical structures and organ zones⁽⁵⁵⁾. Consequently, inflammation or a disorder in a specific dental zone almost always results in a disorder in the zone governed by this meridian, and, conversely, in an improvement once the disturbance is eliminated. Biological dentists familiar with the relationship between teeth, dental zones and particular organs or organ zones can have a targeted consultation with the patient based on disturbances along the meridian in question. In turn, dentists may stimulate improvement along the meridian by means of neural therapy in the corresponding tooth zone. This is a very con-

vincing diagnosis and therapy simulation method for patients, because temporary improvement is experienced within a few seconds or within a few hours. Improvement may be felt in the arm, for example, despite the injection having been made into the dental area⁽⁵⁶⁾. In addition to the narrowly defined and precise remote effect of the meridians, there is the so-called "myotome", which is influenced by disturbances in the oral cavity: C1-C7. As a rule of thumb, all oral cavity disturbances manifest as neck pain, usually associated with limited head mobility.

What are interference fields?

The concept of "interference fields" in the human body is based on the assumption that an inflammatory process in one part in the body can cause a reaction in another part and lead to therapeutic resistance and chronic disorders. In order to identify the interference field, a dentist will usually evaluate x-rays and clinical findings and compare them to the specialist physician's medical findings.

Interference field diagnostics

The teeth constitute one of the most important subsystems within a network of parts of the organism that perform a regulative function. Teeth and the respective periodontium (odonton) are related to other physical structures and organs. Reinhold Voll coined the term "odonton" and identified the direct and close interrelationships between the individual odontons and the different areas of the body⁽⁵⁷⁾. Interactions as well as both positive and negative influences can cause remote effects in both directions: a disturbed organ may have a pathological effect on the associated odonton and, conversely, a diseased tooth or its periodontium may disturb the organ to which it correlates⁽⁵⁸⁾.

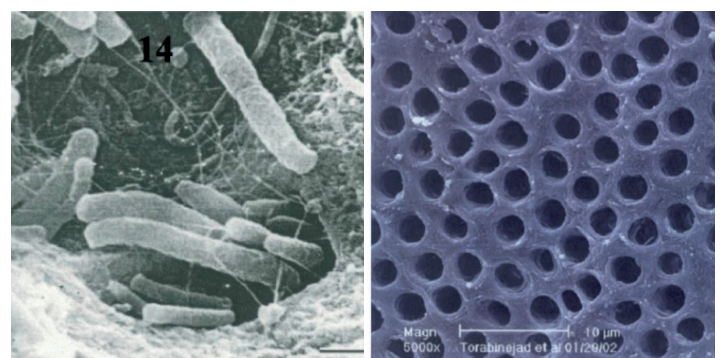


Figure 3: This illustration shows that bacteria, viruses, fungi, spirochetes and other germs can effortlessly penetrate the dentinal tubules in several rows. The dentinal tubules are 1–3 µm in diameter.

Test - injection of 1% Procaine

Procaine is a non-addictive synthetic derivative of cocaine. Before the introduction of procaine, cocaine was the most commonly used analgesic substance and was, among other uses, contained in the very early formula of Coca-Cola®. Procaine is an anesthetic with few side effects (Novocaine®) which blocks stimulus conduction. It also has a strong anti-inflammatory effect, stabilizes the nerve cell membranes by normalizing their action potential, stimulates the parasympathetic nervous system (vagus reaction, vasodilation), promotes the formation of new blood vessels and tissue blood flow (antidote to adrenaline) and is considered a radical scavenger⁽⁵⁹⁻⁶²⁾. It also exerts an attractant effect (chemotaxis) on defense cells. Up to 200 mg of procaine, i.e. up to 20 ml of the 1% solution, can be injected in a single application. Once inside the tissue, procaine breaks down into its components diethylaminoethanol, which is closely related to the neurotransmitter and parasympathetic activator acetylcholine, and para-aminobenzoic acid, a building block of folic acid⁽⁶³⁾.

In principle, the injection represents a temporary reboot of sorts for the respective region. The resulting viscerocutaneous reflex induces the brain to focus on this part of the body and the potential interference field is decoupled from the corresponding organ for a certain time. A 2-ml vial of 1% procaine is injected into the fold of the suspected region and, additionally, orally. The injection is not to be made too tentatively. Instead, a deliberate movement should result in a noticeable puncture for the injection of approx. 0.3 ml of the liquid. This puncture pain triggers the viscerocutaneous reflex, which will wake up the system, so to speak. According to a German entry in Wikipedia, "The visceral reflex is a reflex that causes pain originating in internal organs to be perceived as pain on the skin."

The damaged organ and the painful spot on the body's surface can sometimes be far apart⁽⁶⁴⁾. Patients should keep their eyes open so that a potential constriction of the pupils can be observed. A constriction of the pupils means that the neural therapeutic injection has temporarily moved the patient from the sympathetic to the parasympathetic mode by triggering a vagus reaction. Patients suffering from chronic inflammation (silent inflammation) will always be in the sympathetic mode (flight, resistance and defense with adrenaline release). However, healing can only occur in the parasympathetic mode. The spontaneous constriction of

the pupils is a direct consequence of a switch to the parasympathetic mode, and thus to relaxation and healing. If there is a connection between the neural therapeutic injection in the tooth area and a general medical disease or disorder, the patient will show an improvement in the connected body area within a few seconds, within eight hours at the latest. To give an example, almost all shoulder, arm and elbow pain correlates with root-treated teeth on the colon meridian (upper first and second premolars and lower first and second molar). After neural therapy, the discomfort almost always disappears immediately, with an effect lasting a few hours. Patients are asked to observe any subtle changes in their condition over a period of around 24 hours after the injection. Frequently, the so-called "Huneke Seconds Phenomenon" occurs immediately after the injection, resulting in spontaneous improvement in patients suffering from shoulder-arm syndrome. The suspected tooth can be diagnosed as a definite interference field if the effect lasts for around eight hours. The effect of the anesthesia itself is short-lived and usually wears off after around 30 minutes.

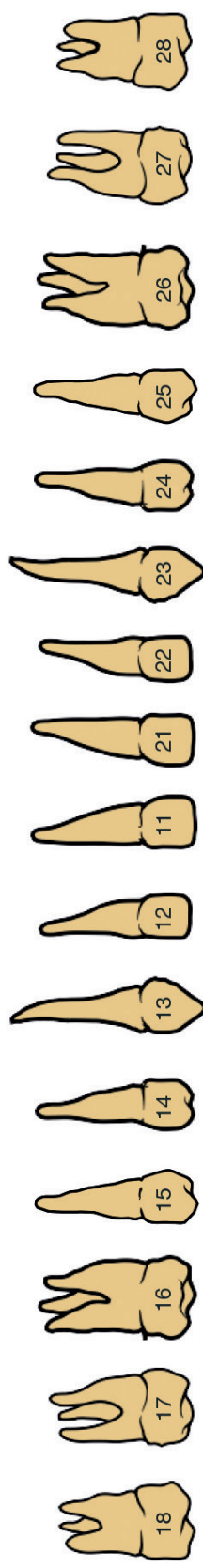
OroTox® - Test

The OroTox® is a simple method of detecting toxin load. A sulcus fluid sample is placed in a reagent mixture whose color will change to yellow if there are any sulfur-containing compounds.

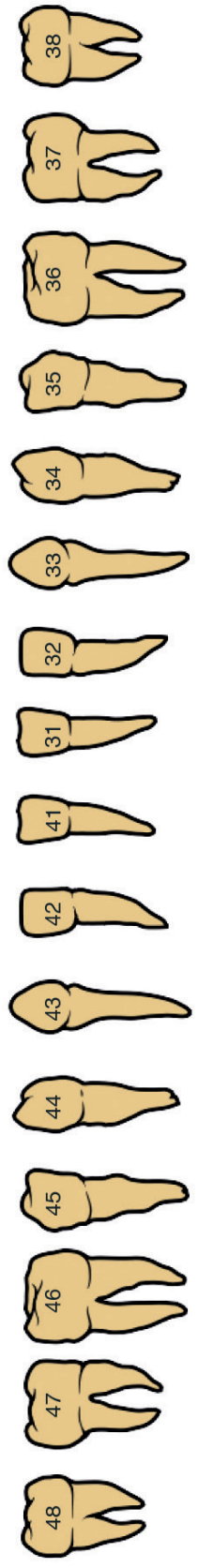
As opposed to a microbiological analysis, the OroTox® test will detect the bacterial products thioether and mercaptan. OroTox® is not a diagnostic agent per se, but provides clear qualitative and quantitative information about the presence of mercaptan/thioether. High OroTox® values on a root-filled tooth are a clear indication of a toxin load that can lead to a disturbance of the cell's energy production⁽⁶⁵⁾.

meridian system for self-analysis

| | | | | | | | | | | |
|----------------------|---|---------------------|-------------------------------------|-----------------------|------------------------------------|------------------------------------|-----------------------|-------------------------------------|--------------------|---|
| SENSORY ORGANS | inner ear | tongue/taste | nose/olfactory sense | eye | nose/olfactory sense/frontal sinus | nose/olfactory sense/frontal sinus | eye | nose/olfactory sense | tongue/taste | inner ear |
| JOINTS | shoulder elbow | jaw | shoulder elbow | rear knee | rear knee | rear knee | hip | shoulder elbow | jaw | shoulder elbow |
| | hand ulnar foot plantar toes | anterior knee | hand radial foot big toe | hip | sacrum-coccyx | sacrum-coccyx | hip | hand radial foot big toe | anterior knee | hand ulnar foot plantar toes |
| SPINAL CORD SEGMENTS | Th 1 C 8 Th 7 Th 6 Th 5 S 3 S 2 S 1 | Th 12 Th 11 L 1 | C 7 C 6 C 5 Th 4 Th 3 L 5 L 4 | Th 8 Th 9 Th 10 | L 3 L 2 S 4 S 5 Co | L 3 L 2 S 4 S 5 Co | Th 8 Th 9 Th 10 | C 7 C 6 C 5 Th 4 Th 3 L 5 L 4 | Th 12 Th 11 L 1 | Th 1 C 8 Th 7 Th 6 Th 5 S 3 S 2 S 1 |
| VERTEBRAE | B 1 C 7 B 6 B 5 S 2 S 1 | B 12 B 11 L 1 | C 7 C 6 C 5 B 4 B 3 L 5 L 4 | B 9 B 10 | L 3 L 2 Co S 5 S 4 S 3 | L 3 L 2 Co S 5 S 4 S 3 | B 9 B 10 | C 7 C 6 C 5 B 4 B 3 L 5 L 4 | B 12 B 11 L 1 | B 1 C 7 B 6 B 5 S 2 S 1 |
| ORGANS | right heart | pancreas | lung | right liver | left kidney | right kidney | left kidney | lung | spleen | left heart |
| YIN | 11-13 h | 9-11 h | 3-5 h | 1-3 h | 17-19 h | 17-19 h | 1-3 h | 3-5 h | 9-11 h | 11-13 h |
| | duodenum allergies | right stomach | colon | gall-bladder | right bladder urogenital region | right bladder urogenital region | left bile ducts | colon | left stomach | jejunum ileum allergies |
| YANG | 13-15 h | 7-9 h | 5-7 h | 23-1 h | 15-17 h | 15-17 h | 23-1 h | 5-7 h | 7-9 h | 13-15 h |
| ENDOCRINE GLANDS | anterior pituitary | parathyroid | thyroid | posterior pituitary | epiphysis | epiphysis | posterior pituitary | thyroid | thyroid | posterior pituitary |
| OTHER | CNS psyche | right mammary gland | right mammary gland | | back pain headache | back pain headache | back pain headache | | left mammary gland | CNS psyche |



| OTHER | energy balance | peripheral nerves | energy balance | peripheral nerves |
|----------------------------------|-----------------------------------|--------------------------------------|--|--|
| ENDOCRINE GLANDS VASCULAR SYSTEM | | | | |
| YANG | 11-13 h | 3-5 h | 9-11 h | 1-3 h |
| YIN | 13-15 h | 5-7 h | 7-9 h | 23-1 h |
| ORGANS | right heart cardiovascular system | right lung | pancreas | right liver |
| VERTEBRAE | right ileum allergies | right colon ileosacral area | right stomach pylorus | gall-bladder |
| SPINAL CORD SEGMENTS | C7 B1 B5 B6 S1 S2 S1 | C7 C6 C5 B4 B3 L5 L4 | B12 B11 L1 | B9 B10 TH8 Th9 Th10 |
| JOINTS | shoulder - elbow | hand radial foot plantar toes | anterior knee | posterior knee |
| SENSORY ORGANS | ear/retina | ethmoidal cells/nose/olfactory sense | sinus maxillaris/tongue/sense of taste | sinus maxillaris/tongue/sense of taste |



Dental correspondences after taking into account the remuneration according to Bahr-Schmid, Voll-Kramer and the findings of TCM.

References

1. Ganzimmun Diagnostics AG. Endotoxinämie: LPS im Serum als Marker für Silent Inflammation. 2015;(Fachinformation 0086):1-11.
2. Dr. Elisabeth Jacobi-Gresser. Risiken für chronische Entzündungen durch orale Reizfaktoren: Immunlabordiagnostik in der Zahnheilkunde. ZMK Allgemeine Zahnheilkunde. 2012.
3. Cotti E, Dessì C, Piras A, Flore G, Deidda M, Madeddu C, Zedda A, Longu G, Mercurio G. Association of endodontic infection with detection of an initial lesion to the cardiovascular system. *Journal of Endodontics*. 2011;37(12):1624-9. doi:10.1016/j.joen.2011.09.006
4. Cotti E, Dessì C, Piras A, Mercurio G. Can a chronic dental infection be considered a cause of cardiovascular disease? A review of the literature. *Int J Cardiol*. 2011;148(1):4-10. doi:10.1016/j.ijcard.2010.08.011
5. Bains R, Bains VK. Lesions of endodontic origin: An emerging risk factor for coronary heart diseases. *Indian Heart J*. 2018;70 Suppl 3S431-S434. doi:10.1016/j.ihj.2018.07.004
6. Shelley Farrar Stoakes. Functions of MHC in the Immune System [Internet]. Available from: <https://www.news-medical.net/life-sciences/Functions-of-MHC-in-the-Immune-System.aspx>
7. Rassow J. Biochemie: 50 Tabellen. 2nd ed. Stuttgart: Thieme; 2008. XXX, 836 Seiten. (Duale Reihe).
8. Pendergrass JC, Haley BE. Inhibition of brain tubulin-guanosine 5'-triphosphate interactions by mercury: similarity to observations in Alzheimer's diseased brain. *Met Ions Biol Syst*. 1997;34461-78.
9. Stejskal J, Stejskal V. The role of metals in autoimmunity and the link to neuroendocrinology. *Neuro endocrinology letters*. 1999;20351-64.
10. Mutter J, Klinghardt D. Amalgam: Risiko für die Menschheit; Quecksilbervergiftungen richtig ausleiten, neue Fakten und Hilfe, auch nach der Amalgamentfernung! 3rd ed. Weil der Stadt: Fit-fürs-Leben-Verl. in der NaturaViva-Verl.-GmbH; 2013. 169 p. (Gesundheit).
11. Trepel M. Neuroanatomie: Struktur und Funktion ; [Online-Zugang + interaktive Extras]. 4th ed. München: Elsevier; 20]09. XIII, 450 Seiten. (StudentConsult).
12. Fischer L. Pathophysiologie des Schmerzes und Neuraltherapie [Pathophysiology of pain and neural therapy]. Praxis (Bern 1994). 2003;92(48):2051-9. ger. doi:10.1024/0369-8394.92.48.2051
13. Goon ATJ, Isaksson MAI. Hand Eczema from Acrylate Compounds in Dentistry. In: Alikhan A, Lachapelle J-M, Maibach HI, editors. Textbook of Hand Eczema. Berlin, Heidelberg: Springer Berlin Heidelberg; 2014. p. 169-83. (vol. 34).
14. Dr. Kurt E. Müller. Immunreaktion auf physiologisch nicht benötigte Metalle. UMG [Internet];2013(4). Available from: <http://deguz.de/fachkreise/fachinformationen/metalle-und-Metallischer-zahnersatz/immunreaktion-auf-physiologisch-nicht-benoetigte-metalle.html>
15. Sterner T, Schütze N, Saxler G, Jakob F, Rader CP. Auswirkungen von klinisch relevanten Aluminium Keramik-, Zirkonium Keramik- und Titanpartikel unterschiedlicher Größe und Konzentration auf die TNFalpha-Ausschüttung in einem humanen Makrophagensystem [Effects of clinically relevant alumina ceramic, zirconia ceramic and titanium particles of different sizes and concentrations on TNF-alpha release in a human macrophage cell line]. *Biomed Tech (Berl)*. 2004;49(12):340-4. ger. doi:10.1515/BMT.2004.063
16. Rader CP, Sterner T, Jakob F, Schütze N, Eulert J. Cytokine response of human macrophage-like cells after contact with polyethylene and pure titanium particles. *The Journal of Arthroplasty*. 1999;14(7):840-8. doi:10.1016/S0883-5403(99)90035-9
17. Cadosch D, Chan E, Gautschi OP, Meagher J, Zellweger R, Filgueira L. Titanium IV ions induced human osteoclast differentiation and enhanced bone resorption in vitro. *J Biomed Mater Res A*. 2009;91(1):29-36. doi:10.1002/jbm.a.32183
18. Volker von Baehr, Sabine Schütt. Immunologische Grundlagen der Titan-induzierten Periimplantitis. ZMK. 2011;2721-6.
19. Baehr Vv. Titanunverträglichkeit. ZWR. 2018;127(04):180-1. doi:10.1055/a-0563-2511
20. Safioti LM, Kotsakis GA, Pozhitkov AE, Chung WO, Daubert DM. Increased Levels of Dissolved Titanium Are Associated With Peri-Implantitis - A Cross-Sectional Study. *J Periodontol*. 2017;88(5):436-42. doi:10.1902/jop.2016.160524
21. Myneni VD, Mezey E. Regulation of bone remodeling by vitamin K2. *Oral Dis*. 2017;23(8):1021-8. doi:10.1111/odi.12624.
22. Aghajanian P, Hall S, Wongworawat MD, Mohan S. The Roles and Mechanisms of Actions of Vitamin C in Bone: New Developments. *J Bone Miner Res*. 2015;30(11):1945-55. doi:10.1002/jbmr.2709
23. Chin K-Y, Ima-Nirwana S. Vitamin C and Bone Health: Evidence from Cell, Animal and Human Studies. *Curr Drug Targets*. 2018;19(5):439-50. doi:10.2174/1389450116666150907100838
24. Nakamichi Y, Udagawa N, Horibe K, Mizoguchi T, Yamamoto Y, Nakamura T, Hosoya A, Kato S, Suda T, Takahashi N. VDR in Osteoblast-Lineage Cells Primarily Mediates Vitamin D Treatment-Induced Increase in Bone Mass by Suppressing Bone Resorption. *J Bone Miner Res*.

2017;32(6):1297–308. doi:10.1002/jbmr.3096.

25. van Leeuwen JP, van Driel M, van den Bemd GJ, Pols HA. Vitamin D control of osteoblast function and bone extracellular matrix mineralization. *Crit Rev Eukaryot Gene Expr.* 2001;11(1-3):199–226.

26. Lindsey RC, Cheng S, Mohan S. Vitamin C effects on 5-hydroxymethylcytosine and gene expression in osteoblasts and chondrocytes: Potential involvement of PHD2. *PLoS ONE.* 2019;14(8):e0220653. doi:10.1371/journal.pone.0220653

27. Kajarabille N, Díaz-Castro J, Hijano S, López-Frías M, López-Aliaga I, Ochoa JJ. A new insight to bone turnover: role of ω -3 polyunsaturated fatty acids. *ScientificWorldJournal.* 2013;2013589641. doi:10.1155/2013/589641

28. Liu H, Li W, Jia S, Li B. Puerarin and zinc additively prevent mandibular bone loss through inhibiting osteoclastogenesis in ovariectomized rats. *Histol Histopathol.* 2017;32(8):851–60. doi:10.14670/HH-11-855.

29. Welch AA, Skinner J, Hickson M. Dietary Magnesium May Be Protective for Aging of Bone and Skeletal Muscle in Middle and Younger Older Age Men and Women: Cross-Sectional Findings from the UK Biobank Cohort. *Nutrients.* 2017;9(11). doi:10.3390/nu9111189

30. Li A, Cong Q, Xia X, Leong WF, Yeh J, Miao D, Mishina Y, Liu H, Li B. Pharmacologic Calcitriol Inhibits Osteoclast Lineage Commitment via the BMP-Smad1 and I κ B-NF- κ B Pathways. *J Bone Miner Res.* 2017;32(7):1406–20. doi:10.1002/jbmr.3146

31. Choi HK, Kim G-J, Yoo H-S, Song DH, Chung K-H, Lee K-J, Koo YT, An JH. Vitamin C Activates Osteoblastogenesis and Inhibits Osteoclastogenesis via Wnt/ β -Catenin/ATF4 Signaling Pathways. *Nutrients.* 2019;11(3). doi:10.3390/nu11030506

32. 2nd International Conference on Membrane Science and Technology [Internet]. 2018.

33. Komabayashi T, Nonomura G, Watanabe LG, Marshall GW, Marshall SJ. Dentin tubule numerical density variations below the CEJ. *J Dent.* 2008;36(11):953–8. doi:10.1016/j.jdent.2008.08.002

34. Kwang S, Abbott P. The presence and distribution of bacteria in dentinal tubules of root filled teeth. *Int Endod J.* 2014;47(6):600–10. doi:10.1111/iej.12195

35. Mjör IA, Nordahl I. The density and branching of dentinal tubules in human teeth. *Archives of Oral Biology.* 1996;41(5):401–12. doi:10.1016/0003-9969(96)00008-8

36. Merkur.de. Diese Viren und Bakterien machen uns krank: Sie sind unsichtbar, aber überall: Viren und Bakterien machen uns krank. Doch die beiden Erreger haben sonst wenig gemeinsam. Warum sie sich unterscheiden. [Internet]. 2017. Available from: [https://www.merkur.de/leben/gesundheitsviren-bakterien-sind-menschen-gefaeh-](https://www.merkur.de/leben/gesundheitsviren-bakterien-sind-menschen-gefaehrlich-virusinfektion-zr-4417390.html)

[rlich-virusinfektion-zr-4417390.html](https://www.merkur.de/leben/gesundheitsviren-bakterien-sind-menschen-gefaehrlich-virusinfektion-zr-4417390.html)

37. Biologie-schule.de. Makrophage [Internet]. Available from: <http://www.biologie-schule.de/makrophage.php>

38. Jacobi-Gresser E, Schütt S, Huesker K, Baehr V v. Methyl mercaptan and hydrogen sulfide products stimulate proinflammatory cytokines in patients with necrotic pulp tissue and endodontically treated teeth. *J Biol Regul Homeost Agents.* 2015;29(1):73–84.

39. Lechner J, Baehr V v. Impact of Endodontically Treated Teeth on Systemic Diseases. *Dentistry.* 2018;08(03). doi:10.4172/2161-1122.1000476

40. Lechner J, Baehr V v. Stimulation of proinflammatory cytokines by volatile sulfur compounds in endodontically treated teeth. *Int J Gen Med.* 2015;8109–18. doi:10.2147/IJGM.S77693

41. Gomes C, Martinho FC, Barbosa DS, Antunes LS, Póvoa HCC, Baltus THL, Morelli NR, Vargas HO, Nunes SOV, Anderson G, Maes M. Increased Root Canal Endotoxin Levels are Associated with Chronic Apical Periodontitis, Increased Oxidative and Nitrosative Stress, Major Depression, Severity of Depression, and a Lowered Quality of Life. *Molecular Neurobiology.* 2018;55(4):2814–27. doi:10.1007/s12035-017-0545-z

42. Vahlkamp T, Meijer AJ, Wilms J, Chamuleau RA. Inhibition of mitochondrial electron transfer in rats by ethanethiol and methanethiol. *Clin Sci.* 1979;56(2):147–56. doi:10.1042/cs0560147

43. IMD Berlin. Labordiagnostik bei chronisch entzündlichen Multisystemerkrankungen [Internet] [cited 2019 Nov 8]. Available from: <https://www.imd-berlin.de/fachinformationen/diagnostikinformationen/entzuendungsdiagnostik-bei-multisystemerkrankungen.html>

44. Siqueira JF, Rôças IN, Alves FRF, Silva MG. Bacteria in the apical root canal of teeth with primary apical periodontitis. *Oral Surg Oral Med Oral Pathol Oral Radiol Endod.* 2009;107(5):721–6. doi:10.1016/j.tripleo.2009.01.042

45. Richardson N, Mordan NJ, Figueiredo JAP, Ng Y-L, Gulabivala K. Microflora in teeth associated with apical periodontitis: a methodological observational study comparing two protocols and three microscopy techniques. *Int Endod J.* 2009;42(10):908–21. doi:10.1111/j.1365-2591.2009.01594.x

46. Dr. Elisabeth Jacobi-Gresser. Risiken für chronische Entzündungen durch orale Reizfaktoren: Immunlabordiagnostik in der Zahnheilkunde. ZMK Allgemeine Zahnheilkunde. 2012.

47. Cai X, Cao C, Li J, Chen F, Zhang S, Liu B, Zhang W, Zhang X, Ye L. Inflammatory factor TNF- α promotes the growth of breast cancer via the positive feedback loop of TNFR1/NF- κ B (and/or p38)/p-STAT3/HBXIP/TNFR1. *Oncotarget.* 2017;8(35):58338–52. doi:10.18632/oncotarget.16873

- 48.** Wolczyk D, Zaremba-Czogalla M, Hryniewicz-Jankowska A, Tabola R, Grabowski K, Sikorski AF, Augoff K. TNF- α promotes breast cancer cell migration and enhances the concentration of membrane-associated proteases in lipid rafts. *Cell Oncol (Dordr)*. 2016;39(4):353–63. doi:10.1007/s13402-016-0280-x
- 49.** Psiram.com. Thomas Rau [Internet]. 2018 [updated 2018 Nov 5]. Available from: https://www.psimam.com/de/index.php/Thomas_Rau
- 50.** Aminoshariae A, Kulild JC, Mickel A, Fouad AF. Association between Systemic Diseases and Endodontic Outcome: A Systematic Review. *Journal of Endodontics*. 2017;43(4):514–9. doi:10.1016/j.joen.2016.11.008
- 51.** Murray CA, Saunders WP. Root canal treatment and general health: a review of the literature. *Int Endod J*. 2000;33(1):1–18. doi:10.1046/j.1365-2591.2000.00293.x
- 52.** Liljestrand JM, Mäntylä P, Paju S, Buhlin K, Kopra KAE, Persson GR, Hernandez M, Nieminen MS, Sinisalo J, Tjäderhane L, Pussinen PJ. Association of Endodontic Lesions with Coronary Artery Disease. *J Dent Res*. 2016;95(12):1358–65. doi:10.1177/0022034516660509
- 53.** Segura-Egea JJ, Martín-González J, Castellanos-Cosano L. Endodontic medicine: connections between apical periodontitis and systemic diseases. *Int Endod J*. 2015;48(10):933–51. doi:10.1111/iej.12507
- 54.** IMD Berlin. Lymphozytentransformationstest (LTT) Zahnersatzmaterialien können Allergien verursachen [Internet] [cited 2019 Nov 8]. Available from: <https://www.imd-berlin.de/spezielle-kompetenzen/zahnmedizin/allergien-und-unvertraeglichkeiten.html>
- 55.** Gleditsch JM. Reflexzonen und Somatotopien: Vom Mikrosystem zu einer Gesamtschau des Menschen. 9th ed.: Urban & Fischer; 2005. 1 online resource.
- 56.** Chung MK BTL. Neural Therapy: An Overlooked Game Changer for Patients Suffering Chronic Pain? *J Pain Relief*. 2015;04(03). doi:10.4172/2167-0846.1000184
- 57.** Mieg R. Krankheitsherd Zähne: Wie sich kranke Zähne auf den ganzen Körper auswirken ; mit vielen eindrücklichen Fallbeispielen ; [Probleme erkennen - Hilfe finden]. 6th ed. Stuttgart: Trias; 2010. 144 Seiten.
- 58.** Voll R. Wechselbeziehungen von Odontonen und Tonsillen zu Organen, Störfeldern und Gewebssystemen. 5th ed. Uelzen: Med.-Literarische Verl.-Ges; 1996.
- 59.** Hahn-Godeffroy JD. Procain in der Neuraltherapie nach Huneke: Literaturüberblick und zusammenfassende Bewertung Sonderdruck. Fortbildung und Praxis für den Hausarzt. 14/93;15876–83.
- 60.** Hahn-Godeffroy JD, Mangold S, Bernert M, Bartelt A, Herdegen T. Langanhaltende Besserung von somatischen und psychovegetativen Störungen unter Procain-Infusionen: Eine multizentrische Anwendungsbeobachtung. *Complement Med Res*. 2019;26(1):13–21. ger. doi:10.1159/000491692
- 61.** Lee JM, Suh JK, Jeong JS, Cho SY, Kim DW. Antioxidant effect of lidocaine and procaine on reactive oxygen species-induced endothelial dysfunction in the rabbit abdominal aorta. *Korean J Anesthesiol*. 2010;59(2):104–10. doi:10.4097/kjae.2010.59.2.104
- 62.** URM R, R O, H N. Procaine and Procaine-Base-Infusion: A Review of the Safety and Fields of Application after Twenty Years of Use. *Clin Res Open Access*. 2018;4(1). doi:10.16966/2469-6714.127
- 63.** Badtke G. Neuraltherapie: Lehrbuch und Atlas. 2nd ed. Wiesbaden: Ullstein Medical; 1998. 210 Seiten.
- 64.** wikipedia. Viszerokutaner Reflex [Internet]. Available from: https://de.wikipedia.org/wiki/Viszerokutaner_Reflex
- 65.** Orottox. Über Orottox [Internet]. 2019. Available from: <https://www.orotox.de/ueber-orotox/>

Different materials with different effects on the body

The cytotoxic, immunological and carcinogenic effects as well as the negative effects on the metabolism of various metals such as mercury (Hg), gold, platinum, copper, cobalt, aluminium, iron and chromium have been well documented in scientific research⁽¹⁻¹²⁾. Metal components can generally be detected anywhere in the body within a few days of being placed in the mouth. Dr. Ulrich Volz was able to prove this as early as 1992 in his Ulm University dissertation on the “Detection of amalgam invasion into the pulp tissue by means of neutron activation analysis and energy loss spectroscopy”⁽¹³⁾. These metals—in particular the highly toxic amalgam—are so toxic to our bodies because they bind to proteins, enzymes and cell membranes in ionized form (sulfhydryl groups) and can impair their function. This covalent bonding can completely block an enzyme’s function. In addition, metal ions from all dental alloys lyse in an aqueous medium (saliva) and thus corrode. They “rust”, so to speak, which results in the flow of a current that can be measured with simple instruments.

Their immunological effect is particularly dangerous, since these different forms of allergies (e.g. type IV) can trigger foreign-body-induced inflammation in the case of titanium, and autoimmune diseases as they delete the MHC code (1.5 b)^(1,14). The immune system considers practically every metal to be a foreign body. It forms antibodies against the metal or the combination of metal and surface features of the cell (hapten effect) in a process which plays an important role in the development of autoimmune diseases and neurodegenerative diseases such as MS, rheumatoid arthritis, ALS or Parkinson’s disease^(1,6). For this reason, a key step of the “THE SWISS BIOHEALTH CONCEPT” treatment protocol consists of removing all metal from the oral cavity. It goes without saying that appropriate protective measures must be taken during the removal.

Amalgam

Amalgam is an alloy which, apart from silver and various other metals, contains more than 50% mercury—the most toxic non-radioactive element on our planet. Amalgam is not a stable and homogenous alloy, but rather an “intermetallic compound” and assumes a gaseous state at room temperature. Mercury is stored in the liver, kidneys, the CNS, large intestine, the thyroid gland and fatty tissue. The half-life of mercury in the brain is 16–30 years⁽³⁾! Amalgam is still routinely used in most dental practices today. Firstly, because it is a material that is easy to handle and has a long

service life, and secondly, because it is subsidized by health insurance companies, i.e. it is free of charge for the patient.

In practice, amalgam has to be disposed of as highly toxic hazardous waste after its removal—this fact alone should give food for thought. Also, since July 1, 2018, dental amalgam may only be used in exceptional medical cases for children under 15 years of age, pregnant women and nursing mothers throughout the EU⁽¹⁵⁾. Contrary to common belief, the mercury content, which amounts to more than 50%, is not firmly bound to the alloy once it has been mixed⁽¹⁶⁾.

A certain amount of mercury vapor is released daily through chewing, grinding, brushing teeth and hot or cold drinks^(18, 19). Although this amount of mercury is in the microgram range, it should not be underestimated, considering that a single mercury molecule can destroy nerve cells⁽⁷⁾. In terms of its toxicity, Hg exceeds all other known elements such as lead, cadmium and arsenic, in some cases many times over⁽²⁰⁻²²⁾. Animal studies have detected pathological changes in the brain as early as 14 days after filling insertion^(23, 24).

Approximately 1–3 µg of mercury vapor is released daily per filling, and this over the entire wearing period of an average of 20 years⁽²⁵⁾. In effect, this constitutes low-dose, chronic poisoning. In numerous studies, a two- to five-fold increase in mercury levels in blood and urine was observed in living amalgam wearers. In studies on deceased patients, Hg levels were found to have increased by as much as two to twelve times in various body tissues. According to these studies, amalgam is the main source of mercury exposure in the human body^(9, 19, 26-44). Mercury is known to be able to

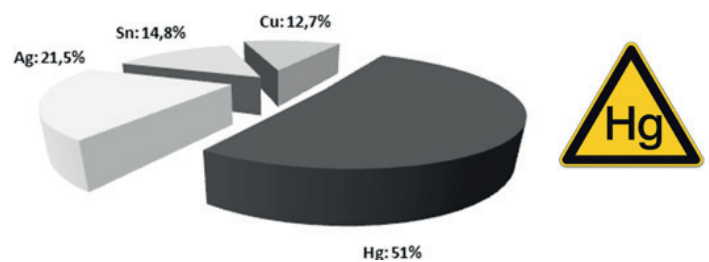


Figure 1: Typical composition of an amalgam filling: 51% mercury (Hg), 13% silver (Ag), 15% tin (Sn) and 21% copper (Cu)⁽¹⁷⁾

mimic any symptom and is not tolerated by the body for this very reason. The human body is extremely smart and stores fat-soluble toxins in metabolically inactive connective or fatty tissue whenever possible. In athletic people or people with a low percentage of body fat, however, toxins are often deposited in the nerve tissue or brain. Unborn babies and infants being breastfed are at particular risk as mercury crosses the placenta^(45, 46). The amount of mercury in breast milk and amniotic fluid clearly correlates with the number of maternal amalgam fillings^(30, 45-55). As amalgam fillings are the main source of poisoning with mercury and other heavy metals, they should be removed for preventive reasons, regardless of whether or not the patient is already chronically ill.

Dental metal alloys

Neither gold, nickel, palladium, silver, platinum nor titanium are biologically present in the human organism. However, they are routinely used in dental alloys. This is aggravated by the fact that, according to the German Medical Devices Act (MPG), any components that account for less than 1% of a material do not have to be declared. In contrast to the toxicity of the highly toxic mercury found in amalgam, tolerance of the above-mentioned metals mainly depends on an individual's immune system. These metals inevitably constitute foreign bodies, which are either tolerated or attacked, depending on the defence readiness of a person's immune system. This can lead to mild inflammation, which may, at times, manifest only locally as bleeding gums. Equally, however, it may cause severe allergies or even autoimmune diseases⁽⁵⁶⁻⁵⁸⁾. Unfortunately, the cause of these diseases generally remains unrecognized, and they are treated with symptomatic therapies. This chronic, low-dose activation of the immune system consumes at least 30% of a patient's physical energy every day. Chronic fatigue is therefore not uncommon. In some patients, the immune response manifests itself every morning as limb pain, sluggishness and even as a slightly elevated temperature. They constantly feel "slightly ill", as it were. This situation is exacerbated by the so-called battery effect (different metals acting as galvanic elements), the resulting increased corrosion of metal ions and attachment to the body's own proteins, cell membranes and enzymes, as well as the antenna effect of all metals⁽⁵⁹⁻⁶³⁾.

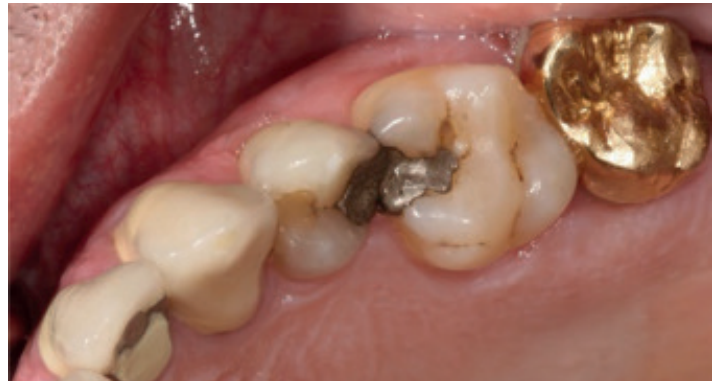

Figure 2: A battery is created when two different metals are placed in a conductive solution. In accordance with the electrochemical voltage series, the less noble metal ions lyse and flow towards the more noble metal. Electrons are released and a current begins to flow. Due to its high mineral content, saliva is an ideal electrolytic solution.

A typical example is a gold crown next to an amalgam filling or a gold abutment on a titanium implant. The resulting comparatively high dental oral currents cause the metals to corrode during the wearing time, further intensifying the negative effect of these metals.

Another problem area is increasing electrosensitivity due to the exponential propagation of electromagnetic fields generated by WLANs and cell phones. Nowadays, it is virtually impossible to avoid electrosmog. Metals inside the body act like small antennas. They can completely disrupt a cell's action potential. Voltage fields are created, which disturb the sensitive central nervous system⁽⁶⁴⁾. The standard absorption rate of electromagnetic fields can be 400-700 times higher when a person with metal in their mouth is using a cell phone (if their phone is ringing or they are receiving a text message)⁽⁶⁵⁾. Metals can scatter, reflect, modulate and amplify electromagnetic radiation in an uncontrolled manner, thus heating up the surrounding tissue. Titanium implants, in particular, which, due to their shape, are especially suited to act as antennas, heat up the

surrounding bone tissue by several degrees Celsius within 3G or 4G network range. Microwave radiation always causes metals to heat up (think of a metal spoon inside a microwave oven). Electrogalvanism and the resulting electro-sensitivity can frequently cause lack of concentration, memory loss, insomnia, unspecific symptoms such as sharp pain or a feeling of pressure in the chest, unexplained palpitations, tinnitus and hearing loss⁽⁶⁶⁾.

Titanium implants or screws

According to Dr. Volker von Baehr (www.imd-berlin.de), 15% of the German population suffers from titanium intolerance⁽⁶⁷⁾, which is mainly caused by the extensive use of titanium dioxide as food additive E171. Prof. Vera Stejskal from the Karolinska Institute (www.melisa.org) considers the intolerance ratio to be even higher. So does Dr. Bernd Bremer, Senior Physician at the Hanover University Medical Materials Science Institute: He estimates that the intolerance level may be as high as 50% and is currently conducting a study on this topic (personal message to Dr. Volz). His estimate correlates with the officially accepted mucositis / peri-implantitis ratio of 80%, or 28-56%, respectively⁽⁶⁸⁾. According to Dr. Volz, peri-implantitis is nothing more than the clinical expression of an intolerance. A paper published in Düsseldorf on the occasion of the 2014 annual meeting of the German Society for Implantology (DGI) by Freiburg University successfully demonstrated the presence of titanium particles in the surrounding soft and hard tissue in just under 80% of peri-implantitis cases. Recent studies and lectures by well-known authors and speakers such as Prof. Therheyden, former DGI chairman, have also confirmed this and described what they called titanium “rusting”.

The corrosion of titanium surfaces causes titanium oxide particles to detach and infiltrate the surrounding tissue, and may be associated with the development of peri-implantitis and implant loss⁽⁶⁹⁻⁷³⁾. Moreover, particle release may also be a result of mechanical friction during implant insertion and/or micromovements of the loaded implant^(70, 74). Macrophages react to titanium oxide particles in tissue with an inflammatory response and release pro-inflammatory cytokines such as TNF- α and IL-1 β . Osteoclasts are activated and bone and tissue resorption may occur^(14, 75-77). In addition to the local effects mentioned above, the cytokines released in conjunction with this chronic immune reaction also have systemic effects on many types of tissue such as muscles, the vascular endothelium and the nervous sys-

tem⁽⁷⁸⁾. Systemic diseases such as rheumatoid arthritis, multiple sclerosis, tumors, breast carcinomas and cardiovascular diseases can be triggered by titanium implants, since TNF- α and similar cytokines are overexpressed through RANTES⁽⁷⁹⁾. Sterner et al. have been able to show that, conversely, zirconia particles of equal size do not induce a significant inflammatory immune response (TNF- α)⁽⁷⁶⁾. A connection with the development of autoimmune reactions is also being examined⁽¹⁾. Furthermore, titanium oxide nanoparticles are cytotoxic and genotoxic and can cause oxidative stress^(5,80,81). Some studies associate neoplasia such as osteosarcomas, plasmacytomas or metastatic breast carcinomas with dental titanium implants⁽⁸²⁻⁸⁴⁾. A study by Weingart et al. detected titanium oxide particles in regional lymph nodes⁽⁸⁵⁾. As described above, titanium implants—like all other dental metals—act as small antennas for electromagnetic fields. In a clinical study by Fujii, patients with titanium implants experienced balance disorders caused by the titanium implants’ amplification of electromagnetic waves⁽⁸⁶⁾. The titanium stimulation test (a blood test) can be used to examine whether there is a pre-existing intolerance to titanium dioxide⁽¹⁴⁾. Inflamed tissue around an implant may already suggest an intolerance. If this is the case, these implants should be removed during treatment and replaced with fully ceramic implants.

References

1. Stejskal J, Stejskal V. The role of metals in autoimmunity and the link to neuroendocrinology. *Neuro Endocrinol Lett.* 1999;20351-64.
2. Mutter J, Klinghardt D. Amalgam: Risiko für die Menschheit; Quecksilbervergiftungen richtig ausleiten, neue Fakten und Hilfe, auch nach der Amalgamentfernung! 3rd ed. Weil der Stadt: Fit-fürs-Leben-Verl. in der NaturaViva-Verl.-GmbH; 2013. 169 Seiten.
3. Mutter J. Gesund statt chronisch krank!: Der ganzheitliche Weg: Vorbeugung und Heilung sind möglich. 3rd ed. Weil der Stadt: Fit fürs Leben Verlag; 2014. 456 Seiten.
4. Bernhoft RA. Mercury toxicity and treatment: a review of the literature. *J Environ Public Health.* 2012;2012460508. doi:10.1155/2012/460508
5. Khan M, Naqvi AH, Ahmad M. Comparative study of the cytotoxic and genotoxic potentials of zinc oxide and titanium dioxide nanoparticles. *Toxicol Rep.* 2015;2765-74. doi:10.1016/j.toxrep.2015.02.004
6. Bjorklund G, Stejskal V, Urbina MA, Dadar M, Chirumbolo S, Mutter J. Metals and Parkinson's Disease: Mechanisms and Biochemical Processes. *Curr Med Chem.* 2018;25(19):2198-214. doi:10.2174/0929867325666171129124616
7. Cariccio VL, Samà A, Bramanti P, Mazzon E. Mercury Involvement in Neuronal Damage and in Neurodegenerative Diseases. *Biol Trace Elem Res.* 2019;187(2):341-56. doi:10.1007/s12011-018-1380-4
8. Ingalls TH. Endemic clustering of multiple sclerosis in time and place, 1934-1984. Confirmation of a hypothesis. *Am J Forensic Med Pathol.* 1986;7(1):3-8. doi:10.1097/00000433-198603000-00002
9. Mutter J. Is dental amalgam safe for humans? The opinion of the scientific committee of the European Commission. *Journal of occupational medicine and toxicology (London, England).* 2011;62. doi:10.1186/1745-6673-6-2
10. Sibley RL. The relationship between mercury from dental amalgam and the cardiovascular system. *Science of The Total Environment.* 1990;99(1-2):23-35. doi:10.1016/0048-9697(90)90207-b
11. Sibley RL, Motl J, Kienholz E. Psychometric evidence that mercury from silver dental fillings may be an etiological factor in depression, excessive anger, and anxiety. *Psychol Rep.* 1994;74(1):67-80. doi:10.2466/pr0.1994.74.1.67
12. Wojcik DP, Godfrey ME, Christie D, Haley BE. Mercury toxicity presenting as chronic fatigue, memory impairment and depression: diagnosis, treatment, susceptibility, and outcomes in a New Zealand general practice setting (1994-2006). *Neuro Endocrinol Lett.* 2006;27(4):415-23.
13. Volz U. Qualitative Untersuchungen zur Amalgaminvasion in die Zahnpulpa.: Inaugural-Dissertation zur Erlangung der Doktorwürde. Ulm;1992.
14. IMD Berlin. Titan-Unverträglichkeit [Internet]. Available from: <https://www.imd-berlin.de/fachinformationen/diagnostikinformationen/titan-unvertraeglichkeit.html>
15. Christian Nobmann. Die neuen Regelungen zu Amalgam. *zm online [Internet].* 2018;(13). Available from: <https://www.zm-online.de/archiv/2018/13/titel/die-neuen-regelungen-zu-amalgam/>
16. Bengtsson UG, Hylander LD. Increased mercury emissions from modern dental amalgams. *Biometals.* 2017;30(2):277-83. doi:10.1007/s10534-017-0004-3
17. COS Zahnärzte. Über Amalgam [Internet]. Available from: <https://zahnarzt-amalgamsanierung.de/ueber-amalgam.html>
18. Taskinen H, Kinnunen E, Riihimäki V. A possible case of mercury-related toxicity resulting from the grinding of old amalgam restorations. *Scandinavian Journal of Work, Environment & Health [Internet].* 1989;15(4):302-4. Available from: <http://www.jstor.org/stable/40965672>
19. Eggleston DW, Nylander M. Correlation of dental amalgam with mercury in brain tissue. *The Journal of Prosthetic Dentistry.* 1987;58(6):704-7. doi:10.1016/0022-3913(87)90424-0
20. Thier R, Bonacker D, Stoiber T, Böhm KJ, Wang M, Unger E, Bolt HM, Degen G. Interaction of metal salts with cytoskeletal motor protein systems. *Toxicol Lett.* 2003;140-14175-81. doi:10.1016/S0378-4274(02)00502-7
21. Stoiber T, Degen GH, Bolt HM, Unger E. Interaction of mercury(II) with the microtubule cytoskeleton in IMR-32 neuroblastoma cells. *Toxicol Lett.* 2004;151(1):99-104. doi:10.1016/j.toxlet.2003.11.017
22. Stoiber T, Bonacker D, Böhm KJ, Bolt HM, Thier R, Degen GH, Unger E. Disturbed microtubule function and induction of micronuclei by chelate complexes of mercury(II). *Mutat Res.* 2004;563(2):97-106. doi:10.1016/j.mrgentox.2004.06.009
23. Pendergrass JC HBE. Mercury-EDTA Complex Specifically Blocks Brain-Tubulin-GTP Interactions: Similarity to Observations in Alzheimer's Disease. In *Status Quo and Perspective of Amalgam and Other Dental Materials. International Symposium Proceedings.* Edited by Friberg LT, Schrauzer GN. Stuttgart: Thieme Verlag;1995 98-105.
24. Pendergrass JC, Haley BE. Inhibition of brain tubulin-guanosine 5'-triphosphate interactions by mercury: similarity to observations in Alzheimer's diseased brain. *Met Ions Biol Syst.* 1997;34461-78.
25. Mackert JR, Berglund A. Mercury exposure from dental amalgam fillings: absorbed dose and the potential for adverse health effects. *Crit Rev Oral Biol Med.* 1997;8(4):410-36.
26. Barregård L, Svalander C, Schütz A, Westberg G, Sällsten G, Blohmé I, Mölne J, Attman PO, Haglind P. Cadmium,

- mercury, and lead in kidney cortex of the general Swedish population: a study of biopsies from living kidney donors. *Environ Health Perspect.* 1999;107(11):867-71. doi:10.1289/ehp.107-1566723
- 27.** Becker K, Kaus S, Krause C, Lepom P, Schulz C, Seiwert M, Seifert B. German Environmental Survey 1998 (GerES III): environmental pollutants in blood of the German population. *Int J Hyg Environ Health.* 2002;205(4):297-308. doi:10.1078/1438-4639-00155
- 28.** Becker K, Schulz C, Kaus S, Seiwert M, Seifert B. German Environmental Survey 1998 (GerES III): environmental pollutants in the urine of the German population. *Int J Hyg Environ Health.* 2003;206(1):15-24. doi:10.1078/1438-4639-00188
- 29.** Drasch G, Schupp I, Riedl G, Günther G. Einfluß von Amalgamfüllungen auf die Quecksilberkonzentration in menschlichen Organen. *Dtsch Zahnärztl Z;*1992(08):490-6.
- 30.** Drasch G, Schupp I, Höfl H, Reinke R, Roeder G. Mercury burden of human fetal and infant tissues. *European Journal of Pediatrics.* 1994;153(8):607-10. doi:10.1007/BF02190671
- 31.** Drasch G, Wanghofer E, Roeder G. Are blood, urine, hair, and muscle valid bio-monitoring parameters for the internal burden of men with the heavy metals mercury, lead and cadmium? *Trace Elem Electrolyt;*1997(14):116-23.
- 32.** Gottwald B, Traenckner I, Kupfer J, Ganss C, Eis D, Schill WB, Gieler U. „Amalgam disease“--poisoning, allergy, or psychic disorder? *Int J Hyg Environ Health.* 2001;204(4):223-9. doi:10.1078/1438-4639-00097
- 33.** Guzzi G, Grandi M, Cattaneo C. Should amalgam fillings be removed? *Lancet;*2002(380):2081.
- 34.** Guzzi G, Grandi M, Cattaneo C, Calza S, Minoia C, Ronchi A, Gatti A, Severi G. Dental amalgam and mercury levels in autopsy tissues: food for thought. *Am J Forensic Med Pathol.* 2006;27(1):42-5. doi:10.1097/01.paf.0000201177.62921.c8
- 35.** Levy M, Schwartz S, Dijk M, Weber J-P, Tardif R, Rouah F. Childhood urine mercury excretion: dental amalgam and fish consumption as exposure factors. *Environ Res.* 2004;94(3):283-90. doi:10.1016/j.envres.2003.07.004
- 36.** Lorscheider FL, Vimy MJ, Summers AO. Mercury exposure from „silver“ tooth fillings: emerging evidence questions a traditional dental paradigm. *The FASEB Journal.* 1995;9(7):504-8. doi:10.1096/fasebj.9.7.7737458
- 37.** Kingman A, Albertini T, Brown LJ. Mercury concentrations in urine and whole blood associated with amalgam exposure in a US military population. *J Dent Res.* 1998;77(3):461-71. doi:10.1177/00220345980770030501
- 38.** Mortada W, Sobh M, M El-Defrawy M, E Farahat S. Mercury in dental restoration: Is there a risk of nephrotoxicity? *Journal of nephrology.* 2002;15171-6.
- 39.** Nylander M. MERCURY IN PITUITARY GLANDS OF DENTISTS. *The Lancet.* 1986;327(8478):442. doi:10.1016/s0140-6736(86)92395-0
- 40.** Nylander M, Weiner J. Mercury and selenium concentrations and their interrelations in organs from dental staff and the general population. *Br J Ind Med.* 1991;48(11):729-34. doi:10.1136/oem.48.11.729
- 41.** Nylander M, Friberg L, Lind B. Mercury concentrations in the human brain and kidneys in relation to exposure from dental amalgam fillings. *Swed Dent J.* 1987;11(5):179-87.
- 42.** Pizzichini M, Fonzi M, Giannerini F, Mencarelli M, Gasparoni A, Rocchi G, Kaitsas V, Fonzi L. Influence of amalgam fillings on Hg levels and total antioxidant activity in plasma of healthy donors. *Science of The Total Environment.* 2003;301(1-3):43-50. doi:10.1016/S0048-9697(02)00291-7
- 43.** AXELWEINER J, Nylander M. The relationship between mercury concentration in human organs and different predictor variables. *Science of The Total Environment.* 1993;138(1-3):101-15doi:10.1016/0048-9697(93)90408-X
- 44.** Zimmer H, Ludwig H, Bader M, Bailer J, Eickholz P, Staehle HJ, Triebig G. Determination of mercury in blood, urine and saliva for the biological monitoring of an exposure from amalgam fillings in a group with self-reported adverse health effects. *Int J Hyg Environ Health.* 2002;205(3):205-11. doi:10.1078/1438-4639-00146
- 45.** Ask K, Akesson A, Berglund M, Vahter M. Inorganic mercury and methylmercury in placentas of Swedish women. *Environ Health Perspect.* 2002;110(5):523-6. doi:10.1289/ehp.02110523
- 46.** Takahashi Y. Placental transfer of mercury in pregnant rats which received dental amalgam restorations. *Toxicology.* 2003;185(1-2):23-33. doi:10.1016/S0300-483X(02)00588-7
- 47.** Holmes AS, Blaxill MF, Haley BE. Reduced levels of mercury in first baby haircuts of autistic children. *Int J Toxicol.* 2003;22(4):277-85. doi:10.1080/10915810305120
- 48.** Morgan DL, Chanda SM, Price HC, Fernando R, Liu J, Brambila E, O'Connor RW, Beliles RP, Barone S. Disposition of inhaled mercury vapor in pregnant rats: maternal toxicity and effects on developmental outcome. *Toxicol Sci.* 2002;66(2):261-73. doi:10.1093/toxsci/66.2.261
- 49.** Takahashi Y. Release of mercury from dental amalgam fillings in pregnant rats and distribution of mercury in maternal and fetal tissues. *Toxicology.* 2001;163(2-3):115-26. doi:10.1016/S0300-483X(01)00390-0
- 50.** Vahter M, Akesson A, Lind B, Björs U, Schütz A, Berglund M. Longitudinal study of methylmercury and inorganic mercury in blood and urine of pregnant and lactating women, as well as in umbilical cord blood. *Environ Res.* 2000;84(2):186-94. doi:10.1006/enrs.2000.4098
- 51.** Yoshida M, Satoh M, Shimada A, Yamamoto E, Yasutake

- A, Tohyama C. Maternal-to-fetus transfer of mercury in metallothionein-null pregnant mice after exposure to mercury vapor. *Toxicology*. 2002;175(1-3):215-22. doi:10.1016/S0300-483X(02)00084-7
- 52.** Yoshida M, Watanabe C, Satoh M, Yasutake A, Sawada M, Ohtsuka Y, Akama Y, Tohyama C. Susceptibility of metallothionein-null mice to the behavioral alterations caused by exposure to mercury vapor at human-relevant concentration. *Toxicol Sci*. 2004;80(1):69-73. doi:10.1093/toxsci/kfh138
- 53.** Drasch G, Aigner S, Roeder G, Staiger F, Lipowsky G. Mercury in human colostrum and early breast milk. Its dependence on dental amalgam and other factors. *J Trace Elem Med Biol*. 1998;12(1):23-7.
- 54.** Oskarsson A, Schültz A, Skerfving S, Hallén IP, Ohlin B, Lagerkvist BJ. Total and inorganic mercury in breast milk in relation to fish consumption and amalgam in lactating women. *Arch Environ Health*. 1996;51(3):234-41. doi:10.1080/00039896.1996.9936021
- 55.** Vimy MJ, Hooper DE, King WW, Lorscheider FL. Mercury from maternal "silver" tooth fillings in sheep and human breast milk. *Biol Trace Elem Res*. 1997;56(2):143-52. doi:10.1007/BF02785388
- 56.** McKee A, Fontenot A. Interplay of innate and adaptive immunity in metal-induced hypersensitivity. *Current Opinion in Immunology*. 2016;4225-30. doi:10.1016/j.coi.2016.05.001
- 57.** Saravanakumar P, Thallam Veeravalli P, Kumar V A, Mohamed K, Mani U, Grover M, Thirumalai Thangarajan S. Effect of Different Crown Materials on the Interleukin-One Beta Content of Gingival Crevicular Fluid in Endodontically Treated Molars: An Original Research. *Cureus*. 2017;9(6):e1361. doi:10.7759/cureus.1361
- 58.** Lehmann I, Sack U, Lehmann J. Metal ions affecting the immune system. *Met Ions Life Sci*. 2011;8157-85.
- 59.** Zohdi H, Emami M, Reza H. Galvanic Corrosion Behavior of Dental Alloys. In: Valdez B, editor. *Environmental and Industrial Corrosion - Practical and Theoretical Aspects*: InTech; 2012.
- 60.** Procházková J, Podzimek S, Tomka M, Kucerová H, Mihaljevic M, Hána K, Mikšovský M, Sterzl I, Vinsová J. Metal alloys in the oral cavity as a cause of oral discomfort in sensitive patients. *Neuro Endocrinol Lett*. 2006;27 Suppl 153-8.
- 61.** Johansson BI. Electrochemical action due to short-circuiting of dental alloys. An in vitro and in vivo study. *Swed Dent J Suppl*. 1986;331-47.
- 62.** Ciszewski A, Baraniak M, Urbanek-Brychczyńska M. Corrosion by galvanic coupling between amalgam and different chromium-based alloys. *Dent Mater*. 2007;23(10):1256-61. doi:10.1016/j.dental.2006.11.006
- 63.** Taher NM, Al Jabab AS. Galvanic corrosion behavior of implant suprastructure dental alloys. *Dent Mater*. 2003;19(1):54-9.
- 64.** Dr. med. dent. Johann Lechner. Immunstress durch Zahnmetalle und Elektromog. *Raum&Zeit*;1995(74):5-13.
- 65.** Virtanen H, Huttunen J, Toropainen A, Lappalainen R. Interaction of mobile phones with superficial passive metallic implants. *Phys Med Biol*. 2005;50(11):2689-700. doi:10.1088/0031-9155/50/11/017
- 66.** Klinghardt D. *Neural Therapy & Mesotherapy Course A: The Intensive Klinghardt Academy*;201180-2.
- 67.** Schütt S, Von Baehr V. Hyperreaktivität von Gewebemakrophagen nach Kontakt mit Titanoxidpartikeln als Ursache einer verstärkten lokalen Entzündungsreaktion bei Patienten mit Periimplantitis. *ZWR - Das Deutsche Zahnärzteblatt*;2010(119):222-32.
- 68.** Lindhe J, Meyle J. Peri-implant diseases: Consensus Report of the Sixth European Workshop on Periodontology. *J Clin Periodontol*. 2008;35(8 Suppl):282-5. doi:10.1111/j.1600-051X.2008.01283.x
- 69.** Barão VAR, Yoon CJ, Mathew MT, Yuan JC-C, Wu CD, Sukotjo C. Attachment of *Porphyromonas gingivalis* to corroded commercially pure titanium and titanium-aluminum-vanadium alloy. *J Periodontol*. 2014;85(9):1275-82. doi:10.1902/jop.2014.130595
- 70.** Delgado-Ruiz R, Romanos G. Potential Causes of Titanium Particle and Ion Release in Implant Dentistry: A Systematic Review. *Int J Mol Sci*. 2018;19(11). doi:10.3390/ijms19113585
- 71.** Safioti LM, Kotsakis GA, Pozhitkov AE, Chung WO, Daubert DM. Increased Levels of Dissolved Titanium Are Associated With Peri-Implantitis - A Cross-Sectional Study. *J Periodontol*. 2017;88(5):436-42. doi:10.1902/jop.2016.160524
- 72.** Fretwurst T, Nelson K, Tarnow DP, Wang H-L, Giannobile WV. Is Metal Particle Release Associated with Peri-implant Bone Destruction? An Emerging Concept. *J Dent Res*. 2018;97(3):259-65. doi:10.1177/0022034517740560
- 73.** Apaza-Bedoya K, Tarce M, Benfatti CAM, Henriques B, Mathew MT, Teughels W, Souza JCM. Synergistic interactions between corrosion and wear at titanium-based dental implant connections: A scoping review. *J Periodont Res*. 2017;52(6):946-54. doi:10.1111/jre.12469
- 74.** Senna P, Antoninha Del Bel Cury A, Kates S, Meirelles L. Surface Damage on Dental Implants with Release of Loose Particles after Insertion into Bone. *Clin Implant Dent Relat Res*. 2015;17(4):681-92. doi:10.1111/cid.12167
- 75.** Olmedo D, Fernández MM, Guglielmotti MB, Cabrini RL. Macrophages related to dental implant failure. *Implant Dent*. 2003;12(1):75-80. doi:10.1097/01.id.0000041425.36813.a9

- 76.** Sterner T, Schütze N, Saxler G, Jakob F, Rader CP. Auswirkungen von klinisch relevanten Aluminium Keramik-, Zirkonium Keramik- und Titanpartikel unterschiedlicher Grösse und Konzentration auf die TNFalpha-Ausschüttung in einem humanen Makrophagensystem [Effects of clinically relevant alumina ceramic, zirconia ceramic and titanium particles of different sizes and concentrations on TNF-alpha release in a human macrophage cell line]. *Biomed Tech (Berl)*. 2004;49(12):340-4. ger. doi:10.1515/BMT.2004.063
- 77.** Hallab NJ, Jacobs JJ. Biologic effects of implant debris. *Bull NYU Hosp Jt Dis*. 2009;67(2):182-8.
- 78.** Jacobi-Gresser E. Pathogenese der Periimplantitis. *Dentale Implantologie & Parodontologie [Internet];08.2019*. Available from: https://www.dimagazin-aktuell.de/implantologie/periimplantitis/story/pathogenese-der-periimplantitis__6705.html
- 79.** Lechner J, Noubissi S, Baehr V v. Titanium implants and silent inflammation in jawbone-a critical interplay of dissolved titanium particles and cytokines TNF- α and RANTES/CCL5 on overall health? *EPMA J*. 2018;9(3):331-43. doi:10.1007/s13167-018-0138-6
- 80.** Hedenborg M. Titanium dioxide induced chemiluminescence of human polymorphonuclear leukocytes. *International Archives of Occupational and Environmental Health*. 1988;61(1):1-6. doi:10.1007/BF00381600
- 81.** Stejskal VDM, Danersund A, Lindvall A, Hudecek R, Nordman V, Yaqob A, Mayer W, Bieger W, Lindh U. Metal-specific lymphocytes: biomarkers of sensitivity in man. *Neuro Endocrinol Lett*. 1999;20(5):289-98.
- 82.** McGuff HS, Heim-Hall J, Holsinger FC, Jones AA, O'Dell DS, Hafemeister AC. Maxillary osteosarcoma associated with a dental implant: report of a case and review of the literature regarding implant-related sarcomas. *J Am Dent Assoc*. 2008;139(8):1052-9. doi:10.14219/jada.archive.2008.0307
- 83.** Poggio CE. Plasmacytoma of the mandible associated with a dental implant failure: a clinical report. *Clin Oral Implants Res*. 2007;18(4):540-3. doi:10.1111/j.1600-0501.2007.01361.x
- 84.** Dib LL, Soares AL, Sandoval RL, Nannmark U. Breast metastasis around dental implants: a case report. *Clin Implant Dent Relat Res*. 2007;9(2):112-5. doi:10.1111/j.1708-8208.2007.00033.x
- 85.** Weingart D, Steinemann S, Schilli W, Strub JR, Hellerich U, Assenmacher J, Simpson J. Titanium deposition in regional lymph nodes after insertion of titanium screw implants in maxillofacial region. *International Journal of Oral and Maxillofacial Surgery*. 1994;23(6):450-2. doi:10.1016/S0901-5027(05)80045-1
- 86.** Fujii Y. Sensation of Balance Dysregulation Caused/Aggravated by a Collection of Electromagnetic Waves in a Dental Implant. *OJAPr*. 2014;02(03):29-35. doi:10.4236/ojapr.2014.23004

“Biological dentistry” refers to dentistry which looks at the human organism from a “bio-logical” perspective. Seen in this light, it becomes apparent that the masticatory system is very closely connected to the rest of the body and is located in the direct vicinity of some of our most important organs. After all, almost all the sensory organs are arranged around our mouths, and the brain is very close by. The importance of the masticatory system is also reflected in the fact that the fifth cranial nerve (trigeminal nerve), which supplies the masticatory system, is the largest cranial nerve ⁽¹⁾, occupying 50% of the space of all the cranial nerves.

Another important consideration is the fact that the masticatory system is linked with the entire organism through the system of meridians. These not only run through the dental system but are also constantly activated by the approximately 15,000 tooth contacts we make every day. Toothlessness therefore results in atrophy of the associated meridian, which can only be partially compensated for by treatments such as acupuncture or reflexology. It is vital that gaps between teeth be closed as quickly as possible using neutral ceramic implants so that the affected meridians can be adequately activated once again.

The condition of the temporomandibular joint also plays a major role. It governs the statics of the spinal column as well as blood supply to the brain and venous outflow from the brain. Loss of bite height compresses the region of the large blood vessels in the neck, and can thereby restrict blood flow to the brain⁽²⁾. A loss of just 1 mm in bite height reduces the blood supply to the brain by around 50%. A correlation between loss of bite height and neurodegenerative diseases such as dementia and cognitive disorders has also been found⁽³⁻⁶⁾. Moreover, effective drainage of toxins and waste products from the brain requires the jugular vein to be sufficiently wide. The brain does not have a lymphatic system with which to remove these substances, instead relying on the glymphatic system to accomplish this task. During the night, our brain cells shrink by up to 60% and thus generate a cavity between the cells through which toxins can drain off ^(7,8). This system can only function effectively, however, if all sources of stress are deactivated at night. This includes all EMF sources such as mobile phones, WLAN, etc. Compared to the oral system, there is no other organ or part of the body that is loaded to such an extent with heavy metals, alloys, toxic materials, dead organs and inflammation. Indeed, dentistry is the only medical discipline which tolerates leaving a dead organ in the body.

In our modern times, a further serious disturbing factor lies in the fact that the gingiva is part of the ectoderm (= outside of the body), whereas the bone is part of the mesoderm (= inside of the body). If we eat something toxic, it remains outside the ectoderm, i.e. on the outside of our body—in the oral cavity, stomach and intestines. Only when it has been absorbed is it located in the mesoderm or endoderm. If the bond between gingiva (= ectoderm) and bone (= mesoderm) is destroyed, as is the case with periodontitis in the majority of the population, then pathogens and toxins can enter the body directly like a Trojan horse. This is a shock to the immune system and is the reason why gum disease seriously increases the risk of heart disease⁽⁹⁻¹³⁾. Ceramic implants boast an outstanding benefit here because the gingiva attaches to the ceramic surface⁽¹⁴⁾, thus firmly closing the “immunological door” once again. Conversely, gingiva never attaches to titanium, which means that titanium implants leave the immunological door open for life. Taking all of these factors together, it is not surprising that experts estimate that more than 60% of all chronic diseases involve disruptive issues associated with the teeth.

At the center of this knowledge about the relationship between disorders in the masticatory system and the rest of the organism lies the concept of “focal infection”. Put simply, this means that there is a nidus/focus of infection somewhere in the body which can cause a response or disturbance in a completely different part of the body⁽¹⁵⁾. This term was coined by probably the most famous dentist of all time, Dr. Weston Price, who was President of Research and Education at the American Dental Association (ADA) for over 30 years and who had long been aware of the need to eliminate these foci⁽¹⁶⁾. His work has been continued by eminent biological dentists and doctors such as Thomas Levy, Johann Lechner, Boyd Haley, Dietrich Klinghardt, Joachim Mutter and many others. Until recently, however, the dilemma was that the necessary “clean-up work” in the mouth often left behind a “field of destruction” with gaps which required further treatment with prostheses and bone augmentation. Patients were often left unable to socialize for weeks, suffered from severe pain and massive swelling, and in some cases spent years trying to regain a reasonable anatomical and esthetic result.

This was the handicap of holistic dentistry in the past. Patients understood the need for radical therapy along the road to recovery, but could not be given an optimum result using the solutions available.

Biological dentistry provides the answer to this problem, and involves comprehensively recognizing the logical relationships at play, incorporating them into every step in the process, and deriving from them a treatment concept that is both simple and highly effective. In the first step, all non-biological or non-neutral materials as well as all dead organ parts and foci of inflammation are removed under maximum protective conditions. During this process, the immune system is activated and not further weakened by the use of chemical drugs. In the second step, the masticatory system is preserved and reconstructed using metal-free and neutral materials, always with the aim of preserving or restoring the anatomy, bone and soft tissue, and thus the esthetics.

Biological dentistry versus holistic / naturopathic dentistry

Prior to the era of biological dentistry with the possibilities which it offers today, a less radical but also less effective discipline was established. Known as holistic or naturopathic dentistry, it attempted to diagnose and alleviate disorders using assessment methods and therapies which were mostly subjective (in other words, they were not reproducible or scientifically proven). For example, metals which had previously been tested continued to be used in the form of “bio-alloys”, and attempts were made to positively influence dental nidi with neural therapy instead of removing them.

Successes were certainly achieved, but they could not compensate for the extent to which the masticatory system is involved in chronic disease. Biological dentistry requires excellent, highly-experienced surgeons who are capable of carefully removing complicatedly displaced wisdom teeth, inflammation or foreign bodies near nerves or maxillary sinuses or extremely ankylotic root-treated teeth while preserving the bone. In the past, surgeons trained and working at a high level were not particularly fond of “holistic dentistry” and usually dismissed it as an esoteric trend. Then again, holistic dentists had not undergone the surgical training that would have enabled them to radically eliminate the aforementioned disorders surgically instead of merely trying to alleviate them.

Happily, a great deal of change has taken place in recent times. A growing number of experienced oral and maxillo-facial surgeons are now implementing THE SWISS



Figure 1: Firmly attached gingiva (stained blue) on the zirconia implant in a zirconia-epithelial connection.

BIOHEALTH CONCEPT, an unprecedented solution for biological dentistry pioneered and fully proven by Dr. Volz over the past two decades. In addition to ceramic implants, they are also offering other treatments like wisdom tooth extraction using the new concept.

The SWISS BIOHEALTH CONCEPT

Thanks to Dr. Volz’s biological dentistry concept, we have since 2001 been able to restore the gaps left behind by radical reconstructive surgery in a completely neutral and metal-free manner using the ceramic implants developed by Dr. Volz himself. Since the introduction of the Short-Cut Concept (SCC) according to Dr. Volz in 2014, we have for the first time in dental history been able to fill these gaps with ceramic implants and fixed restorations in a single course of treatment—sometimes even in a single session—without the patient having to endure significant pain or swelling but instead being fit and feeling presentable again in just a few days. At the same time, the anatomy, bone and gingiva are preserved, thus respecting the principle of physical integrity. Our best “proof of concept” lies in the fact that Dr. Volz’s largest group of patients are dentists themselves, particularly implantologists, closely followed by alternative practitioners, doctors of biological medicine and therapists. What these professionals recognize is the fact that our immediate implant protocol offers a solution to a problem which has been central to dentistry for over 100 years - namely how to thoroughly eliminate interference fields and treat the inevitable gaps in a biocompatible way that patients approve of and gladly accept. Countless patients who knew that they needed therapy but were not prepared to accept the solutions on offer or who did not get adequate care are now receiving help in practices and clinics that offer the Short-Cut Concept (SCC) according to Dr. Volz, the ALL IN ONE CONCEPT and THE SWISS BIOHEALTH CONCEPT.

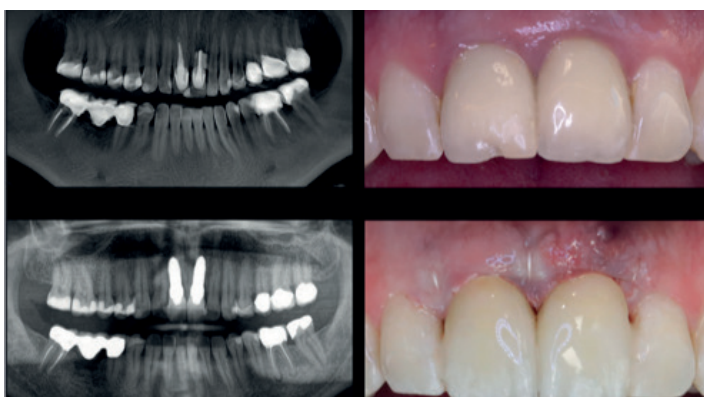

Figure 2: Removal of the upper two front teeth with immediate implant placement and immediate temporaries (bottom). Not only did the patient's disc problems "disappear" immediately after surgery, but the temporary restoration was already more visually attractive than the old ceramic crowns.

The ALL IN ONE CONCEPT and MY BIOHEALTH WEEK

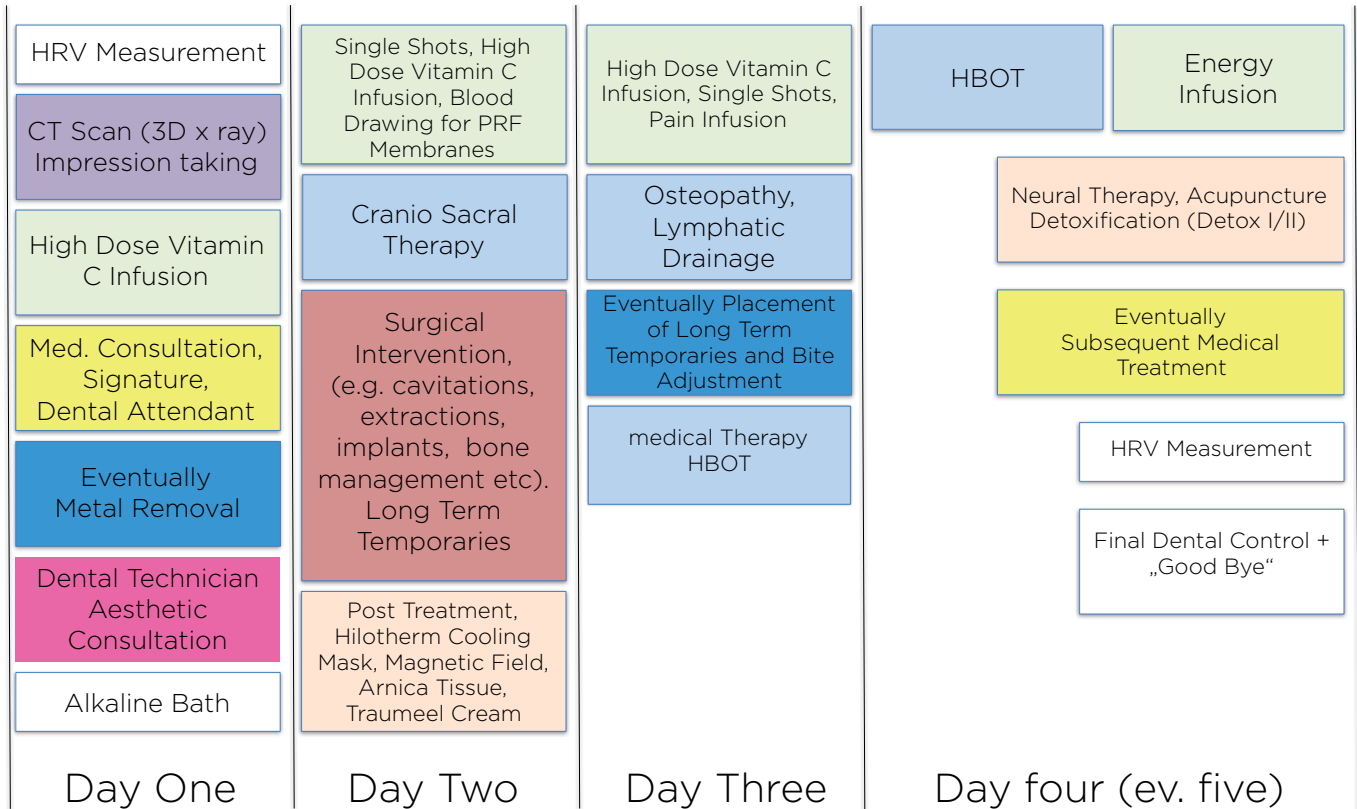
A logical development of Dr. Volz's 28 years of experience was the establishment of the SWISS BIOHEALTH CLINIC in 2016 and the ALL IN ONE CONCEPT that was introduced there. Now, all of a patient's dental problems can be eliminated in just a single session or series of sessions. This is key because the immune system can only function in an optimum manner once all potential problematic factors like metals, osteonecrosis, root-treated teeth and other fields of interference have been completely removed, thus eliminating systemic stress. It is all the more important because ceramic implants are completely neutral and will only be assimilated into healthy bones by a functioning immune system. Titanium implants release inflammatory mediators such as $TNF-\alpha$ and $IL-1\beta$, are assimilated by way of chronic inflammation, and can therefore heal into qualitatively compromised bone^(17, 18). However, according to the 2008 consensus conference, about 80% of these implants are affected by gingivitis and 28%–56% by bone inflammation.

Peri-implantitis does not occur with zirconia ceramic implants, which justifies the greater effort and expenditure

required prior to implant placement. Our highly consistent ALL IN ONE CONCEPT delivers success rates of around 98% at the SWISS BIOHEALTH CLINIC, a positive side-effect being that patients complete the entire treatment in one session or series of sessions. This concept makes it possible to lay the foundation for a major improvement in health as quickly as possible, enabling patients to leave the clinic with fixed and esthetic temporary restorations.

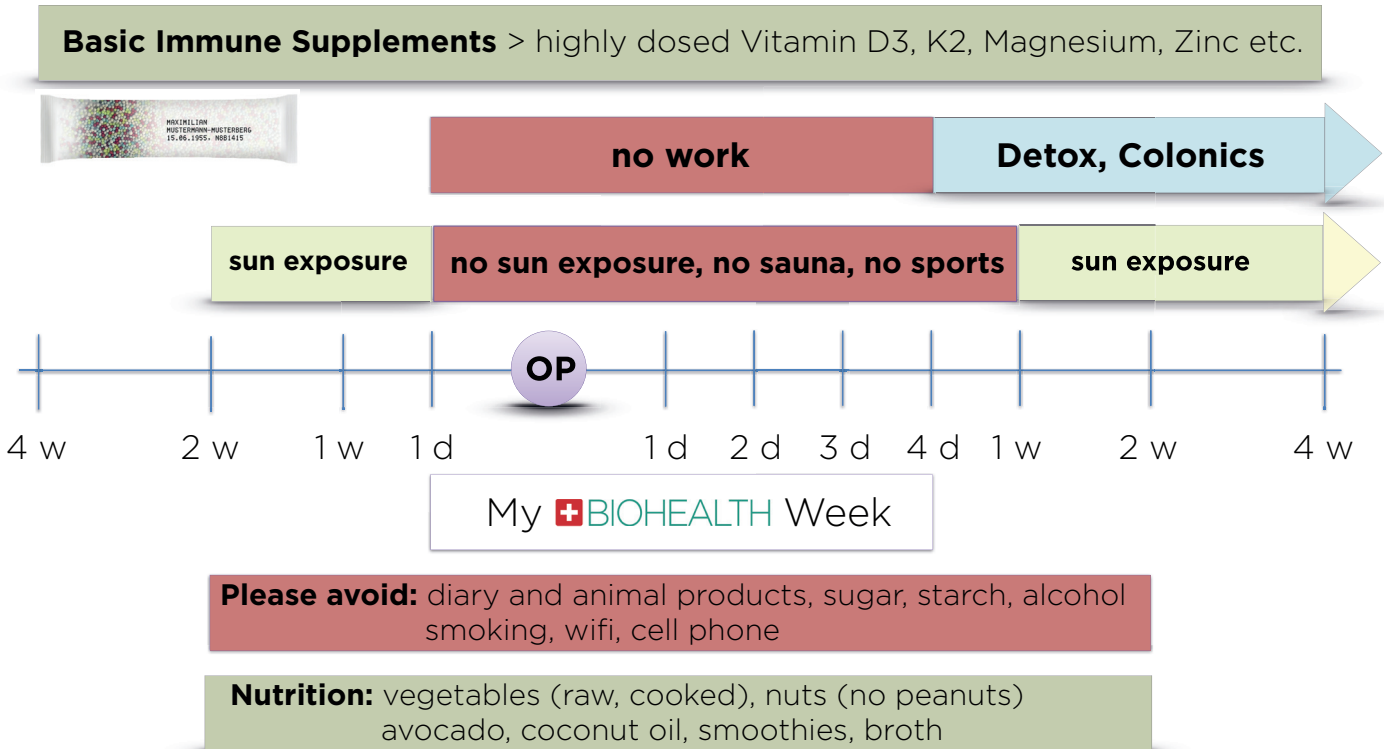
Figure 3 illustrates the typical scheme of treatment in accordance with THE SWISS BIOHEALTH CONCEPT, explains how patients have to prepare for surgery and lists what they need to do in the weeks before and after surgery. The scheme is based on the BIOLOGICAL TREATMENT PROTOCOL (BTP) and was developed by internationally recognized specialists in biological medicine and dentistry.

In very simple terms, the objectives of THE SWISS BIOHEALTH CONCEPT can be defined as partnering with immunology; working in a radical but stress-free (atraumatic) way from an early stage, in a preventive and minimally invasive manner which avoids swelling and pain; reaching the goal in as few sessions as possible to minimize the time the patient is out of action; using as few foreign materials as possible and - if any are required - keeping them as biologically compatible as possible, AND keeping the patient in a parasympathetic state throughout the therapy to the greatest extent possible.



My  BIOHEALTH Week

Figure 3: The My Biohealth Week scheme



Case history, findings, examinations

It goes without saying that all conventional aspects of dental examination and diagnosis must be carried out. These include case history, findings, x-rays, a functional examination, modeling, etc.

DVT

Furthermore, a three-dimensional x-ray image (digital volume tomography, DVT) is essential to identify inflammation, ischemic osteonecrosis (FDOJ = fatty degenerative osteolysis of the jawbone, formerly known as "NICO"), foreign bodies and dispersed metals.

LDL and Vitamin D3 (25-OH) analysis

A high LDL value (low-density lipoprotein = "bad cholesterol") of over 1.2 g/L indicates a high propensity to inflammation. A low D3 value of below 70 ng/ml reduces the chance of forming healthy bones and correlates with a weak immune system.

Additional lab tests

Further tests can also be conducted, but these reach far into the medical field and should be carried out in cooperation with a doctor/naturopath, if necessary. They include tests for micronutrients, IgG4- food intolerances, porphyrins, nitrostress, HPU/KPU analysis, genetic tests, stool analysis, etc.

Titanium intolerance test

If the patient has titanium implants, both a Melisa test (www.melisa.org) and a titanium stimulation test (www.imd-berlin.de) should always be carried out, as titanium is the only material that is not removed from the patient categorically and automatically. However, in view of the imminent migration to the new 5G mobile phone network, we now recommend prophylactic removal of titanium, since even in the 3G/4G field, the temperature of the bone around a titanium implant rises by up to 4°C when the wearer uses a mobile phone! A study by Kavyashree et al. also showed that excessive mobile phone use can impair bone maturation around implants and delay osseointegration⁽²⁴⁾.

Meridian analysis

Once sources of inflammation and foci have been identified on a 3D image, they are "matched", i.e. associated with the patient's general symptoms with the help of the meridian system. We always - and in all patients - find an accumulation of general medical symptoms on the meridians which run through nidi, interference fields or areas of inflammation.

Neural therapy simulation

The correlations identified can now be simulated, so that they become tangible and comprehensible for the patient. The injection of procaine around the suspected tooth is an instrument perfectly suited to convince the patient of the necessity of rehabilitation and to determine in advance whether the biological-dental therapy will result in a general physical improvement. As a rough guide, the actual improvement will be about twice as strong as the improvement that can be achieved through simulation.

Immunological pre- and post- treatment

Given the standard that modern medicine has reached in the 21st century, it seems anachronistic to automatically prescribe oral antibiotics after dental surgery, to prescribe a chlorhexidine mouthwash and to tolerate massive swelling over many days. This approach stems from a mechanistic approach, according to which bacteria must be fought and killed without any consideration of side effects. Oral antibiotics (anti bios = against life) lead in various ways to lysis (dissolution) of the bacteria's cell membrane, with the result that enormous amounts of endotoxins (i.e. the intestinal contents of the bacteria, so to speak) are released into the body, which can lead to side effects as severe as septic shock⁽²⁵⁾.

Furthermore, patients feel weakened when taking oral antibiotics and often suffer from diarrhea and vomiting as their valuable intestinal bacteria get destroyed. They may also suffer fungal infections of the intestines or genitals as the bacteria which normally keep fungi in check are eliminated. We have also observed an increase in levels of fungi in the oral cavity after the use of chlorhexidine. Furthermore, the ill-considered and routine use of oral antibiotics promotes the development of resistance and reduces their life-saving value in the event of truly serious diseases⁽²⁶⁾.

This is why biological dentistry focuses on strengthening the immune system, local sterilization and activation of bone healing with natural or intravenously administered substances in order to avoid the aforementioned problems. When administered intravenously, antibiotics do not have the same side effects.

We must also be aware that although our bodies are naturally designed to thrive, they sometimes no longer function properly because we have strayed too far from nature. In evolutionary terms, we were intended to live unclothed in the equatorial region of our planet, thus receiving a sufficient supply of vitamin D3 from the sun, leading a physically active life, roaming in the wild and feeding on fresh natural products which would provide us with sufficient amounts of all the vitamins (especially vitamin C), minerals and other micronutrients we need. When it comes to vitamins, the following are of particular importance.

Vitamin D3

Strictly speaking, vitamin D3 is a hormone, not a vitamin, and is essential for unimpeded bone healing, since it inhibits osteoclasts and activates osteoblasts⁽²⁷⁻²⁹⁾. The intake of 20,000 I.U./day over four weeks prior to surgery regularly results in levels of 70-120 ng/ml of 25-hydroxy-vitamin D3 (calcidiol) in the blood. We believe that this dose optimally prepares patients for surgery.

Vitamin D3 levels in the population differ according to latitude. Levels are highest in people living near the equator (40ng/ml) and lower in those living further north and south of the equator⁽³⁰⁾. Unfortunately, 60% of the German population has levels under the lower limit of 30ng/ml⁽³¹⁾, which means that they are in a state of “immunological hibernation” and are not capable of healing bones and wounds completely and without complications. It is important to combine vitamin D3 with vitamin K2/mk7 when taking it over long periods, as vitamin D3 requires vitamin K2 in order to prevent potential hypercalcemia in the blood⁽³²⁾. A K2 deficiency can lead to cardiovascular disease, among other things⁽³³⁾. The combination of D3 and K2/mk7 also helps to prevent hypercalcemia associated with D3 over-dosage⁽³²⁾. The ratio of vitamin D3 to K2/mk7 should be 10,000 I.U. D3 to 100µg K2/mk7.

The phenomenon of vitamin D3 receptor blockage has been the subject of growing debate in recent years and is

associated with an activation of retroviruses embedded in the DNA by environmental and dental toxins. This explains why, surprisingly, significantly lower amounts of D3 are sufficient to maintain a value of 70 ng/ml after a successful restoration in accordance with the ALL-IN-ONE concept has been carried out. In the event of a receptor blockage, the system must be flooded with high doses of vitamin D3 prior to restoration in order to achieve the required value of > 70 ng/ml. This can be achieved in virtually all cases through supplementation with the BASIC IMMUNE formulation. In rare cases it may be necessary to increase D3 to daily doses of up to 100,000 I.U.

The importance of this vitamin and its many positive effects are explained in detail in the chapter “The importance of vitamin d”.

Vitamin K2/mk7 (menaquinone)

As far back as 1945, Dr. Weston Price discovered a “vitamin-like activator” which, according to his research, plays a central role in the storage of minerals, child growth and development, tooth positioning and physique, reproduction, aging, caries, heart disease and brain function. He named this factor “activator X”. It was not until 2008 that Christopher Masterjohn combined the studies of Weston Price with those of the United States Department of Agriculture and Tufts University. Masterjohn was able to demonstrate that activator X is identical to vitamin K2. This vitamin is of bacterial origin and is found almost exclusively in animal and fermented foods. Nattō, a popular Japanese food made from fermented soybeans, is particularly rich in K2.

It is not possible to overdose on vitamin K2/mk7, although patients taking anticoagulants should limit their intake⁽³⁴⁾. K2/mk7 activates substances known as matrix GLA proteins by inducing carboxylation⁽³⁵⁾. During this process, GLA proteins transport minerals such as calcium into our tissues (vessels, connective tissue and bones). Osteocalcin is probably the most important GLA protein. It is only effective in its carboxylated form (activated osteocalcin) and should be present in sufficient quantities. Its synthesis is triggered by calcitriol (active vitamin D3). In general, vitamin K2/mk7 is responsible for transporting the minerals absorbed by D3 in the intestine and reabsorbed in the renal end tubules from the blood to the bones. Thus, K2/mk7 inhibits vascular calcification, as the osteocalcin dissolves

the minerals from the vessel walls and returns them to the bone. It prevents the widespread disease of arteriosclerosis and protects against cardiovascular disorders⁽³⁶⁻³⁸⁾. K2/mk7 can also have positive effects on bone metabolism. It optimizes bone density and can prevent osteoporosis^(39, 40). Furthermore, K2/mk7 can protect against caries⁽⁴¹⁾. There is also evidence that this vitamin improves brain function by influencing sphingolipid synthesis⁽⁴²⁾, has an anti-tumor effect⁽⁴³⁾, prevents type II diabetes⁽⁴⁴⁾ and can increase fertility in men⁽⁴⁵⁾. Thus, modern research has been able to largely confirm Weston Price's findings.

The BASIC IMMUNE PROTOCOL

The BASIC IMMUNE PROTOCOL according to Dr. Klinghardt and Dr. Volz prescribes the following standard pre-surgery supplementation with minerals and vitamins: One sachet of the energy-promoting ingredients (Energy) in the morning. One sachet of the relaxing and calming ingredients (Relax) in the evening

Patients are required to start taking the BASIC IMMUNE mixture four weeks prior to surgery and to continue taking it for another four weeks afterwards, thereby enabling the body's stores to be filled to the maximum without any risk of overdosing due to the relatively short treatment period of two months. The simple dosage form with one sachet in the morning and one in the evening makes it quick and easy to take the supplement correctly, and the sachets are convenient for people who travel a lot.

Patients generally start to notice an increase in performance after just two to three days. They have more energy and their bodies are better able to regenerate thanks to deep, restful sleep. Having recognized these benefits, several members of the German Olympic national sailing team have been taking BASIC IMMUNE since 2018. According to the Cologne List, BASIC IMMUNE is clear of doping risk.

The enhanced effectiveness of the BASIC IMMUNE supplements is achieved through microencapsulation of the ingredients using small cellulose sponges as carriers. Cellulose is itself a dietary fiber or prebiotic which is metabolized by the gut bacteria. This produces energy in the form of ATP on the one hand and promotes the growth of vital intestinal bacteria on the other. The nutrients are loaded onto these cellulose sponges and then coated with cellulose in a patented process to produce finished pellets with layers of dif-

ferent thicknesses. Mutually supportive nutrients are loaded onto a single pellet and separated from nutrients known to counteract one another. The varying thickness of the coating allows different nutrients to be absorbed in different sections of the large and small intestine, thereby boosting their effectiveness. As the nutrients are released from the cellulose sponges very slowly over some 12 hours, a slow-release effect is achieved, further boosting the effect of the doses in the BASIC IMMUNE mixture. Patients whose intestinal flora is not yet optimally developed may find apparently undigested BASIC IMMUNE pellets in their stool. These are merely empty sponges which could not be completely digested due to the lack of gut bacteria. The nutrients have nevertheless been absorbed. Thanks to the oversupply of cellulose, gut bacteria will start developing and the intestine's ability to digest the cellulose will improve over time. This process can be accelerated via intestinal cleansing or taking the BioPro Supreme protein shake, which contains large amounts of live gut bacteria.

Periodontitis: Chicken or egg?

Our consistent application of the protocol described above in the SWISS BIOHEALTH CLINIC has enabled us to observe that not only do the implants of almost all patients who follow this protocol and take the BASIC IMMUNE mixture heal without complication, but preexisting manifestations of gum inflammation have completely disappeared by the time patients arrive at our clinic for surgery. This clearly disproves the official thesis that gum inflammation (periodontitis) is due to poor dental hygiene and shows that these patients are being unjustifiably stigmatized. We postulate that periodontitis is the "scurvy of the 21st century" and is caused by micronutrient deficiency (especially vitamin D and vitamin C), which leads to gum inflammation⁽⁴⁶⁻⁵¹⁾. This is accompanied by pain and sensitivity, causing patients to stop brushing adequately. Plaque buildup is therefore the consequence rather than the cause of periodontitis and not the other way around!

Vitamin C

Vitamin C is just as important in wound healing and infection protection as vitamin D₃⁽⁵²⁻⁵⁵⁾. Humans have been described as "defective mutants" with respect to vitamin C because they lack the enzyme which would enable them to synthesize vitamin C from glucose in the small intestine and must instead absorb it through their diet. The recom-

mended daily intake for adults in Germany is officially 95–110 mg per day⁽⁵⁶⁾ - a level that can just about prevent scurvy!

Two-time Nobel Prize winner Prof. Linus Pauling recommended intravenous vitamin C infusions of 10 to 20 g. He justified this by arguing that almost all mammals, with the exception of humans, apes and guinea pigs, can metabolize ascorbate from glucose, with an average daily production of 10000 mg based on a human body weight of 70 kg⁽⁵⁷⁾. Goats can produce 200 mg of vitamin C per kilogram of body weight daily⁽⁵⁸⁾. In stressful situations, animals even produce significantly higher amounts of vitamin C. In situations of acute stress, rats can produce up to 10 g of vitamin C in a fraction of a second. In a study involving cancer patients who had run out of treatment options, Pauling and his colleague Cameron demonstrated that with the administration of 10 g of vitamin C per day, the average survival time for the ascorbate group was more than 4.2 times longer than for the control group⁽⁵⁹⁾. Daily doses of up to 15 g vitamin C do not generate any side effects but must be given intravenously since oral intake is limited to about 500–1000 mg per day. For a single administration before, during and after a jaw operation, 15 g of vitamin C per day is recommended to reach a total dose of 45 g of vitamin C perioperatively. Only via the Esther-C form can a bigger daily dose of 2–10 g be taken orally (SWISS BIOHEALTH VITAL Ester-C supz inside).

Vitamin C is not only the ultimate radical scavenger (antioxidant) and thus reduces tissue stress but, like vitamin D3, it also has an osteoblast-activating and osteoclast-inhibiting effect, thereby supporting bone formation and inhibiting bone resorption^(60–64). In addition, it has detoxifying and anti-inflammatory (anti-infectious) properties and promotes the formation of collagen and connective tissue^(65, 66). Symptoms of deficiency are typically scurvy and periodontitis, as well as wound-healing disorders and susceptibility to infection^(46, 52, 53, 64, 67, 68). Unfortunately, contrary to popular belief, orange juice contains only very small amounts of vitamin C (52 mg per 100 ml). By way of comparison, the acerola cherry contains up to 1,700 mg per 100 g⁽⁶⁹⁾!

| BASIC IMMUNE - ENERGY (morning) Suggested recommended daily intake: | | BASIC IMMUNE - RELAX (evening) Suggested recommended daily intake: | |
|--|-----------|---|----------|
| Micronutrient | per day | Micronutrient | per day |
| Vitamin C (ascorbic acid) | 2.000 mg | L-Arginine | 2.500 mg |
| L-Arginine | 1.500 mg | L-Lysin | 2.000 mg |
| Vitamin E (tocotrienol) | 200 mg | Alpha Lipoic Acid | 600 mg |
| Coenzyme Q10 | 100 mg | Magnesium (magnesium citrate) | 474 mg |
| Vitamin B2 (riboflavin) | 50 mg | Zinc (zinc citrate) | 56 mg |
| Folic Acid (methylfolate) | 2.500 µg | Vitamin B6 (pyridoxal 5-phosphate) | 30 mg |
| Vitamin A (retinol) | 2.400 µg | Manganese (manganese sulfate) | 6 mg |
| Vitamin B12 (methylcobalamin) | 2.000 µg | | |
| Selenium (selenomethionine) | 600 µg | | |
| Vitamin D3 (cholecalciferol) | 500 µg | | |
| Vitamin K2 (menaquinone-7) | 200 µg | | |
| Bromelain | 1100 GDU* | | |

* G.D.U. = Gelatin Digesting Unit

Figure 4: Basic Immune ingredients

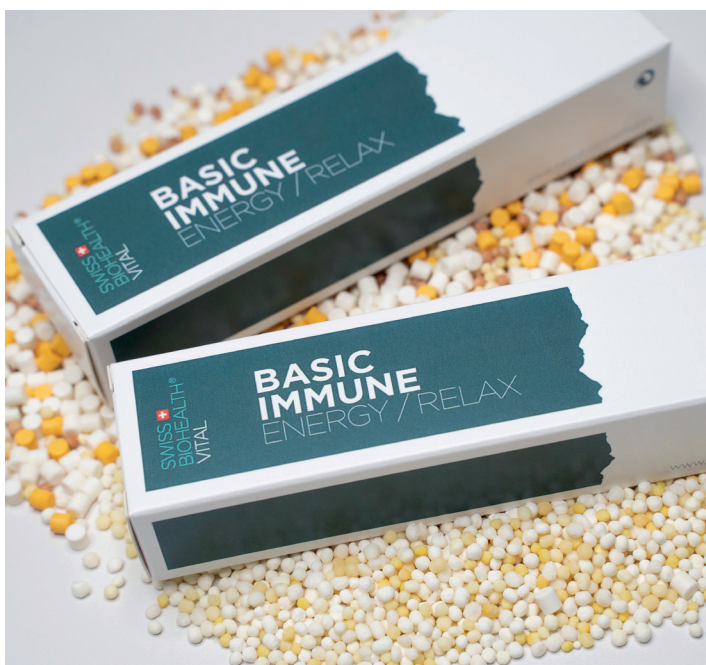

Figure 5: Basic Immune



Figure 6: Testimonial of the German Olympic Sailing Team:

„We tried out Basic Immune during and after the competition and could immediately identify constant and long-lasting energy, attention and just a general feeling of well-being, even after 6 days of hard work. Usually, right after the competition the body needs some time to rest where all the systems shut down, but with Basic Immune this process could be reconciled. Furthermore, is Basic Immune incredible easy to transport and to take in! In my opinion, is this one of the great strengths of Basic Immune, as usually it needs a lot of discipline to force oneself to take in all the different supplements. I myself believe that a pre and after - work product on the same basis for sports could be a great opportunity for the future.“

Jan Jasper Wagner and Julian Autenrieth

Single Shots

To manage the inflammatory response related to surgery, single shots of dexamethasone (8 mg) and Sobelin 600 mg or Augmentin 625 mg, each dissolved in 50-100ml NaCl, should be given intravenously prior to surgery. This prevents the “bad inflammation” caused by giant cells, which is associated with tissue destruction. “Good inflammation” based on macrophages, leucocytes, lymphocytes and monocytes, which leads to the formation of new and healthy tissue, will not be affected. It is important to ensure that all intravenous administrations are carried out prior to surgery so that the PRF and blood coagulum, which is stored in cavities (extraction sockets, FDOJ cavities or maxillary sinuses) but has no contact with the bloodstream until vascularization, is already “loaded” with the valuable substances. The administration of cortisol (dexamethasone) has become increasingly important in recent years, since more than 50% of people living in Western industrialized nations now suffer from adrenal fatigue, which means that they can no longer produce sufficient amounts of the body’s own cortisol and are particularly at risk of wound-healing disorders and other complications⁽⁷⁰⁾. This adrenal weakness is triggered by years of stress-related overproduction of cortisol⁽⁷¹⁾, which eventually leads to a loss of the ability to produce cortisol at all (the tank is empty). This also alters the production of other hormones in the adrenal cortex with serious consequences for the health and performance of the affected individuals. We suspect that some 95% of our patients now suffer from this weakness. You can request the Adrenal Fatigue Questionnaire in the SWISS BIOHEALTH CLINIC to determine your risk easily and free of charge.

BTP Infusion

During the entire surgical procedure, the patient receives our BTPII infusion, which contains 15 g of vitamin C plus procaine, magnesium sulfate, sodium bicarbonate and vitamin B12. It is important not to use isotonic saline solution as a basis, as it retains water in the kidneys, but to use isotonic Ringer’s solution instead. Towards the end of the procedure, the BTPII infusion is replaced by an analgesic infusion. The patient should not feel severe pain at any stage, as this would activate the sympathetic nervous system and undermine the immune and healing mechanisms ⁽⁷²⁾. For minor procedures, 15 minutes of Perfalgam® (1 g paracetamol) is sufficient. For lengthy major procedures, Novalgin® 2.5 g should be infused for approximately 20 minutes.

DAILY USE

DAILY USE is a mixture based on BASIC IMMUNE, which also consists of a morning and an evening sachet and is designed for long-term use. Since a sufficient supply of micronutrients is no longer available from our food due to the leaching of our soils, and because our stressful lives increase our nutrient requirements, people in industrialized Western countries need to supplement daily and routinely with the most important substances such as minerals and vitamins. It is important to understand, however, that DAILY USE is only a maintenance dose and that the body's stores must first be filled up using BASIC IMMUNE. Nobody will deny that our stress levels have increased significantly in recent years due to adverse factors such as environmental pollution, electromog, consequences of nuclear accidents, digital overload and the pressure of being constantly online.

Unfortunately, increasing stress not only requires more nutrients but often depletes their levels even further in our system, as is illustrated below through the example of vitamin D3. One of vitamin D3's key functions is to promote the absorption of minerals in the intestine and their reabsorption through the renal end tubules. To ensure this takes place on an ongoing basis, the level of the D3 hormone calcitriol in our cells is regulated via a cybernetic feedback loop, independent of actual D3 formation with the help of the sun or D3 intake from food. If blood calcium levels increase, calcitriol is decreased, thereby reducing calcium absorption. The parathyroid hormone is also lowered in order to mobilize less calcium from the bones. This is a very useful control circuit which counteracts hypercalcemia, i.e. excessive calcium in the blood, which carries a risk of arteriosclerosis. If this feedback loop functions properly, the exact amount of calcitriol will always be produced to balance out the calcium level in the blood⁽⁷³⁾.

A vitamin D3 deficiency due to insufficient formation with the help of sunlight (something that was never intended by nature, as mankind originated in Africa)⁽⁷⁴⁾ and insufficient intake through food generates additional stress, compounding the many other stress factors. As a result, the body falls into the acidic pH range. However, since the blood pH value must always be regulated at just under 7.4 in order to maintain vital functions, calcium is increasingly absorbed or mobilized from the bones via the parathyroid hormone to buffer and neutralize the blood. This overrides the feedback loop described above.

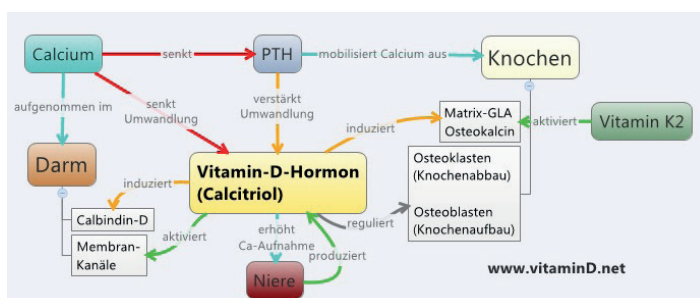


Figure 7: Feedback loop for adequate blood calcium levels⁽⁷⁵⁾

Although the blood pH level is normalized, the increased calcium level leads to a further dangerous drop in calcitriol - a vicious circle! Consequently, high-dose D3 therapy invariably not only increases performance but also reduces susceptibility to stress and improves mood. There is hardly a more effective anti-depressant than vitamin D3 in daily doses of at least 20,000 I.U.⁽⁷⁶⁻⁸⁰⁾

Intestinal rehabilitation and amino acids

Rehabilitation of intestinal flora and amino acid supply can be achieved with the help of two important products manufactured especially for SWISS BIOHEALTH VITAL (supz inside). A team of experts working under Dr. Dominik Nischwitz ensures not only the maximum effectiveness and safety but also the best bioavailability of the selected raw materials and capsule shells, which for example do not contain titanium oxide.

BioPro Supreme is a vegan protein powder based on brown rice. One daily dose contains the complete amino acid profile equivalent of a 300 g steak. It contains six selected probiotic cultures in a concentration of 2 billion bacteria per serving which help cleanse and build up the intestinal flora. Psyllium husks, fructo-oligosaccharides and Sunfiber are added as prebiotics. As a further special feature, this protein-probiotic complex contains an extra portion of the amino acid glutamine in each daily dose.

A regular intake, especially after surgical interventions, but also by patients who practice intensive sports, provides sufficient vegan amino acids (the most important building material of our bodies) and improves the intestinal flora. This strengthens the gut-related part of our immune sys-

tem, which makes up around 80% of our overall immune system. The powder is made up in the SWISS BIOHEALTH SHAKER with purified water or unsweetened almond or coconut milk.

Amino Supreme Performance is a sugar-free red amino drink with exclusively vegan amino acids and no artificial colors or flavors. Developed in close cooperation with doctors and athletes according to the latest scientific findings, it consists of a special amino-acid matrix. It contains BCAAs (branched-chain amino acids) and all the EAAs (essential amino acids), as well as taurine, glutamine, creatine, beta-alanine, tyrosine and ornithine aspartate. Additionally, it contains the mineral magnesium in the form of magnesium malate. Particularly after surgery, the body has an increased need for amino acids, as these are required to build cells and enzymes. An enhanced supply of amino acids also accelerates detoxification. In phase II detoxification in the liver, an amino acid is added to toxins such as heavy metals in order to flush them out of the system. Amino acids are also needed for neurotransmitter formation, and thus for better functioning of the brain and the endocrine system⁽⁸¹⁾, improved performance and better mood in general.

Detoxification

A highly effective detoxification procedure is key in ensuring lasting treatment success and delivering the greatest health improvements for the patient, especially after the removal of amalgam or other metals or after surgical interventions in general.

It is important to distinguish between non-specific general detoxification therapies and specific therapies that can only be carried out after a medical examination and diagnosis and under medical supervision. These include the specific prescription of drugs, minerals and vitamins, usually after a blood test, a mercury/heavy metal mobilization test and an ART (Autonomous Response Test) according to Dr. Klinghardt. Likewise, mercury drainage using intravenous DMPS (di-mercapto-propane-sulfonic acid) may only be carried out under medical supervision. Neural therapies with a mixture of DMPS and procaine in ganglia and other areas must be carried out in a targeted manner.

Individual patients can and must follow general detoxification therapies after treatment. These include drinking plenty of pure and purified water - at least two to three

liters per day. Also advised is sweating from the fourth postoperative day onwards via regular sauna sessions, preferably using an infrared sauna. Ion foot baths according to Dr. Klinghardt as well as intestinal cleansing (colon hydrotherapy), ideally in combination with special intestinal massages, are also very beneficial in promoting detoxification. It is also very important to maintain a healthy diet, avoiding a renewed intake of harmful substances, and to eat vegetables (raw or cooked), nuts (but not peanuts because of the aflatoxin they contain), avocados, coconut oil, smoothies and broths. Dairy products and other animal proteins need to be avoided for several weeks, as well as sugar, starch, alcohol and smoking. The influence of EMF on detoxification efficiency has also been vastly underestimated in the past, as Dr. Volz showed in a DETOX EXPERIMENT in 2010. He brought together 20 patients, some of them severely ill (with conditions including ALS, cancer, Alzheimer's, Parkinson's and MS), and 20 well-known biological doctors including Dr. Dietrich Klinghardt, Dr. Christfried Preußler, Dr. Joachim Mutter, Dr. Christof Plothe, HPU specialist Dr. Tina Ritter, Prof. John Ionescu and others in a completely EMF-radiation-free area in Brazil.

The absence of EMF alone vastly improved both the efficiency of the detoxification therapy and the patients' symptoms immediately. Thus, a "digital sabbatical" of at least 5 days postoperatively is an absolute must to avoid hampering the detoxification and healing process. Since detoxification takes place during sleep, primarily at night, due to liver activity and the shrinking of brain cells^(7,82), it is of particular importance to protect the bedroom by switching off all EMF sources (smartphones, Wi-Fi, etc.), using protective plugs such as VivoBase, or placing radiation protection canopies over the bed.

Deep, restful sleep is a prerequisite for good regeneration and detoxification, because it is during the deep sleep phase that cells repair and molt, the energy supply is replenished, the immune system is activated and human growth hormones (HGH) and new muscles develop. The bite height is an extremely important factor when it comes to detoxification of the central nervous system via the lymphatic system and the drainage of toxins through the large neck veins (jugular vein) at night⁽⁷⁾. A reduced bite height leads to a constriction of neck veins and impaired drainage of the lymph.

The sleep hormone melatonin is a key factor in good sleep. As soon as dusk sets in, molecules formed in the eye send out signals to the diencephalon, prompting it to produce melatonin from the feel-good hormone serotonin. Melatonin is mainly produced by the pineal gland and is only released into the bloodstream at night as part of our circadian rhythm⁽⁸³⁾.

Cortisol and insulin have a particularly negative effect on deep sleep because they antagonize melatonin production^(84, 85), a prerequisite for the deep sleep phase. Thus, stress severely impairs nocturnal sleep as it releases cortisol⁽⁸⁶⁾. Any screen activities after 5 p.m., especially those involving blue light, should be avoided, as this type of light stimulates cortisol production and largely destroys the sleep-promoting melatonin^(87, 88).

Sports activities which increase body temperature shortly before bedtime are not recommended. The same goes for late suppers with heavy consumption of short-chain carbohydrates, coffee, green tea or chocolate, as these increase the release of cortisol, adrenaline and insulin and interfere with sleep. A healthy intestine is important for sleep because the microbiome produces neurotransmitters such as dopamine, serotonin and GABA⁽⁸⁹⁾, which can improve deep sleep. A healthy and balanced diet is very important for promoting a healthy and diversified intestinal flora (intake of pre- and probiotics). Micronutrients that favor good sleep include vitamin D3⁽⁹⁰⁾, Omega-3 fatty acids⁽⁹¹⁾, vitamins E, B3, B6 and magnesium⁽⁹²⁾. The consumption of nuts (with the exception of peanuts) is particularly recommended because they contain tryptophan, the precursor of serotonin. Furthermore valerian, lavender, passiflora, ginkgo biloba, St. John's wort and ashwagandha (*Withania somnifera*) have a calming effect on our organism and promote deep sleep. Also worth mentioning is Swiss stone pine wood, as its essential oil can have a calming and sleep-promoting effect.

In addition to the widely-known detoxifying agents MSM and zeolite, chlorella is an important detoxifying tool. The recommended dose is 20 tablets three times per day.

Bite elevation constitutes another important and highly effective detoxification measure. The correct bite height can be optimally tested before a surgical procedure by means of ART according to Dr. Klinghardt. This test makes it possible to identify the bite height that not only opens

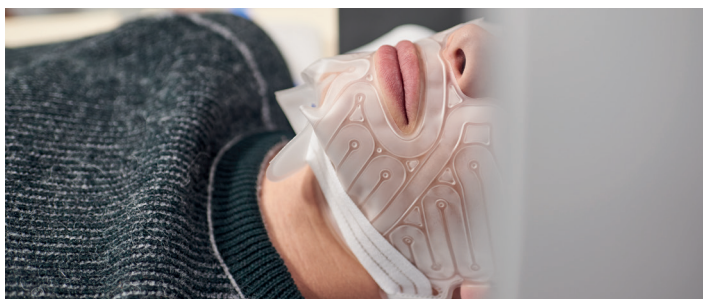

Figure 8: Hilotherm cooling mask

the jugular vein as described above and thus boosts detoxification, but also puts the patient in a deep YIN state, i.e. in the parasympathetic mode. The correct bite height will already be built into the long-term temporary in the event of a complete restoration, or alternatively achieved by wearing a detox splint on the lower jaw at night. In addition to opening the lateral jugular vein, the bite correction also improves the blood supply to the brain⁽²⁾.

Additional measures

Further measures include hilotherapy by means of a device which the patient should apply continuously over a period of 72 hours postoperatively. If used consistently, this device can prevent postoperative pain and swelling. The success of this technique is based on the following principle. After surgery, the oxygen and nutrient supply is considerably impaired, raising the metabolic rate with subsequent overheating of the tissue due to inflammation. This in turn increases the overall oxygen requirement, and the amount of oxygen available is no longer sufficient for regeneration, resulting in reduced blood circulation (ischemia) and lack of oxygen supply. The consequence is cell death and formation of edema - a vicious circle. The damaged tissue's oxygen demand therefore needs to be reduced. This can be achieved by cooling the tissue using the Hilotherm cooling mask.

A cooling of the tissue by 10°C will reduce the metabolic rate by 50%, a cooling by 20°C (from 37°C down to 17°C) reduces it by 75%. As a result, the available oxygen will be more than sufficient. However, the temperature must not fall below 15°C, as this would cause lymph congestion, preventing the removal of toxins⁽⁹³⁾.

Another important measure is the reduction of elevated LDL levels (“bad cholesterol”). Within the general population, LDL increases are mainly due to our bodies reacting to increasing levels of electrosmog. LDL has a counterproductive effect because it increases the risk of inflammation and impairs bone healing⁽²⁰⁾.

We recommend the following protocol agreed with Dr. Klinghardt, in order to reduce LDL levels:

- Chlorella (20 pellets three times a day)
- Niacin (500 mg one to three times per day)
- Acetyl-L-Carnitine (1,500 mg morning and evening)
- BASIC IMMUNE supplements over a period of a least three months

Homeopathic medicines can be administered in the following situations:

- Apis C30 in the event of an allergy or anaphylactic shock, in addition to the prescribed general medical measures
- Belladonna C30 to relieve swelling
- Arnica C200 in all cases before and after every surgical intervention
- Bellis Perennis D6 and C30 to reduce hematomas
- Hypericum C30 in the event of nerve injuries and paraesthesia

Before being discharged from the clinic, patients should be given the following prophylactics to take away with them. These should however only be taken in the event of complications and only after prior consultation with the dentist:

- Augmentin: 625 mg for oral administration twice daily
- Prednisolone: 4 x 20 mg tablets for a tapered therapy according to the following daily dose pattern: 20-20-10-10-10-5-5

Complications occur - if at all - almost exclusively on weekends! This is not due to Murphy’s Law, but rather to the increased parasympathetic activation as people relax at weekends. The provision of prophylactics eliminates the need for the patient to obtain a prescription and then search for an emergency pharmacy, thus preventing unnecessary stress and wasted time all round.

References

1. Netter FH. The Ciba collection of medical illustrations: Volume 1 Nervous System Part I Anatomy and physiology. Summit, N.J.: Ciba Pharmaceutical Products; 1959-1993. 8 v. in 13.
2. Miyamoto I, Yoshida K, Tsuboi Y, Iizuka T. Rehabilitation with dental prosthesis can increase cerebral regional blood volume. *Clin Oral Implants Res*. 2005;16(6):723-7. doi:10.1111/j.1600-0501.2005.01171.x
3. Fang W-L, Jiang M-J, Gu B-B, Wei Y-M, Fan S-N, Liao W, Zheng Y-Q, Liao S-W, Xiong Y, Li Y, Xiao S-H, Liu J. Tooth loss as a risk factor for dementia: systematic review and meta-analysis of 21 observational studies. *BMC Psychiatry*. 2018;18(1):345. doi:10.1186/s12888-018-1927-0
4. Kato T, Usami T, Noda Y, Hasegawa M, Ueda M, Nabeshima T. The effect of the loss of molar teeth on spatial memory and acetylcholine release from the parietal cortex in aged rats. *Behavioural Brain Research*. 1997;83(1-2):239-42. doi:10.1016/s0166-4328(97)86078-0
5. Alvarenga MOP, Ferreira RdO, Magno MB, Fagundes NCF, Maia LC, Lima RR. Masticatory Dysfunction by Extensive Tooth Loss as a Risk Factor for Cognitive Deficit: A Systematic Review and Meta-Analysis. *Front Physiol*. 2019;10:832. doi:10.3389/fphys.2019.00832
6. Lexomboon D, Trulsson M, Wårdh I, Parker MG. Chewing ability and tooth loss: association with cognitive impairment in an elderly population study. *J Am Geriatr Soc*. 2012;60(10):1951-6. doi:10.1111/j.1532-5415.2012.04154.x
7. Xie L, Kang H, Xu Q, Chen MJ, Liao Y, Thiyagarajan M, O'Donnell J, Christensen DJ, Nicholson C, Iliff JJ, Takano T, Deane R, Nedergaard M. Sleep drives metabolite clearance from the adult brain. *Science*. 2013;342(6156):373-7. doi:10.1126/science.1241224
8. Plog BA, Nedergaard M. The Glymphatic System in Central Nervous System Health and Disease: Past, Present, and Future. *Annu Rev Pathol*. 2018;13:379-94. doi:10.1146/annurev-pathol-051217-111018
9. Cardoso EM, Reis C, Manzaneres-Céspedes MC. Chronic periodontitis, inflammatory cytokines, and interrelationship with other chronic diseases. *Postgrad Med*. 2018;130(1):98-104. doi:10.1080/00325481.2018.1396876
10. Louhelainen A-M, Aho J, Tuomisto S, Aittoniemi J, Vuento R, Karhunen PJ, Pessi T. Oral bacterial DNA findings in pericardial fluid. *J Oral Microbiol*. 2014;6:25835. doi:10.3402/jom.v6.25835
11. Macedo Paizan ML, Vilela-Martin JF. Is there an association between periodontitis and hypertension? *Curr Cardiol Rev*. 2014;10(4):355-61.
12. Ott SJ, El Mokhtari NE, Musfeldt M, Hellmig S, Freitag S, Rehman A, Kühbacher T, Nikolaus S, Namsolleck P, Blaut M, Hampe J, Sahly H, Reinecke A, Haake N, Günther R, Krüger D, Lins M, Herrmann G, Fölsch UR, Simon R, Schreiber S. Detection of diverse bacterial signatures in atherosclerotic lesions of patients with coronary heart disease. *Circulation*. 2006;113(7):929-37. doi:10.1161/CIRCULATION-AHA.105.579979
13. Pessi T, Karhunen V, Karjalainen PP, Ylitalo A, Airaksinen JK, Niemi M, Pietila M, Lounatmaa K, Haapaniemi T, Lehtimäki T, Laaksonen R, Karhunen PJ, Mikkelsen J. Bacterial signatures in thrombus aspirates of patients with myocardial infarction. *Circulation*. 2013;127(11):1219-28. e1-6. doi:10.1161/CIRCULATIONAHA.112.001254
14. Ichikawa Y, Akagawa Y, Nikai H, Tsuru H. Tissue compatibility and stability of a new zirconia ceramic in vivo. *J Prosthet Dent*. 1992;68(2):322-6. doi:10.1016/0022-3913(92)90338-b
15. Wikipedia. Infektion [Internet]. Available from: <https://de.wikipedia.org/wiki/Infektion>
16. Price WA. Dental infections and the degenerative diseases [Internet]. west_virginia_university, americana. 1923. Available from: <https://ia800307.us.archive.org/16/items/dentalin02pric/dentalin02pric.pdf>
17. Rader CP, Sterner T, Jakob F, Schütze N, Eulert J. Cytokine response of human macrophage-like cells after contact with polyethylene and pure titanium particles. *J Arthroplasty*. 1999;14(7):840-8. doi:10.1016/s0883-5403(99)90035-9
18. Pettersson M, Kelk P, Belibasakis GN, Bylund D, Molin Thorén M, Johansson A. Titanium ions form particles that activate and execute interleukin-1 β release from lipopolysaccharide-primed macrophages. *J Periodont Res*. 2017;52(1):21-32. doi:10.1111/jre.12364
19. Lindhe J, Meyle J. Peri-implant diseases: Consensus Report of the Sixth European Workshop on Periodontology. *J Clin Periodontol*. 2008;35(8 Suppl):282-5. doi:10.1111/j.1600-051X.2008.01283.x
20. Choukroun J, Khoury G, Khoury F, Russe P, Testori T, Komiyama Y, Sammartino G, Palacci P, Tunali M, Choukroun E. Two neglected biologic risk factors in bone grafting and implantology: high low-density lipoprotein cholesterol and low serum vitamin D. *J Oral Implantol*. 2014;40(1):110-4. doi:10.1563/AAID-JOI-D-13-00062
21. Bryce G, MacBeth N. Vitamin D deficiency as a suspected causative factor in the failure of an immediately placed dental implant: a case report. *J R Nav Med Serv*. 2014;100(3):328-32.
22. Cooper LF. Systemic effectors of alveolar bone mass and implications in dental therapy. *Periodontol* 2000. 2000;23:103-9.
23. Schulze-Späte U, Dietrich T, Wu C, Wang K, Hasturk H, Dibart S. Systemic vitamin D supplementation and local bone formation after maxillary sinus augmentation - a randomized, double-blind, placebo-controlled clinical investi-

- gation. *Clin Oral Implants Res.* 2016;27(6):701-6. doi:10.1111/clr.12641
- 24.** Kavyashree M, Harish PV, Mishra SK, Chowdhary R. Cell Phone Radiation Effect on Bone-to-Implant Osseointegration: A Preliminary Histologic Evaluation in Rabbits. *Int J Oral Maxillofac Implants.* 2019;34(3):643-50. doi:10.11607/jomi.7024
- 25.** Infektionsbiologie. Der septische Schock [Internet]. Available from: http://www.infektionsbiologie.ch/seiten/lernwege/lernweg%20infektionsbiologie%20bakterien/inf-bakterien_kap4_07.htm
- 26.** Huizen J. What are the side effects of antibiotics? [Internet]. Thu 2018. Available from: <https://www.medicalnewstoday.com/articles/322850.php>
- 27.** Nakamichi Y, Udagawa N, Horibe K, Mizoguchi T, Yamamoto Y, Nakamura T, Hosoya A, Kato S, Suda T, Takahashi N. VDR in Osteoblast-Lineage Cells Primarily Mediates Vitamin D Treatment-Induced Increase in Bone Mass by Suppressing Bone Resorption. *J Bone Miner Res.* 2017;32(6):1297-308. doi:10.1002/jbmr.3096
- 28.** van Driel M, Pols HAP, van Leeuwen JPTM. Osteoblast differentiation and control by vitamin D and vitamin D metabolites. *Curr Pharm Des.* 2004;10(21):2535-55. doi:10.2174/1381612043383818
- 29.** Goltzman D. Functions of vitamin D in bone. *Histochem Cell Biol.* 2018;149(4):305-12. doi:10.1007/s00418-018-1648-y
- 30.** Wacker M, Holick MF. Sunlight and Vitamin D: A global perspective for health. *Dermatoendocrinol.* 2013;5(1):51-108. doi:10.4161/derm.24494
- 31.** Focus. Vitamin D Grenzwerte des Vitamins [Internet]. Available from: https://www.focus.de/gesundheit/ernaehung/gesundessen/tid-17499/vitamin-d-grenzwerte-des-vitamins_aid_488149.html
- 32.** van Ballegooijen AJ, Pilz S, Tomaschitz A, Gröbler MR, Verheyen N. The Synergistic Interplay between Vitamins D and K for Bone and Cardiovascular Health: A Narrative Review. *Int J Endocrinol.* 2017;2017. doi:10.1155/2017/7454376
- 33.** van Ballegooijen AJ, Beulens JW. The Role of Vitamin K Status in Cardiovascular Health: Evidence from Observational and Clinical Studies. *Curr Nutr Rep.* 2017;6(3):197-205. doi:10.1007/s13668-017-0208-8
- 34.** VitaminExpress. Vitamin K2 - natürlicher Schutz für Knochen und Arterien [Internet]. 2019. Available from: <https://www.vitaminexpress.org/de/vitamin-k2#toc-vitamin-k2-uberdosierung>
- 35.** Geleijnse JM, Vermeer C, Grobbee DE, Schurgers LJ, Knapen MHJ, van der Meer IM, Hofman A, Witteman JCM. Dietary intake of menaquinone is associated with a reduced risk of coronary heart disease: the Rotterdam Study. *J Nutr.* 2004;134(11):3100-5. doi:10.1093/jn/134.11.3100
- 36.** Kurnatowska I, Grzelak P, Masajtis-Zagajewska A, Kaczmarska M, Stefańczyk L, Vermeer C, Maresz K, Nowicki M. Effect of vitamin K2 on progression of atherosclerosis and vascular calcification in nondialyzed patients with chronic kidney disease stages 3-5. *Pol Arch Med Wewn.* 2015;125(9):631-40.
- 37.** Schurgers LJ, Cranenburg ECM, Vermeer C. Matrix Gla-protein: the calcification inhibitor in need of vitamin K. *Thromb Haemost.* 2008;100(4):593-603.
- 38.** Gast GCM, Roos N de, Sluijs I, Bots M, Beulens J, Geleijnse J, Witteman JC, Grobbee D, Peeters PHM, van der Schouw Y. A high menaquinone intake reduces the incidence of coronary heart disease. *Nutrition, metabolism, and cardiovascular diseases: NMCD.* 2009;19504-10. doi:10.1016/j.numecd.2008.10.004
- 39.** Knapen MHJ, Drummen NE, Smit E, Vermeer C, Theuvsen E. Three-year low-dose menaquinone-7 supplementation helps decrease bone loss in healthy postmenopausal women. *Osteoporos Int.* 2013;24(9):2499-507. doi:10.1007/s00198-013-2325-6
- 40.** Iwamoto J, Takeda T, Sato Y. Effects of vitamin K2 on osteoporosis. *Curr Pharm Des.* 2004;10(21):2557-76. doi:10.2174/1381612043383782
- 41.** Southward K. A hypothetical role for vitamin K2 in the endocrine and exocrine aspects of dental caries. *Med Hypotheses.* 2015;84(3):276-80. doi:10.1016/j.mehy.2015.01.011
- 42.** Denisova NA, Booth SL. Vitamin K and sphingolipid metabolism: evidence to date. *Nutr Rev.* 2005;63(4):111-21. doi:10.1111/j.1753-4887.2005.tb00129.x
- 43.** Setoguchi S, Watase D, Matsunaga K, Yamakawa H, Goto S, Terada K, Ohe K, Enjoji M, Karube Y, Takata J. Antitumor Effects and Delivery Profiles of Menahydroquinone-4 Prodrugs with Ionic or Nonionic Promoiety to Hepatocellular Carcinoma Cells. *Molecules.* 2018;23(7). doi:10.3390/molecules23071738
- 44.** Li Y, Chen JP, Duan L, Li S. Effect of vitamin K2 on type 2 diabetes mellitus: A review. *Diabetes Res Clin Pract.* 2018;13639-51. doi:10.1016/j.diabres.2017.11.020
- 45.** Patti A, Gennari L, Merlotti D, Dotta F, Nuti R. Endocrine actions of osteocalcin. *Int J Endocrinol.* 2013;2013846480. doi:10.1155/2013/846480
- 46.** Tada A, Miura H. The Relationship between Vitamin C and Periodontal Diseases: A Systematic Review. *Int J Environ Res Public Health.* 2019;16(14). doi:10.3390/ijerph16142472
- 47.** Stein SH, Livada R, Tipton DA. Re-evaluating the role of vitamin D in the periodontium. *J Periodont Res.* 2014;49(5):545-53. doi:10.1111/jre.12149
- 48.** Stein SH, Tipton DA. Vitamin D and its impact on oral health--an update. *J Tenn Dent Assoc.* 2011;91(2):30-3; quiz

- 34-5.
- 49.** Uwitonze AM, Murererehe J, Ineza MC, Harelimana EI, Nsabimana U, Uwambaye P, Gatarayiha A, Haq A, Razzaque MS. Effects of vitamin D status on oral health. *J Steroid Biochem Mol Biol.* 2018;175190-4. doi:10.1016/j.jsbmb.2017.01.020
- 50.** Lee J-H, Shin M-S, Kim E-J, Ahn Y-B, Kim H-D. The association of dietary vitamin C intake with periodontitis among Korean adults: Results from KNHANES. *PLoS ONE.* 2017;12(5):e0177074. doi:10.1371/journal.pone.0177074
- 51.** Woelber JP, Bremer K, Vach K, König D, Hellwig E, Ratka-Krüger P, Al-Ahmad A, Tennert C. An oral health optimized diet can reduce gingival and periodontal inflammation in humans - a randomized controlled pilot study. *BMC Oral Health.* 2016;17(1):28. doi:10.1186/s12903-016-0257-1
- 52.** Carr AC, Maggini S. Vitamin C and Immune Function. *Nutrients.* 2017;9(11). doi:10.3390/nu9111211
- 53.** Li X, Tang L, Lin YF, Xie GF. Role of vitamin C in wound healing after dental implant surgery in patients treated with bone grafts and patients with chronic periodontitis. *Clin Implant Dent Relat Res.* 2018;20(5):793-8. doi:10.1111/cid.12647
- 54.** Gröber U. Mikronährstoffe: Metabolic Tuning - Prävention - Therapie ; mit 134 Tabellen. 3rd ed. Stuttgart: Wiss. Verl.-Ges; 2011, c 2011. 622 S. (Für die Kitteltasche).
- 55.** Wintergerst ES, Maggini S, Hornig DH. Immune-enhancing role of vitamin C and zinc and effect on clinical conditions. *Ann Nutr Metab.* 2006;50(2):85-94. doi:10.1159/000090495
- 56.** Deutsche Gesellschaft für Ernährung e.V. Vitamin C: Empfohlene Zufuhr [Internet]. Available from: <https://www.dge.de/wissenschaft/referenzwerte/vitamin-c/>
- 57.** DGOM e.V. Was bewirkt Ascorbin in unserem Körper? [Internet]. Available from: <https://www.dgom.de/22-inhalte/naehrstoffe/170-vitamin-c>
- 58.** Wehner-V. Segesser Sibylle. Der Trick mit dem Vitamin C [Internet]. 2008. Available from: https://www.nzz.ch/der_trick_mit_dem_vitamin_c-1.694995
- 59.** Cameron E, Pauling L. Supplemental ascorbate in the supportive treatment of cancer: Prolongation of survival times in terminal human cancer. *Proc Natl Acad Sci U S A.* 1976;73(10):3685-9. doi:10.1073/pnas.73.10.3685
- 60.** Chakraborty A, Ramani P, Sherlin HJ, Premkumar P, Natesan A. Antioxidant and pro-oxidant activity of Vitamin C in oral environment. *Indian J Dent Res.* 2014;25(4):499-504. doi:10.4103/0970-9290.142547
- 61.** Padayatty SJ, Katz A, Wang Y, Eck P, Kwon O, Lee J-H, Chen S, Corpe C, Dutta A, Dutta SK, Levine M. Vitamin C as an antioxidant: evaluation of its role in disease prevention. *J Am Coll Nutr.* 2003;22(1):18-35. doi:10.1080/07315724.2003.10719272
- 62.** Choi HK, Kim G-J, Yoo H-S, Song DH, Chung K-H, Lee K-J, Koo YT, An JH. Vitamin C Activates Osteoblastogenesis and Inhibits Osteoclastogenesis via Wnt/ β -Catenin/ATF4 Signaling Pathways. *Nutrients.* 2019;11(3). doi:10.3390/nu11030506
- 63.** Chin K-Y, Ima-Nirwana S. Vitamin C and Bone Health: Evidence from Cell, Animal and Human Studies. *Curr Drug Targets.* 2018;19(5):439-50. doi:10.2174/1389450116666150907100838
- 64.** Aghajanian P, Hall S, Wongworawat MD, Mohan S. The Roles and Mechanisms of Actions of Vitamin C in Bone: New Developments. *J Bone Miner Res.* 2015;30(11):1945-55. doi:10.1002/jbmr.2709
- 65.** Haines DD, Varga B, Bak I, Juhasz B, Mahmoud FF, Kalantari H, Gesztelyi R, Lekli I, Czompa A, Tosaki A. Summative interaction between astaxanthin, Ginkgo biloba extract (EGb761) and vitamin C in suppression of respiratory inflammation: a comparison with ibuprofen. *Phytother Res.* 2011;25(1):128-36. doi:10.1002/ptr.3160
- 66.** Boyera N, Galey I, Bernard BA. Effect of vitamin C and its derivatives on collagen synthesis and cross-linking by normal human fibroblasts. *Int J Cosmet Sci.* 1998;20(3):151-8. doi:10.1046/j.1467-2494.1998.171747.x
- 67.** Carpenter KJ. The discovery of vitamin C. *Ann Nutr Metab.* 2012;61(3):259-64. doi:10.1159/000343121
- 68.** Hemilä H. Vitamin C and Infections. *Nutrients.* 2017;9(4). doi:10.3390/nu9040339
- 69.** Aponet.de. Die Top 5 der Vitamin-C-Bomben [Internet]. Available from: <https://www.aponet.de/wissen/gesunde-ernaehrung-und-sport/vitamine-mineralien-und-spurenel/vitamine-im-ueberblick/vitamin-c-bomben.html>
- 70.** adrenal-fatigue.de. Symptome der Nebennierenschwäche [Internet]. Available from: <https://www.adrenal-fatigue.de/>
- 71.** Head KA, Kelly GS. Nutrients and botanicals for treatment of stress: adrenal fatigue, neurotransmitter imbalance, anxiety, and restless sleep. *Altern Med Rev.* 2009;14(2):114-40.
- 72.** Schlereth T, Birklein F. The sympathetic nervous system and pain. *Neuromolecular Med.* 2008;10(3):141-7. doi:10.1007/s12017-007-8018-6
- 73.** Rotter D. Vitamin D - Das Sonnenhormon [Internet]. Available from: <https://www.vitamind.net/vitamin-d3/stoffwechsel/>
- 74.** Wissenschaft im Dialog. Wie ist der erste Mensch entstanden? [Internet]. Available from: <https://www.wissenschaft-im-dialog.de/projekte/wieso/artikel/beitrag/wie-ist-der-erste-mensch-entstanden/>
- 75.** Vitamin D - Das Sonnenhormon. Vitamin D - Heilmittel für MS und Autoimmunerkrankungen?: Interview mit Dr

- Coimbra über hochdosiertes Vitamin D für Multiple Sklerose und andere Autoimmunerkrankungen: Das Coimbra Protokoll. Erfolgsquote 95 Prozent. [Internet]. Available from: <https://www.vitamind.net/interviews/coimbra-ms-autoimmun/>
- 76.** Berk M, Sanders KM, Pasco JA, Jacka FN, Williams LJ, Hayles AL, Dodd S. Vitamin D deficiency may play a role in depression. *Med Hypotheses*. 2007;69(6):1316–9. doi:10.1016/j.mehy.2007.04.001
- 77.** Hoogendijk WJG, Lips P, Dik MG, Deeg DJH, Beekman ATF, Penninx BWJH. Depression is associated with decreased 25-hydroxyvitamin D and increased parathyroid hormone levels in older adults. *Arch Gen Psychiatry*. 2008;65(5):508–12. doi:10.1001/archpsyc.65.5.508
- 78.** Lee DM, Tajar A, O'Neill TW, O'Connor DB, Bartfai G, Boonen S, Bouillon R, Casanueva FF, Finn JD, Forti G, Giwercman A, Han TS, Huhtaniemi IT, Kula K, Lean ME, Punab M, Silman AJ, Vanderschueren D, Wu FC, Pendleton N. Lower vitamin D levels are associated with depression among community-dwelling European men. *J Psychopharmacol (Oxford)*. 2011;25(10):1320–8. doi:10.1177/0269881110379287
- 79.** May HT, Bair TL, Lappé DL, Anderson JL, Horne BD, Carlquist JF, Muhlestein JB. Association of vitamin D levels with incident depression among a general cardiovascular population. *Am Heart J*. 2010;159(6):1037–43. doi:10.1016/j.ahj.2010.03.017
- 80.** Wilkins CH, Sheline YI, Roe CM, Birge SJ, Morris JC. Vitamin D deficiency is associated with low mood and worse cognitive performance in older adults. *Am J Geriatr Psychiatry*. 2006;14(12):1032–40. doi:10.1097/01.JGP.0000240986.74642.7c
- 81.** Jenkins TA, Nguyen JCD, Polglaze KE, Bertrand PP. Influence of Tryptophan and Serotonin on Mood and Cognition with a Possible Role of the Gut-Brain Axis. *Nutrients*. 2016;8(1). doi:10.3390/nu8010056
- 82.** <https://people.cornellcollege.edu/bnowakthompson/pdfs/liverDetox.pdf>. What processes does the liver undergo to remove toxins? [Internet].
- 83.** Xie Z, Chen F, Li WA, Geng X, Li C, Meng X, Feng Y, Liu W, Yu F. A review of sleep disorders and melatonin. *Neurol Res*. 2017;39(6):559–65. doi:10.1080/01616412.2017.1315864
- 84.** Peschke E, Bähr I, Mühlbauer E. Melatonin and Pancreatic Islets: Interrelationships between Melatonin, Insulin and Glucagon. *Int J Mol Sci*. 2013;14(4):6981–7015. doi:10.3390/ijms14046981
- 85.** Zamanian Z, Dehghani M, Hashemi H. Outline of Changes in Cortisol and Melatonin Circadian Rhythms in the Security Guards of Shiraz University of Medical Sciences. *Int J Prev Med*. 2013;4(7):825–30.
- 86.** Bassett SM, Lupis SB, Gianferante D, Rohleder N, Wolf JM. Sleep quality but not sleep quantity effects on cortisol responses to acute psychosocial stress. *Stress*. 2015;18(6):638–44. doi:10.3109/10253890.2015.1087503
- 87.** National Sleep Foundation. How Blue Light Affects Kids & Sleep [Internet]. Available from: <https://www.sleepfoundation.org/articles/how-blue-light-affects-kids-sleep>
- 88.** Wahl S, Engelhardt M, Schaupp P, Lappe C, Ivanov IV. The inner clock-Blue light sets the human rhythm. *J Biophotonics*. 2019;e201900102. doi:10.1002/jbio.201900102
- 89.** van Giau V, Wu SY, Jamerlan A, An SSA, Kim S, Hulme J. Gut Microbiota and Their Neuroinflammatory Implications in Alzheimer's Disease. *Nutrients*. 2018;10(11). doi:10.3390/nu10111765
- 90.** Patrick RP, Ames BN. Vitamin D hormone regulates serotonin synthesis. Part 1: relevance for autism. *FASEB J*. 2014;28(6):2398–413. doi:10.1096/fj.13-246546
- 91.** Patrick RP, Ames BN. Vitamin D and the omega-3 fatty acids control serotonin synthesis and action, part 2: relevance for ADHD, bipolar disorder, schizophrenia, and impulsive behavior. *FASEB J*. 2015;29(6):2207–22. doi:10.1096/fj.14-268342
- 92.** Salmon L. Tired? The vitamins and minerals your body needs to help you sleep better: Not sleeping well is awful, so here are 10 natural remedies that could help you get some shut-eye. [Internet]. 2018. Available from: <http://home.bt.com/lifestyle/health/sleep/tired-the-vitamins-and-minerals-your-body-needs-to-help-you-sleep-better-11364098011805>
- 93.** HILOTHERM Clinic + HomeCare. 10 – 35 °C HILOTHERAPY® zur Vermeidung von Schwellungen, Hämatomen, Entzündungen und Schmerzen [Internet]. Available from: https://www.hilotherm.com/sites/default/files/RZ_HT_Clinic_Broschuere_DE_ANSICHT_1.pdf

The importance of vitamin D

Vitamin D is produced in the body in several stages. The final stage of vitamin D3 in the cell is a hormone called calcitriol which, together with the parathyroid hormone (PTH), is one of the most important hormonal elements in controlling the calcium and phosphate balance⁽¹⁾. The parathyroid hormone is secreted by the parathyroid gland and released when the calcium level drops. It leads indirectly to the activation of osteoclasts (“bone-eating cells”) and the mobilization of calcium and phosphate from the bone tissue. The result is increased calcium in the blood and decreased mineral content in the bones (osteopenia, osteoporosis). The synthesis and release of PTH is inhibited by calcitriol. Calcitriol thus reduces the excretion of calcium from the kidneys and increases the calcium available by means of intestinal absorption. This is associated with increased osteoblast activity, i.e. the ability to form healthy new bone⁽²⁾.

In addition to its importance for calcium metabolism and, consequently, for bone formation, vitamin D3 has immunological and metabolic effects on our body. Autoimmune diseases such as multiple sclerosis or rheumatoid arthritis occur more frequently when we have low D3 levels⁽⁴⁾. Furthermore, vitamin D3 controls more than 2,000 different

genes and the immune system⁽³⁾ by decreasing our acquired immune response (especially overactive in the case of autoimmune diseases) and increasing our innate non-specific immune response. Vitamin D3 receptors are found in some cell types in our immune system, e.g. in T lymphocytes, especially T helper cells⁽⁵⁾. In experiments, the elimination of these receptors led to outbreaks of inflammatory bowel disease. Vitamin D deficiency can lead to dysbiosis of the intestinal microbiome and trigger colitis⁽⁶⁾.

Vitamin D3 also strengthens antimicrobial peptides (AMPs). These often kill microorganisms, i.e. bacteria and viruses, faster and more effectively than our acquired immune system does by activating specialized defense cells. The proven resistance to influenza brought about by sufficient vitamin D3 is based on the inhibition of the NF- κ B transcription factor^(7,8). Nuclear factor kappa B (NF- κ B) is a protein that is activated by cell stress and causes both an inflammatory cascade and the formation of free radicals. Vitamin D3 thus plays a regulating role in cell stress reactions, subject to the availability of a sufficient supply of 25-hydroxyvitamin D3 (storage form of vitamin D3). Studies show an increased predisposition to respiratory infections in children and adolescents^(9,10). The permanent activation of NF- κ B can also trigger a preventive effect with regard to cardiovascular diseases, heart attacks, cancer, MS and chronic fatigue⁽¹¹⁻¹⁸⁾. D3 helps patients activate their parasympathetic nervous system, ensuring healthy sleep and necessary relaxation. The skin produces 80% of our vitamin D3 by converting its own 7-dehydrocholesterol. UVB radiation is required to convert this substance into the previtamin D3 by photolysis⁽¹⁹⁾. Previtamin D3 is then converted into the respective vitamin (cholecalciferol) by thermal isomerization. It takes the skin eight hours to convert 80% of the previtamin. As soon as the vitamin D3 enters the bloodstream, it is transported to the liver with the help of the vitamin D binding protein (DBP), where it is hydroxylated to 25-OH-vitamin D3 (calcidiol). Calcidiol is a storage form of vitamin D3. The conversion into the active steroid hormone calcitriol then continues in the kidneys⁽³⁾. Our skin’s 7-dehydrocholesterol content decreases ever more with age. Older people’s ability to form D3 in the skin is also reduced by more than half compared to 20-year-olds⁽²⁰⁾. On a sunny day, humans produce about 10,000-20,000 I.U. (International Units) of vitamin D3 per hour⁽²¹⁾. The recommended daily dose was not increased in Germany from 400 units to 800 units per day until 2012⁽²²⁾. We assume

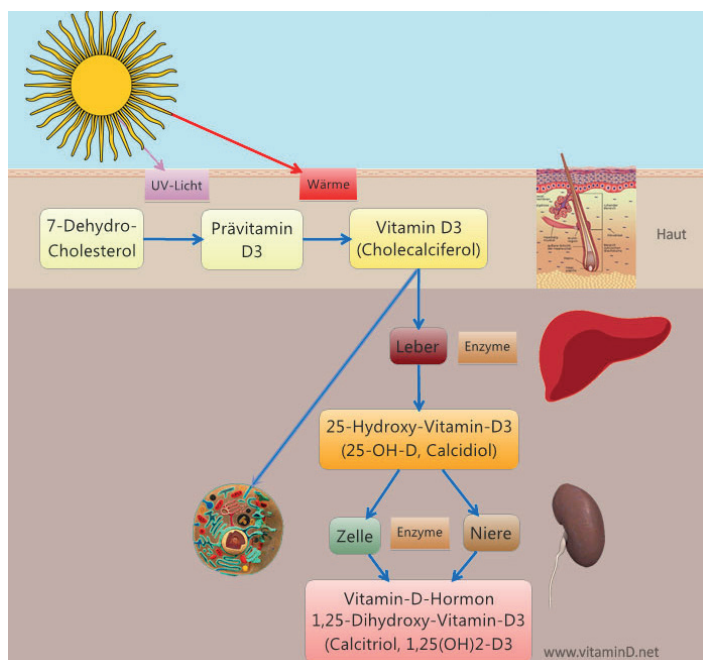


Figure 1: Synthesis of calcitriol⁽³⁾

that a protective dose of 20,000 I.U. per day will optimally prepare patients for surgical intervention. There is very little vitamin D in our diets. Only cod liver oil has a significant value of 12,000 I.U. per 100 g⁽²³⁾. Typical deficiency symptoms are rickets, osteoporosis, susceptibility to infection, gingivitis and many others^(15, 24-27). Activated vitamin D3 stimulates the formation of antimicrobial peptides on the skin and mucous membrane, and thus has an antibacterial and anti-inflammatory effect⁽²⁸⁾.

Unfortunately, in reality, we usually spend the entire day fully clothed in closed rooms far away from the equator without any exercise, and therefore have a reduced metabolism. When we do go out into the sun, we are usually far away from the equator and “protect” our body from absorbing vitamin D3 with sunscreen. When using a cream with a sun protection factor, SPF 8 is sufficient to reduce vitamin D3 production by more than 97%⁽²⁹⁾. Unfortunately, widespread obesity is another factor contributing to reduced vitamin D3 absorption, as it is then formed in the skin but cannot be released into the blood. Consequently, obese people more frequently have vitamin D deficiency⁽³⁰⁻³²⁾.

When it comes to sunscreen, it is important to know that the production of vitamin D is exclusively reliant upon long-wave UVB radiation, which accounts for the lower proportion of UV radiation. It is not dangerous for our skin. The shorter UVA rays, on the other hand, penetrate deeper into the skin and are responsible for cell damage and skin aging. Therefore, it is better to go out briefly in the midday sun, which is rich in UVB, than to follow the widespread assumption that the less intense morning and evening sun is preferable⁽²¹⁾. This is completely wrong, because the morning and evening sun contains only UVA rays. It does not facilitate D3 production, serving only to cause skin damage. Practically all sunscreens only have a UVB filter built in. On the one hand, this fatally prevents the formation of vitamin D3 in the skin. On the other hand, people may spend more time in the sun, and thus damage their skin through greater UVA exposure. Scientific findings from the Karolinska Institute in Stockholm, gathered over 20 years and involving more than 30,000 subjects, suggest that sunscreens have been proven to be responsible for the development of skin cancer⁽³³⁾, a result seconded by another study⁽³⁴⁾. Creeping poisoning with toxins contained in sunscreens certainly contributes to this situation, as these toxins are particularly easily absorbed by the skin—which after all is one of the most effective absorption organs. Titanium dioxide

nanoparticles (E171), contained in almost all sunscreens, damage the DNA and contribute to the development of Alzheimer's, epilepsy and autism. Zinc oxide nanoparticles⁽³⁵⁾, also contained in these products, are suspected of killing intestinal and brain stem cells⁽³⁶⁾.

Moreover, almost all sunscreens contain the two “super poisons” oxybenzone and octinoxate^(37, 38). For this reason, Hawaii was the first American state to ban the sale and use of sunscreens, as these toxins destroy the coral reefs⁽³⁹⁻⁴¹⁾. Interestingly, press articles mention the fatal effect of the two super toxins on corals but completely fail to mention their effect on humans, who slather them on one of their best absorption organs—namely their skin—with a surface area of 1.5-2 m², several times a day. SWISS BIOHEALTH VITAL is currently developing a sunscreen that is not only free of titanium oxide and any other toxic substances but will also have a UVA filter only. Furthermore, in 2018 it became public knowledge that the current recommendations for daily doses of vitamin D3 had been set too low⁽⁴²⁻⁴⁴⁾ - namely by a factor of 10 due to a calculation error!⁽⁴⁵⁾ We obtain 20% of our vitamin D through food⁽⁴⁶⁾. Fat-rich fish species, such as salmon and herring, have a high proportion, as do milk⁽⁴⁷⁾, porcini mushrooms, shiitake mushrooms and avocados⁽⁴⁸⁾. In general, however, there is an increasing loss of minerals and vitamins in all types of fruit and vegetables. Leached soils, air pollution, modern processing methods and storage have resulted in a drastic loss of valuable substances in our food over the past 50 years⁽⁴⁹⁾. Nowadays, you would have to eat ten times as much fruit and vegetables to get the same level of nutrients as 50 years ago. As a result of today's predominantly indoor lifestyle, the majority of the population now suffers from vitamin D deficiency^(50, 51).

It is important to note that the population of countries north of the 40th parallel (in Europe: north of Rome) cannot produce sufficient vitamin D from October to March⁽⁵²⁾. Cloudiness and the angle of incidence of the sun both impact the absorption of UVB radiation^(21, 53). If the angle is less than 45°, the path for the sun's rays through the ozone layer is too long for vitamin D to be produced, since the ozone layer absorbs part of the UV radiation. The website www.timeanddate.com enables you track the hours of sunshine along with the angle of incidence for any place in the world. For example, on January 11, 2018, in Oslo (40th latitude), there was no time of day when the sun was at an angle of incidence greater than 45°. In Tel Aviv (32nd

degree of latitude), on the other hand, optimal vitamin D production was achieved between 9:28 a.m. and 4:03 p.m. on January 11. An app is available for mobile phones (Dminder by Prof. Molick), which shows precisely how many I.U. of vitamin D can be produced at what time of day and within what time frame. There is a simple rule of thumb to remember: If your shadow is longer than your height, no vitamin D can be produced⁽²¹⁾.

Due to stressful living conditions, which lead to systemic acidosis and thus to the resorption of calcium from the bones in order to buffer the blood pH to 7.4, the body simulates a sufficiently high D3 level, which further exacerbates the lack of D3. Since vitamin D3 supports the immune system, a deficiency can have many different repercussions⁽⁵⁴⁾. Besides concentration and cardiovascular disorders, it can lead to reduced muscle strength, growth disorders, osteomalacia, immune deficiency, sleep disorders, depression and increased susceptibility to fractures^(15, 16, 26, 54-60). Neurological diseases, such as schizophrenia or autism, are vitamin D dependent; even the microbiome, our largest immune organ, is dependent on vitamin D⁽⁶¹⁾. Pregnant women are recommended to have vitamin D levels above 40 ng/ml (25-OH-D3) to protect both mother and fetus⁽⁶²⁾.

In oncology, the positive effects of vitamin D are increasingly being highlighted. Many studies have shown that low vitamin D levels in patients with colon cancer, breast cancer, chronic lymphatic leukemia and acute myeloid leukemia can be associated with a poorer clinical outcome and a worse prognosis⁽⁶³⁻⁶⁵⁾. One study also indicated that patients with B-cell lymphoma benefit from additional vitamin D administration in antibody therapy with rituximab⁽⁶⁶⁾. In patients with metastatic colon cancer, one study shows that high vitamin D levels prolong progression-free survival⁽⁶⁷⁾. The study by Borchmann et al. conducted over an observation period of 13 years followed 351 patients with Hodgkin's lymphoma to determine whether a vitamin D deficiency could be considered a risk factor for poorer tumor control. The authors were able to show that patients with vitamin D deficiency had reduced progression-free survival and overall survival durations⁽⁶⁸⁾. Vitamin D is even believed to have an anticarcinogenic effect and is recommended as a novel and economical cancer drug⁽⁶⁹⁾.

A 2016 study by Lindqvist et al. already indicated that avoiding sunlight as a risk factor for premature death was on a par with smoking⁽⁷⁰⁾. Another finding was that the prevalence of chronic diseases such as diabetes mellitus

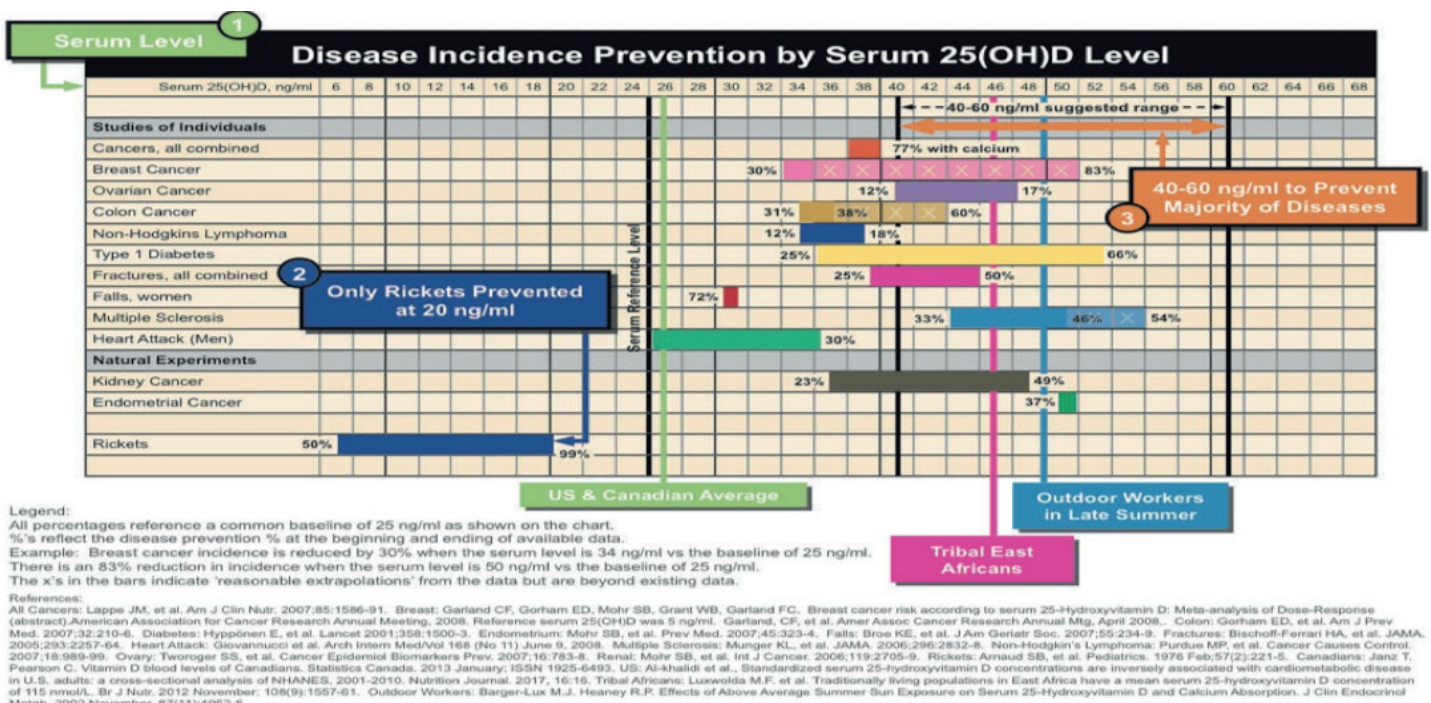


Figure 2: Disease Incidence Prevention by Serum 25(OH)D Level⁽⁷¹⁾

and multiple sclerosis increased with the distance from the equator and thus less sunlight and less time spent outdoors. A meta-analysis (see Fig. 3) showed that patients with a serum level of 40-60 ng/ml of the storage form 25-OH vitamin D₃ are protected from most chronic diseases⁽⁷¹⁾!

The importance of vitamin D has also been described several times in dentistry. A study by Woelber et al. from 2016 shows that a low-carbohydrate diet with adequate coverage of the need for omega-3 fatty acids, fiber, vitamins C and D and antioxidants can generally prevent inflammation of the gums and periodontium⁽⁷²⁾. Consequently, periodontitis no longer requires surgery, but can be prevented and treated through a supply of the above-mentioned vitamins and minerals. Teles et al. already showed in their 2012 study that patients with high vitamin D levels had significantly less gum bleeding, shallower pocket depths and less tooth loss⁽⁷³⁾.

The correlation between vitamin D deficiency and caries, molar incisor hypomineralization, gingivitis / periodontitis and tooth loss has also been demonstrated⁽⁷⁴⁻⁸⁰⁾. Vitamin D inhibits the growth and expression of virulence factors of the periodontal marker germ *Porphyromonas gingivalis*⁽⁸¹⁾; vitamin D also increases the antibacterial activity of oral epithelial cells against the periodontal germ *Aggregatibacter actinomycetem-comitans*⁽⁸²⁾. Higher vitamin D levels have a positive effect on local bone remodeling⁽⁸³⁾. A study by Choukroun et al. confirms the importance of vitamin D₃ for bone formation, on which the healing of implants depends⁽⁸⁴⁾. 1,25-(OH)₂-vitamin D₃ (= calcitriol) is the most important hormone involved in bone formation, while also reducing the propensity to inflammation. Vitamin D₃ deficiency inhibits the healing of implants and raises the risk of infection⁽⁸⁴⁻⁸⁶⁾.

Dental X-rays can also provide information about vitamin D₃ deficiency: In patients with severe vitamin D₃ deficiency, the pulp horns are asymmetrical and narrowed and look like a hard-back chair. Healthy pulp resembles a round arch with wider pulp horns⁽⁸⁷⁾. The conversion into the active vitamin D hormone and further transport within the body rely particularly heavily upon magnesium⁽⁸⁸⁻⁹⁰⁾. Magnesium deficiency would block the entire supply of PTH, calcium and vitamin D⁽⁹¹⁾. Protein synthesis and the activation of some genes also require vitamin A in a balanced concentration to vitamin D⁽⁹²⁾. If the ratio is unbalanced, the vitamins

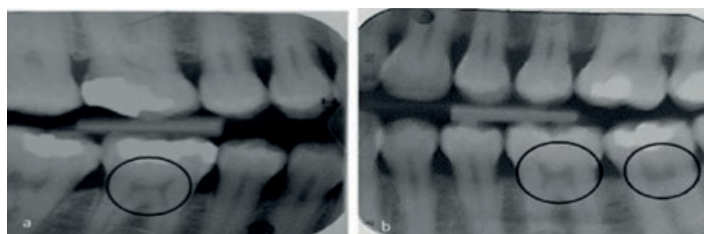


Figure 3: a) X-ray (vitamin D deficiency), (b) X-ray (normal vitamin D level)⁽⁸⁷⁾

act as antagonists, and vitamin D's action is impaired⁽⁹³⁾. A zinc deficiency also limits the function of vitamin D. Zinc is needed to form vitamin D receptors, which are found on almost all cells⁽⁹⁴⁾. BASIC IMMUNE, developed by Dr. Klinghardt and Dr. Volz, contains D₃ and K₂ as well as other co-factors in a perfectly balanced ratio. Intake should be started four weeks before the surgical procedure. Even the German Olympic sailing team takes BASIC IMMUNE in order to be optimally prepared for the Olympics. They noticed a tremendous increase in performance and faster regeneration time.

In view of our current lifestyle, the fact that we live far away from the equator and tend to experience high stress levels, it is not possible to achieve the vitamin D₃ level necessary for our health through sufficient sun exposure. Even if natural sunlight were optimal, we cannot get by nowadays without taking vitamin D to protect ourselves against acute and chronic diseases and to guarantee long-term ceramic implant success.

References

1. Khundmiri SJ, Murray RD, Lederer E. PTH and Vitamin D. *Compr Physiol*. 2016;6(2):561-601. doi:10.1002/cphy.c140071
2. Rasso J. *Biochemie: 50 Tabellen*. 2nd ed. Stuttgart: Thieme; 2008. XXX, 836 Seiten. (Duale Reihe).
3. Vitamin D - das Sonnenhormon. Vitamin D Stoffwechsel: Vitamin D Stoffwechsel: So verwertet der Körper Vitamin D. Vitamin-D-Synthese in der Haut, Umwandlung in die aktiven Formen und Regulation des Vitamin-D-Hormons [Internet]. Available from: <https://www.vitamind.net/vitamin-d3/stoffwechsel/>
4. Vitamin D - das Sonnenhormon. Vitamin D - Heilmittel für MS und Autoimmunerkrankungen?: Interview mit Dr Coimbra über hochdosiertes Vitamin D für Multiple Sklerose und andere Autoimmunerkrankungen: Das Coimbra Protokoll. Erfolgsquote 95 Prozent. [Internet]. Available from: <https://www.vitamind.net/interviews/coimbra-ms-autoimmun/>
5. Smolders J, Damoiseaux J, Menheere P, Hupperts R. Vitamin D as an immune modulator in multiple sclerosis, a review. *J Neuroimmunol*. 2008;194(1-2):7-17. doi:10.1016/j.jneuroim.2007.11.014
6. Tabatabaeizadeh S-A, Tafazoli N, Ferns GA, Avan A, Ghayour-Mobarhan M. Vitamin D, the gut microbiome and inflammatory bowel disease. *J Res Med Sci*. 2018;23. doi:10.4103/jrms.JRMS_606_17
7. Chen Y, Zhang J, Ge X, Du J, Deb DK, Li YC. Vitamin D receptor inhibits nuclear factor κ B activation by interacting with I κ B kinase β protein. *J Biol Chem*. 2013;288(27):19450-8. doi:10.1074/jbc.M113.467670
8. Cohen-Lahav M, Shany S, Tobvin D, Chaimovitz C, Douvdevani A. Vitamin D decreases NF κ B activity by increasing I κ B α levels. *Nephrol Dial Transplant*. 2006;21(4):889-97. doi:10.1093/ndt/gfi254
9. Berry DJ, Hesketh K, Power C, Hyppönen E. Vitamin D status has a linear association with seasonal infections and lung function in British adults. *Br J Nutr*. 2011;106(9):1433-40. doi:10.1017/S0007114511001991
10. CANNELL JJ, VIETH R, UMHAU JC, Holick MF, GRANT WB, MADRONICH S, GARLAND CF, GIOVANNUCCI E. Epidemic influenza and vitamin D. *Epidemiol Infect*. 2006;134(6):1129-40. doi:10.1017/S0950268806007175
11. Al Mheid I, Patel R, Murrow J, Morris A, Rahman A, Fike L, Kavtaradze N, Uphoff I, Hooper C, Tangpricha V, Alexander RW, Brigham K, Quyyumi AA. Vitamin D status is associated with arterial stiffness and vascular dysfunction in healthy humans. *J Am Coll Cardiol*. 2011;58(2):186-92. doi:10.1016/j.jacc.2011.02.051
12. Anderson JL, May HT, Horne BD, Bair TL, Hall NL, Carlquist JF, Lappé DL, Muhlestein JB. Relation of vitamin D deficiency to cardiovascular risk factors, disease status, and incident events in a general healthcare population. *Am J Cardiol*. 2010;106(7):963-8. doi:10.1016/j.amjcard.2010.05.027
13. Chowdhury R, Kunutsor S, Vitezova A, Oliver-Williams C, Chowdhury S, Kiefte-de-Jong JC, Khan H, Baena CP, Prabhakaran D, Hoshen MB, Feldman BS, Pan A, Johnson L, Crowe F, Hu FB, Franco OH. Vitamin D and risk of cause specific death: systematic review and meta-analysis of observational cohort and randomised intervention studies. *BMJ*. 2014;348:g1903. doi:10.1136/bmj.g1903
14. Forman JP, Giovannucci E, Holmes MD, Bischoff-Ferrari HA, Tworoger SS, Willett WC, Curhan GC. Plasma 25-hydroxyvitamin D levels and risk of incident hypertension. *Hypertension*. 2007;49(5):1063-9. doi:10.1161/HYPERTENSIONAHA.107.087288
15. Holick MF. Vitamin D: A millenium perspective. *J Cell Biochem*. 2003;88(2):296-307. doi:10.1002/jcb.10338
16. Muscogiuri G, Annweiler C, Duval G, Karras S, Tirabassi G, Salvio G, Balercia G, Kimball S, Kotsa K, Mascitelli L, Bhattoa HP, Colao A. Vitamin D and cardiovascular disease: From atherosclerosis to myocardial infarction and stroke. *Int J Cardiol*. 2017;230:577-84. doi:10.1016/j.ijcard.2016.12.053
17. Roy S, Sherman A, Monari-Sparks MJ, Schweiker O, Hunter K. Correction of Low Vitamin D Improves Fatigue: Effect of Correction of Low Vitamin D in Fatigue Study (EViDiF Study). *N Am J Med Sci*. 2014;6(8):396-402. doi:10.4103/1947-2714.139291
18. Zhou R, Wang M, Huang H, Li W, Hu Y, Wu T. Lower Vitamin D Status Is Associated with an Increased Risk of Ischemic Stroke: A Systematic Review and Meta-Analysis. *Nutrients*. 2018;10(3). doi:10.3390/nu10030277
19. Holick MF. Environmental factors that influence the cutaneous production of vitamin D. *Am J Clin Nutr*. 1995;61(3 Suppl):638S-645S. doi:10.1093/ajcn/61.3.638S
20. MacLaughlin J, Holick MF. Aging decreases the capacity of human skin to produce vitamin D $_3$. *J Clin Invest*. 1985;76(4):1536-8. doi:10.1172/JCI112134
21. Vitamin D - das Sonnenhormon. Vitamin D und Sonne: Vitamin D und Sonne: Sonnenlicht ist die wichtigste Vitamin-D-Quelle. Das Vitamin wird durch Sonne in der Haut gebildet. Wieviel Sonne ist dafür nötig? [Internet]. Available from: <https://www.vitamind.net/sonne/>
22. Deutsche Gesellschaft für Ernährung e.V. Vitamin D (Calciferole) [Internet]. Available from: <https://www.dge.de/wissenschaft/referenzwerte/vitamin-d/>
23. Vitamin D - das Sonnenhormon. Vitamin D Lebensmittel: Vitamin D Lebensmittel: Welche Lebensmittel enthalten Vitamin D? Wie viel Vitamin D sollte man zu sich nehmen? Welche Nahrungsmittel sind die besten Quellen? [Internet]. Available from: <https://www.vitamind.net/lebensmittel/>
24. Gombart AF. The vitamin D-antimicrobial peptide path-

way and its role in protection against infection. *Future Microbiol.* 2009;4(9):1151–65. doi:10.2217/fmb.09.87

25. Miznerova E, Hlavaty T, Koller T, Toth J, Holociova K, Huorka M, Killinger Z, Payer J. The prevalence and risk factors for osteoporosis in patients with inflammatory bowel disease. *Bratisl Lek Listy.* 2013;114(8):439–45.

26. Jagelavičienė E, Vaitkevičienė I, Šilingaitė D, Šinkūnaitė E, Daugėlaitė G. The Relationship between Vitamin D and Periodontal Pathology. *Medicina (Kaunas).* 2018;54(3). doi:10.3390/medicina54030045

27. Stein SH, Tipton DA. Vitamin D and its impact on oral health--an update. *J Tenn Dent Assoc.* 2011;91(2):30-3; quiz 34-5.

28. Hiremath VP, Rao CB, Naik V, Prasad KV. Anti-inflammatory effect of vitamin D on gingivitis: a dose-response randomised control trial. *Oral Health Prev Dent.* 2013;11(1):61-9. doi:10.3290/j.ohpd.a29377

29. Gröber U. Mikronährstoffe: Metabolic Tuning - Prävention - Therapie ; mit 134 Tabellen. 3rd ed. Stuttgart: Wiss. Verl.-Ges; 2011, c 2011. S. 138. (Für die Kitteltasche).

30. Cheng S, Massaro JM, Fox CS, Larson MG, Keyes MJ, McCabe EL, Robins SJ, O'Donnell CJ, Hoffmann U, Jacques PF, Booth SL, Vasani RS, Wolf M, Wang TJ. Adiposity, cardiometabolic risk, and vitamin D status: the Framingham Heart Study. *Diabetes.* 2010;59(1):242–8. doi:10.2337/db09-1011

31. Savastano S, Barrea L, Savanelli MC, Nappi F, Di Somma C, Orio F, Colao A. Low vitamin D status and obesity: Role of nutritionist. *Reviews in Endocrine and Metabolic Disorders.* 2017;18(2):215–25. doi:10.1007/s11154-017-9410-7

32. Vimalaswaran KS, Berry DJ, Lu C, Tikkanen E, Pilz S, Hiraki LT, Cooper JD, Dastani Z, Li R, Houston DK, Wood AR, Michaëlsson K, Vandenput L, Zgaga L, Yerges-Armstrong LM, McCarthy MI, Dupuis J, Kaakinen M, Kleber ME, Jameson K, Arden N, Raitakari O, Viikari J, Lohman KK, Ferrucci L, Melhus H, Ingelsson E, Byberg L, Lind L, Lorentzon M, Salomaa V, Campbell H, Dunlop M, Mitchell BD, Herzig K-H, Pouta A, Hartikainen A-L, Streeten EA, Theodoratou E, Jula A, Wareham NJ, Ohlsson C, Frayling TM, Kritchevsky SB, Spector TD, Richards JB, Lehtimäki T, Ouwehand WH, Kraft P, Cooper C, März W, Power C, Loos RJF, Wang TJ, Järvelin M-R, Whittaker JC, Hingorani AD, Hyppönen E. Causal relationship between obesity and vitamin D status: bi-directional Mendelian randomization analysis of multiple cohorts. *PLoS Med.* 2013;10(2):e1001383. doi:10.1371/journal.pmed.1001383

33. Plourde E. Sunscreens--biohazard: Treat as hazardous waste. Irvine, CA: New Voice Publications; 2012. xx, 331.

34. Allison D. Sunscreen causes cancer, not the sun! [Internet]. 2019 [cited 2019 Nov 5]. Available from: <https://awarenessact.com/sunscreen-causes-cancer-not-the-sun/>

35. Lin W, Xu Y, Huang C-C, Ma Y, Shannon K, Chen D-R. Toxicity of nano- and micro-sized ZnO particles in human lung epithelial cells. *Journal of Nanoparticle Research.* 2008;1125–39. doi:10.1007/s11051-008-9419-7

36. Mayr-kuren.de. Die Sonne: Genuß und Schutz [Internet] [cited 2019 Nov 5]. Available from: <https://www.mayr-kuren.de/sonne-sonnenschutz.html#sonnencreme>

37. DiNardo JC, Downs CA. Dermatological and environmental toxicological impact of the sunscreen ingredient oxybenzone/benzophenone-3. *J Cosmet Dermatol.* 2018;17(1):15–9. doi:10.1111/jocd.12449

38. Schneider SL, Lim HW. Review of environmental effects of oxybenzone and other sunscreen active ingredients. *J Am Acad Dermatol.* 2019;80(1):266–71. doi:10.1016/j.jaad.2018.06.033

39. The Guardian. Hawaii becomes first US state to ban sunscreens harmful to coral reefs [Internet]. 2018 [cited 2019 Nov 5]. Available from: <https://www.theguardian.com/travel/2018/may/03/hawaii-becomes-first-us-state-to-ban-sunscreens-harmful-to-coral-reefs>

40. Raffa RB, Pergolizzi JV, Taylor R, Kitzen JM. Sunscreen bans: Coral reefs and skin cancer. *J Clin Pharm Ther.* 2019;44(1):134–9. doi:10.1111/jcpt.12778

41. Siller A, Blaszkak SC, Lazar M, Olasz Harken E. Update About the Effects of the Sunscreen Ingredients Oxybenzone and Octinoxate on Humans and the Environment. *Plast Surg Nurs.* 2018;38(4):158–61. doi:10.1097/PSN.0000000000000244

42. Papadimitriou DT. The Big Vitamin D Mistake. *J Prev Med Public Health.* 2017;50(4):278–81. doi:10.3961/jpmph.16.111

43. Veugelers PJ, Ekwaru JP. A statistical error in the estimation of the recommended dietary allowance for vitamin D. *Nutrients.* 2014;6(10):4472–5. doi:10.3390/nu6104472

44. Zentrum der Gesundheit. Tagesbedarf für Vitamin D: Ein Rechenfehler [Internet]. 2019 [updated 2019 Oct 30]. Available from: <https://www.zentrum-der-gesundheit.de/tagesbedarf-vitamin-d-ia.html>

45. Heaney Robert P. The IOM Miscalculated Its RDA For Vitamin D [Internet]. 2015. Available from: <http://blogs.creighton.edu/heaney/2015/02/13/the-iom-miscalculated-its-rda-for-vitamin-d/>

46. Lauer N. Gesund mit veganer Ernährung.

47. Zittermann A, Gummert JF. Nonclassical vitamin D action. *Nutrients.* 2010;2(4):408–25. doi:10.3390/nu2040408

48. Vitamin D - das Sonnenhormon. Vitamin D Lebensmittel: Vitamin D Lebensmittel: Welche Lebensmittel enthalten Vitamin D? Wie viel Vitamin D sollte man zu sich nehmen? Welche Nahrungsmittel sind die besten Quellen? [Internet]. Available from: <https://www.vitamind.net/lebensmittel/>

- 49.** Mayer A-M. Historical changes in the mineral content of fruits and vegetables. *British Food Journal*. 1997;99:207-11. doi:10.1108/00070709710181540
- 50.** Chapuy MC, Preziosi P, Maamer M, Arnaud S, Galan P, Hercberg S, Meunier PJ. Prevalence of vitamin D insufficiency in an adult normal population. *Osteoporos Int*. 1997;7(5):439-43. doi:10.1007/s001980050030
- 51.** van Schoor NM, Lips P. Worldwide vitamin D status. *Best Pract Res Clin Endocrinol Metab*. 2011;25(4):671-80. doi:10.1016/j.beem.2011.06.007
- 52.** Webb AR, Kline L, Holick MF. Influence of season and latitude on the cutaneous synthesis of vitamin D₃: exposure to winter sunlight in Boston and Edmonton will not promote vitamin D₃ synthesis in human skin. *J Clin Endocrinol Metab*. 1988;67(2):373-8. doi:10.1210/jcem-67-2-373
- 53.** Chen T, Lu Z, Holick M. Photobiology of Vitamin D. In: *Vitamin D: Physiology, Molecular Biology, and Clinical Applications*; 2010. p. 35-60.
- 54.** Azrielant S, Shoenfeld Y. Vitamin D and the Immune System. *Isr Med Assoc J*. 2017;19(8):510-1.
- 55.** Berridge MJ. Vitamin D deficiency: Infertility and neurodevelopmental diseases (attention deficit hyperactivity disorder, autism, and schizophrenia). *Am J Physiol , Cell Physiol*. 2018;314(2):C135-C151. doi:10.1152/ajpcell.00188.2017
- 56.** Ganmaa D, Stuart JJ, Sumberzul N, Ninjin B, Giovannucci E, Kleinman K, Holick MF, Willett WC, Frazier LA, Rich-Edwards JW. Vitamin D supplementation and growth in urban Mongol school children: Results from two randomized clinical trials. *PLoS ONE*. 2017;12(5):e0175237. doi:10.1371/journal.pone.0175237
- 57.** Gao Q, Kou T, Zhuang B, Ren Y, Dong X, Wang Q. The Association between Vitamin D Deficiency and Sleep Disorders: A Systematic Review and Meta-Analysis. *Nutrients*. 2018;10(10). doi:10.3390/nu10101395
- 58.** Chiang C-M, Ismaeel A, Griffis RB, Weems S. Effects of Vitamin D Supplementation on Muscle Strength in Athletes: A Systematic Review. *J Strength Cond Res*. 2017;31(2):566-74. doi:10.1519/JSC.0000000000001518
- 59.** Parker GB, Brotchie H, Graham RK. Vitamin D and depression. *J Affect Disord*. 2017;208:56-61. doi:10.1016/j.jad.2016.08.082
- 60.** Bischoff-Ferrari HA, Willett WC, Wong JB, Giovannucci E, Dietrich T, Dawson-Hughes B. Fracture prevention with vitamin D supplementation: a meta-analysis of randomized controlled trials. *JAMA*. 2005;293(18):2257-64. doi:10.1001/jama.293.18.2257
- 61.** Kočovská E, Gaughran F, Krivoy A, Meier U-C. Vitamin-D Deficiency As a Potential Environmental Risk Factor in Multiple Sclerosis, Schizophrenia, and Autism. *Front Psychiatry*. 2017;8:47. doi:10.3389/fpsy.2017.00047
- 62.** Wagner CL, Hollis BW. The Implications of Vitamin D Status During Pregnancy on Mother and her Developing Child. *Front Endocrinol (Lausanne)*. 2018;9:500. doi:10.3389/fendo.2018.00500
- 63.** Maalmi H, Ordóñez-Mena JM, Schöttker B, Brenner H. Serum 25-hydroxyvitamin D levels and survival in colorectal and breast cancer patients: systematic review and meta-analysis of prospective cohort studies. *Eur J Cancer*. 2014;50(8):1510-21. doi:10.1016/j.ejca.2014.02.006
- 64.** Shanafelt TD, Drake MT, Maurer MJ, Allmer C, Rabe KG, Slager SL, Weiner GJ, Call TG, Link BK, Zent CS, Kay NE, Hanson CA, Witzig TE, Cerhan JR. Vitamin D insufficiency and prognosis in chronic lymphocytic leukemia. *Blood*. 2011;117(5):1492-8. doi:10.1182/blood-2010-07-295683
- 65.** Lee HJ, Muindi JR, Tan W, Hu Q, Wang D, Liu S, Wilding GE, Ford LA, Sait SNJ, Block AW, Adjei AA, Barcos M, Griffiths EA, Thompson JE, Wang ES, Johnson CS, Trump DL, Wetzler M. Low 25(OH) vitamin D₃ levels are associated with adverse outcome in newly diagnosed, intensively treated adult acute myeloid leukemia. *Cancer*. 2014;120(4):521-9. doi:10.1002/cncr.28368
- 66.** Bittenbring JT, Neumann F, Altmann B, Achenbach M, Reichrath J, Ziepert M, Geisel J, Regitz E, Held G, Pfreundschuh M. Vitamin D deficiency impairs rituximab-mediated cellular cytotoxicity and outcome of patients with diffuse large B-cell lymphoma treated with but not without rituximab. *J Clin Oncol*. 2014;32(29):3242-8. doi:10.1200/JCO.2013.53.4537
- 67.** Ng K, Nimeiri HS, McCleary NJ, Abrams TA, Yurgelun MB, Cleary JM, Rubinson DA, Schrag D, Miksad R, Bullock AJ, Allen J, Zuckerman D, Chan E, Chan JA, Wolpin BM, Constantine M, Weckstein DJ, Faggen MA, Thomas CA, Kournioti C, Yuan C, Ganser C, Wilkinson B, Mackintosh C, Zheng H, Hollis BW, Meyerhardt JA, Fuchs CS. Effect of High-Dose vs Standard-Dose Vitamin D₃ Supplementation on Progression-Free Survival Among Patients With Advanced or Metastatic Colorectal Cancer: The SUNSHINE Randomized Clinical Trial. *JAMA*. 2019;321(14):1370-9. doi:10.1001/jama.2019.2402
- 68.** Borchmann S, Cirillo M, Goergen H, Meder L, Sasse S, Kreissl S, Bröckelmann PJ, Tresckow B v., Fuchs M, Ullrich RT, Engert A. Pretreatment Vitamin D Deficiency Is Associated With Impaired Progression-Free and Overall Survival in Hodgkin Lymphoma. *Journal of Clinical Oncology*. 2019;JCO.19.00985. doi:10.1200/JCO.19.00985
- 69.** Wu X, Hu W, Lu L, Zhao Y, Zhou Y, Xiao Z, Zhang L, Zhang H, Li X, Li W, Wang S, Cho CH, Shen J, Li M. Repurposing vitamin D for treatment of human malignancies via targeting tumor microenvironment. *Acta Pharm Sin B*. 2019;9(2):203-19. doi:10.1016/j.apsb.2018.09.002
- 70.** Lindqvist PG, Epstein E, Nielsen K, Landin-Olsson M,

- Ingvar C, Olsson H. Avoidance of sun exposure as a risk factor for major causes of death: a competing risk analysis of the Melanoma in Southern Sweden cohort. *J Intern Med*. 2016;280(4):375–87. doi:10.1111/joim.12496
- 71.** GrassrootsHealth Nutrient Research Institute. Lower Disease Incidence with Vitamin D levels 40-60 ng/ml [Internet] [cited 2019 Nov 5]. Available from: <https://www.grassrootshealth.net/project/general-health/>
- 72.** Woelber JP, Bremer K, Vach K, König D, Hellwig E, Ratka-Krüger P, Al-Ahmad A, Tennert C. An oral health optimized diet can reduce gingival and periodontal inflammation in humans - a randomized controlled pilot study. *BMC Oral Health*. 2016;17(1):28. doi:10.1186/s12903-016-0257-1
- 73.** Teles FR, Teles RP, Martin L, Socransky SS, Haffajee AD. Relationships among interleukin-6, tumor necrosis factor- α , adipokines, vitamin D, and chronic periodontitis. *J Periodontol*. 2012;83(9):1183–91. doi:10.1902/jop.2011.110346
- 74.** Kim I-J, Lee H-S, Ju H-J, Na J-Y, Oh H-W. A cross-sectional study on the association between vitamin D levels and caries in the permanent dentition of Korean children. *BMC Oral Health*. 2018;18(1):43. doi:10.1186/s12903-018-0505-7
- 75.** Schroth RJ, Rabbani R, Loewen G, Moffatt ME. Vitamin D and Dental Caries in Children. *J Dent Res*. 2016;95(2):173–9. doi:10.1177/0022034515616335
- 76.** Kühnisch J, Thiering E, Kratzsch J, Heinrich-Weltzien R, Hickel R, Heinrich J. Elevated serum 25(OH)-vitamin D levels are negatively correlated with molar-incisor hypomineralization. *J Dent Res*. 2015;94(2):381–7. doi:10.1177/0022034514561657
- 77.** Bhargava A, Rastogi P, Lal N, Singhal R, Khatoon S, Ali Mahdi A. Relationship between VITAMIN D and chronic periodontitis. *J Oral Biol Craniofac Res*. 2019;9(2):177–9. doi:10.1016/j.jobcr.2018.07.001
- 78.** Meghil MM, Hutchens L, Raed A, Multani NA, Rajendran M, Zhu H, Looney S, Elashiry M, Arce RM, Peacock ME, Dong Y, Cutler CW. The influence of vitamin D supplementation on local and systemic inflammatory markers in periodontitis patients: A pilot study. *Oral Dis*. 2019;25(5):1403–13. doi:10.1111/odi.13097
- 79.** Nørrisgaard PE, Haubek D, Kühnisch J, Chawes BL, Stokholm J, Bønnelykke K, Bisgaard H. Association of High-Dose Vitamin D Supplementation During Pregnancy With the Risk of Enamel Defects in Offspring: A 6-Year Follow-up of a Randomized Clinical Trial. *JAMA Pediatr*. 2019. doi:10.1001/jamapediatrics.2019.2545
- 80.** Zhan Y, Samietz S, Holtfreter B, Hannemann A, Meisel P, Nauck M, Völzke H, Wallaschofski H, Dietrich T, Kocher T. Prospective Study of Serum 25-hydroxy Vitamin D and Tooth Loss. *J Dent Res*. 2014;93(7):639–44. doi:10.1177/0022034514534985
- 81.** Grenier D, Morin M-P, Fournier-Larente J, Chen H. Vitamin D inhibits the growth of and virulence factor gene expression by *Porphyromonas gingivalis* and blocks activation of the nuclear factor kappa B transcription factor in monocytes. *J Periodont Res*. 2016;51(3):359–65. doi:10.1111/jre.12315
- 82.** McMahon L, Schwartz K, Yilmaz O, Brown E, Ryan LK, Diamond G. Vitamin D-mediated induction of innate immunity in gingival epithelial cells. *Infect Immun*. 2011;79(6):2250–6. doi:10.1128/IAI.00099-11
- 83.** Schulze-Späte U, Dietrich T, Wu C, Wang K, Hasturk H, Dibart S. Systemic vitamin D supplementation and local bone formation after maxillary sinus augmentation - a randomized, double-blind, placebo-controlled clinical investigation. *Clin Oral Implants Res*. 2016;27(6):701–6. doi:10.1111/clr.12641
- 84.** Choukroun J, Khoury G, Khoury F, Russe P, Testori T, Komiyama Y, Sammartino G, Palacci P, Tunali M, Choukroun E. Two neglected biologic risk factors in bone grafting and implantology: high low-density lipoprotein cholesterol and low serum vitamin D. *J Oral Implantol*. 2014;40(1):110–4. doi:10.1563/AAID-JOI-D-13-00062
- 85.** Bryce G, MacBeth N. Vitamin D deficiency as a suspected causative factor in the failure of an immediately placed dental implant: a case report. *J R Nav Med Serv*. 2014;100(3):328–32.
- 86.** Cooper LF. Systemic effectors of alveolar bone mass and implications in dental therapy. *Periodontol 2000*. 2000;23:103–9. doi:10.1034/j.1600-0757.2000.2230110.x
- 87.** zm-online. Wie der Zahnarzt einen Vitamin D-Mangel diagnostiziert: Auch der Zahnarzt kann einen Vitamin D-Mangel diagnostizieren. Und zwar mithilfe einer einfachen Röntgenaufnahme, wie kanadische Anthropologen jetzt herausgefunden haben. [Internet]. 2018 [cited 2019 Nov 5]. Available from: <https://www.zm-online.de/news/zahnmedizin/wie-der-zahnarzt-einen-vitamin-d-mangel-diagnostiziert>
- 88.** Risco F, Traba ML. Influence of magnesium on the in vitro synthesis of 24,25-dihydroxyvitamin D₃ and 1 α , 25-dihydroxyvitamin D₃. *Magnes Res*. 1992;5(1):5–14.
- 89.** Risco F, Traba ML. Possible involvement of a magnesium dependent mitochondrial alkaline phosphatase in the regulation of the 25-hydroxyvitamin D₃-1 α -and 25-hydroxyvitamin D₃-24R-hydroxylases in LLC-PK1 cells. *Magnes Res*. 1994;7(3-4):169–78.
- 90.** Zittermann A. Magnesium deficit ? overlooked cause of low vitamin D status? *BMC Med*. 2013;11:229. doi:10.1186/1741-7015-11-229
- 91.** Zofková I, Kancheva RL. The relationship between magnesium and calciotropic hormones. *Magnes Res*. 1995;8(1):77–84.

- 92.** Sánchez-Martínez R, Castillo AI, Steinmeyer A, Aranda A. The retinoid X receptor ligand restores defective signaling by the vitamin D receptor. *EMBO Rep.* 2006;7(10):1030–4. doi:10.1038/sj.embor.7400776
- 93.** Johansson S, Melhus H. Vitamin A antagonizes calcium response to vitamin D in man. *J Bone Miner Res.* 2001;16(10):1899–905. doi:10.1359/jbmr.2001.16.10.1899
- 94.** Freedman L TT. DNA Binding Properties of the Vitamin D3 Receptor Zinc Finger Regio. *Molecular Endocrinology*;1991(Vol 5 No.12):1815–26.

Restoration

Within the context of “THE SWISS BIOHEALTH CONCEPT”, the term “restoration” refers to a defined, systematic algorithm of treatment sequences that aim to:

- reduce the strain on the immune system as quickly as possible
- ensure the greatest possible safety, especially as regards infection and intoxication
- provide rapid, standardized treatment in a time-efficient, cost-effective manner This point is often neglected by dentists and oral surgeons in that they consider only the primary costs their patients incur (dentist’s fees, material, dental lab work). It is often the case, however, that secondary costs prove far greater for patients: travel, accommodation, absences from work, inability to work due to swelling, etc.

Restoration Sequence

The ALL IN ONE CONCEPT follows the below steps in the order presented in one appointment wherever possible, or over two to three appointments on subsequent days if necessary. This is the “treatment sequence”. Crucially, no further invasive or detoxifying measures are taken during the day to three days after the surgery, because it is during this period that patients go through the so-called “catabolic phase”. During the development of this concept, Dr. Dietrich Klinghardt’s four-phase concept was borne in mind. It encompasses a treatment period of up to two years, within which the few days of biological dental therapy account for around 60% of the improvement in health.

1st step: Gentle, stress-free metal removal using protective measures to relieve the strain on the immune system without burdening the body, preferably the day before surgery. Amalgam removal using six-fold protection and insertion of

CEREC ceramic inlays or long-term temporaries. Removal of crowns/bridges using cofferdam protection and replacement with long-term temporaries. Removal of crowns using cofferdam protection and of any titanium implant abutments.

2nd step: Removal of all root-canal-treated and infected teeth, root residues, wisdom teeth, FDOJs and foreign bodies, quadrant by quadrant, followed by immediate implantation. The following sequence should ideally be followed during the operation:

Women: bottom right, top right, bottom left, top left

Men: bottom left, top left, bottom right, top right


This sequence is derived from the YIN-YANG system, ensuring the immune system is relieved of strain in the quickest, most far-reaching manner possible. It is for this reason that women should sleep on men’s “heart side”, namely to their left.

3rd step: Production of fixed, metal-free long-term temporaries to stay in the mouth for three to a maximum of 12 months. These temporaries should look very similar to the final crowns, protect the teeth and implants, restore the bite height and promote detoxification. Patients are instructed not to chew any hard foods on the implants for the first six weeks after the procedure, so as not to impair complication-free healing.

4th step: After three to four months, an examination is carried out, checking how the implants have healed using the periosteum test, ascertaining the status of any previously precarious situations and, if necessary, commencing further treatment in this temporary restoration phase. The long-term temporaries are also used to perfectly adjust the bite height during this phase.

The four treatment stages:

- 3-4m: establishment of normal physiology
- 1-2d: removal of metals, dead teeth / titanium implants / osteonecroses (FDOJs, etc.)
- 2-6m: detoxification of all systems (DMPS, chlorella, etc.)
- 2m: immune modulation (90% of all symptoms are caused by immune reactions to toxins and germs)
- 6-12m: reduction of pathogenic germs and normalization of the microbiome



5th step: As soon as a stable, healthy state has been achieved thanks to the long-term temporaries, these are replaced with the final ceramic crowns.

Metal restoration

With mercury being so dangerous, its removal requires special protective measures, and the body should be optimally prepared beforehand.

Commence our detoxification protocol (see below) as early as 14 days before the planned appointment or follow the instructions from the environmental physician or naturopath who referred you. This promotes your body's ability to detoxify. This is extremely important, because, even under the most stringent of protective measures, a certain amount of mercury vapor entering the body during amalgam removal is unavoidable. Stepping up your supplement regime provides your body with the preconditions under which to optimally capture and excrete these toxins. In conjunction with the special protective measures, this minimizes, if not eliminates, the risk of the removal causing acute poisoning.

The detoxification protocol supports the body in its detoxifying function with the aim of ensuring the amalgam removal phase can be completed without further complications. By no means does it constitute complete heavy metal drainage. Complete detoxification cannot be carried out correctly until all of the interference fields in the oral cavity have been thoroughly removed (metal and interference field restoration). Please consult your doctor or naturopath in this regard.

Detoxification protocol

In the days before the amalgam is removed, all foods with harmful effects should be eliminated from your diet. This means: no coffee, alcohol, tobacco, simple sugars, gluten or cow's milk products. Water, healthy fats, vegetables and salads of all kinds as well as a healthy lifestyle with plenty of sleep, exercise and sunshine have a positive, stimulating effect. You should begin taking the following dietary supplements and medicines 14 days before amalgam removal and continue to take them for 14 days afterwards:

- chlorella vulgaris pellets: 8-10 pellets three times per day (30 min. before meals, last dose just before bed)

- zinc gluconate or citrate: 20 mg two times per day with food
- Omega-3 fish oil: 2 capsules with breakfast, 4 capsules before bed
- magnesium citrate: 2 capsules in the morning and with your evening meal

Maintain this same diet on the day of amalgam removal. Please drink large quantities of water after treatment.

Subsequently, a professional and personalized amalgam drainage plan should be followed under the guidance of an environmental physician or naturopath. There continue to be discussions as to whether amalgam should be removed as quickly as possible in a single appointment or over a series of appointments with plenty of time in between. These discussions are futile and misdirected: Suggesting staggered removal over several appointments clearly implies that those in favor of this method do not feel equipped to remove the amalgam with absolute safety and without subjecting the patient to any sort of contamination or stress. If this is the case, the dentist should not be removing any amalgam at all, because it consists of over 50% mercury—the most poisonous non-radioactive element, which can cause the most severe of illnesses even in the smallest doses^(2,3). Instead, the correct approach is to follow an amalgam removal protocol as described below, which ensures the patient is not contaminated with any mercury. Provided this is done, the amalgam fillings ought to be removed as quickly as possible in as few appointments as possible.

Amalgam removal using six-fold protection

It is easy to make mistakes during amalgam removal that can have fatal consequences for the patient. Usually, dentists drill the filling out without any protective measures whatsoever. They have not been made aware of the issues set out above, because these deviate from conventional university teachings. However, in doing so, they release huge quantities of highly toxic, anorganic mercury vapor (HgO)⁽⁴⁾. After routine amalgam removal like this, it is not uncommon for patients to experience neurological complaints, chronic fatigue, joint and muscle complaints or other symptoms recently added to this list. For this reason, it is imperative that six-fold protection be used when removing amalgam fillings:

- Using a cofferdam, a protective rubber cloth, provides protection from amalgam chips and fragments, which could come loose and collect in the tissue. The most recent generation is latex-free and made out of silicone (ROEKO: Flexidam). This has the advantage that mercury in gaseous form cannot penetrate silicone.
- Using a clean-up suction device. This provides additional protection from mercury vapor, as the device is positioned above the tooth being treated.
- Carefully drilling at a low speed using a carbide cutter to prevent the development of toxic mercury vapors.
- Using a gold-coated nose guard. This absorbs mercury vapors, because gold and mercury have a high mutual affinity. Breathing masks categorized as FFP3 are good and affordable alternatives. They protect not only against 99% of mercury but also against all toxic dust, smoke and aerosols smaller than 0.6 μm , carcinogenic and radioactive substances as well as viruses, bacteria and fungal spores.
- Using an iQ-Air ambient exchanger: a type of “nozzle” positioned as closely as possible to the oral cavity. The device then works similarly to a vacuum cleaner, using an extremely high suction force to extract all the air in the area surrounding the heads of the patient and the staff performing the treatment, filtering out mercury and pathogens before releasing it back into the room.
- Once the amalgam has been removed, a chlorella algae insert is placed in the tooth to bind any mercury remaining there.

Supplying oxygen through a nasal tube is no longer recommended, because, according to Dr. Klinghardt, it opens the blood-brain barrier and does more harm than good. Depending on the state of the patient’s health, the teeth are either treated immediately and conclusively (using ceramic or composite) or temporarily with cement (glass ionomer cement fillings) until drainage is complete. Infusions of high doses of vitamin C and other micronutrients may also be provided on an optional basis.

Removal of metal inlays, metal crowns and metal bridges using cofferdam protection

All metals are removed using cofferdam protection at the very least to prevent metal particles from being absorbed by the mucous membranes and the gastrointestinal tract. In the event of serious illnesses such as ALS or upon the patient’s request, maximum protection (see amalgam removal) may also be used for general metal removal.

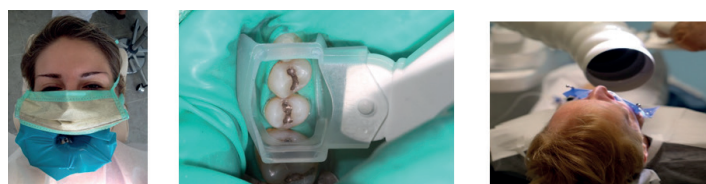

Figure 1: Amalgam removal using six-fold protection

Explantation of titanium implants

Using a special system (Implant Removal Set[®], Neobiotech) it is possible in most cases to unscrew the titanium implants from the bone without incurring the usual bone defect. Depending on the state of the patient’s health, a fully ceramic implant can then be fitted directly without having to wait for the bone to heal. Switching out titanium for ceramic in this way avoids bone loss and saves time, because the new implant can be screwed directly into the same bone cavity. In cases where there is no titanium intolerance and no electrosensitivity, the titanium implant may be left in for the time being. The structure and the screw on the implant are usually made of a gold alloy, and must therefore always be replaced with a fully ceramic structure (abutment) with a titanium screw to avoid a localized current flow. With the introduction of mobile 5G and subsequent networks, we assume that all titanium implants will need to be removed, because the overheating of the bone as a result of the antenna effect and the subsequent destruction of proteins above 42°C will lead to a general loosening of titanium implants and greater bone loss.

FDOK (fatty degenerative osteonecrosis and osteolysis of the jawbone), formerly NICO (neuralgia inducing cavitation osteonecrosis) or IO (ischemic osteonecrosis)

Wisdom teeth

It is justified to ask why wisdom teeth should play such an important role in western industrialized nations and why they are so often displaced transversely in the jaw, have insufficient room to erupt and therefore require surgical removal. Has nature made a mistake?

No, it is evolution that has made a mistake, if anything! At some point, mothers in western industrialized nations

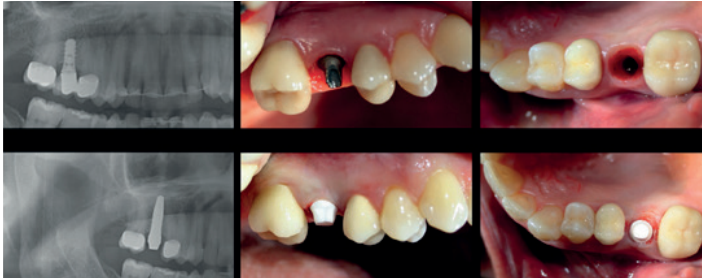


Figure 2: Explantation of a titanium implant and insertion of a ceramic implant

started to shorten the period during which they breastfed, giving it up entirely or expressing breast milk and giving it to their babies in bottles. Suckling at the mother's breast, however, alongside the many other emotional and psychological advantages, serves to improve the stomatognathic system and encourage the jaw to develop forwards⁽⁵⁾. To a certain extent, this is orthodontic in nature: The constant pressure exerted during suckling over many months is transferred to the jaw.

If infants were breastfed for one and a half to two years, as nature intended and still is the norm in many indigenous cultures, the jaw would be large enough to provide sufficient space for the wisdom teeth. This is largely infeasible in our society, which is why young people have their wisdom teeth surgically removed, usually between the ages of 12 and 20. This is not ideal, as this is the period during which young people suffer from general mineral deficiency due to a strong growth spurt, often exacerbated by unhealthy eating habits at this age. All four wisdom teeth are usually removed at once, focusing on speed, i.e. the shortest possible surgery times. Usually, the wound is not fully cleaned or sterilized (e.g. using ozone), and is then consigned to secondary healing by inserting a strip containing antibiotics and cortisone, blocking the immune system. Antibiotics are almost always given orally as well, further weakening the immune system. The operation is usually very invasive ("major surgery, major incision") and traumatic, and therefore involves severe swelling. However, this prevents the switch into the parasympathetic mode, which is necessary for effective healing. Under these conditions, the bone defect is unable to heal, which is why around 90% of all wisdom tooth operations lead to an FDOJ.

This means that, while the gum tissue and often the hard bone underneath (known as "compact or cortical bone") do heal, a cavity remains, which is either completely empty, filled with pure fat or with a mixture of fat and dead trabeculae. This is also known as "chronic fatty degenerative inflammation". The correct radiological term is "osteolysis of the jawbone". The former term "NICO" has been replaced with "FDOJ" (fatty degenerative osteonecrosis of the jawbone). This is important when communicating with radiologists, insurance providers and experts.

The formation of an FDOJ can only be avoided by strictly following the BTP Biological Treatment Protocol described here. In many cases, however, broken wisdom teeth and those in a row must also be removed, as they constitute an interference field. In the course of the removal, an FDOJ is then found behind the wisdom teeth. Dr. Volz has found a simple and logical method of differentiation: If keratinized "attached gingiva" can also be found around the wisdom tooth on the dorsal side, the wisdom tooth can be left in. In this case, the "immunological door" is closed (gingiva = ectoderm, bone = mesoderm, see also 2.1). There is only ever really enough space if the wisdom tooth is not only able to erupt, but also if there is up to 15 mm of horizontal bone behind it. Only in these cases is it possible for continuous keratinized gingiva to form. Otherwise, there is a connection between the oral cavity and the bone in the form of a hugely dirty gingival pocket. In these cases, the "immunological door" is wide open.

2D imagery is not well suited to the diagnosis of an FDOJ⁽⁶⁾. It is only with a great deal of experience that a surgeon may be able to identify an FDOJ on just an orthopantomogram (panoramic x-ray). A reliable diagnosis can be made based on a 3D recording, a DVT. When gum tissue above an FDOJ is opened, the condition can usually be detected from the outside thanks to the yellow to brown discoloration of the bone caused by LDL cholesterol deposits. The blood also glistens due to the floating droplets of fat released by opening the bone.

Taking a closer look at the histopathology of these fatty degenerative bone necrosis areas, you can see thin trabeculae of bone where the boney interconnections have been lost. The bone marrow, containing fats, shows mucoid degenerations with interstitial edema. In principle, the number of fat cells is strikingly increased.⁽¹⁾

This is chronic, silent inflammation resulting from the lack of an acute cellular inflammation reaction due to the significantly increased amount of interleukin-1 receptor antagonist (IL-1ra)⁽⁷⁾. In this case, IL-1ra acts as a masking cap, causing the immune system to fail to regulate the excessive expression of dangerous inflammatory mediators such as RANTES and FGF-2 (see below) down. The strikingly low IL-6 and TNF- α levels are an additional aggravating factor⁽¹⁾ - a sign of the fact that the immune system has not registered anything out of the ordinary!

The tissue shows fatty, degenerative and osteolytic components due to insufficient nutritional supply. Expanded intertrabecular spaces often contain small, necrotic bone fragments and fatty micro-bubbles and reservoirs of liquefied fat. These are similar to fat cysts, with an almost complete loss of the adipocyte nuclei and residual, degenerated bone marrow. An accumulation of acidic glycosaminoglycans can also be seen in the bone marrow. Small nerve fibers are another distinguishing feature in most FDOJ biopsies, located in the vicinity of degenerated, fatty tissue^(1,8). The fact that these often cause facial pain gave rise to the name NICO (neuralgia inducing cavitation osteonecrosis). Alongside IL-1ra masking, FDOJs have another disastrous characteristic: In what could be deemed a "bone infarction", a bone necrosis, the connection to vessels and therefore the connection to our body's own healing, repair and immune systems is impaired. This means that an FDOJ can barely be bettered using non-invasive therapy or medicine. At the same time, FDOJ waste products cannot be transported away, because lymphatic drainage is inactive. FDOJs do, however, have nerve vessels, which can transport toxins to the ganglia and other areas of the cen-

tral nervous system (CNS) by axonal transport very quickly, which can cause nerve pain (neuralgia) or even nerve failure! Intraosseous inflammation has readily been recorded among patients with facial neuralgia⁽⁹⁾. FDOJs always go hand in hand with significant increases in inflammatory mediators, namely regulated and normal T cells expressed and secreted (RANTES) as well as fibroblast growth factor 2 (FGF-2)^(1, 10, 11).

Both of these mediators are also always to be found in tissue in the event of severe illnesses such as ALS, MS, rheumatoid arthritis, cardiovascular diseases, breast cancer and other tumors, and are always present in extremely high concentrations^(1,10,12-17). Due to the production of RANTES and FGF-2, among other aspects, FDOJs are considered a significant cause of autoimmune diseases.

RANTES is a member of the chemotactic cytokine family (chemokines). RANTES' chemotactic processes carry T cells, dendritic cells, NK cells, mast cells, eosinophil and basophil cells⁽¹⁸⁾ to areas that are infected or susceptible to inflammation. This can promote the development of MS and Parkinson's in the CNS. The impact on mast cells increases the risk of allergies, hair loss and thyroid gland diseases.

Melanoma cells also excrete RANTES, which stimulate the growth of tumor cells. In Hodgkin lymphoma, malignant Sternberg-Reed cells produce RANTES, which trigger the chemotactic migration of mast cells into the tumor tissue⁽¹⁾. Unfortunately, at present, there is no non-invasive or partially invasive therapy that can heal an FDOJ. Only the minimally invasive, atraumatic yet radical surgical FDOJ

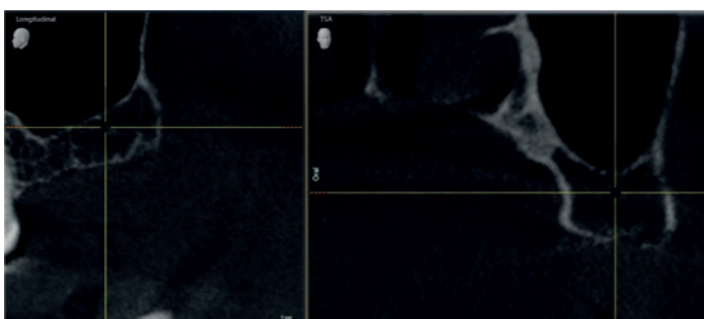


Figure 3: FDOJ on a DVT

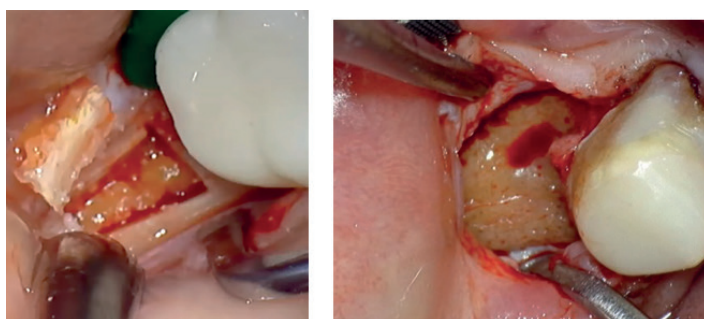


Figure 6: FDOJ in the lower and upper jaws

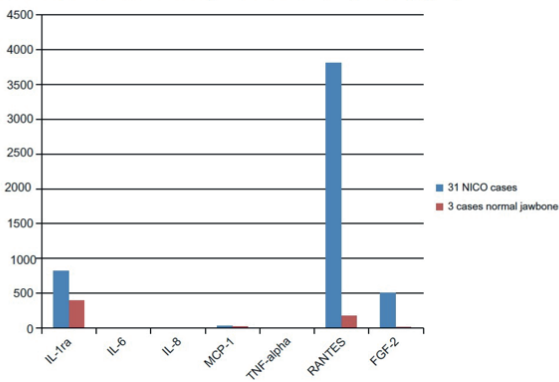


Figure 5: Cytokine distribution in FDOJs⁽¹⁾

removal as per THE SWISS BIOHEALTH CONCEPT can achieve comprehensive healing at the site, reduce the symptoms associated with it and, in the best case scenario, eliminate them entirely.

Alongside neuralgic complaints, FDOJs are particularly readily associated with symptoms related to the meridians that run through this area, that is the heart/circulation, the triple warmer and the small intestine meridians: chronic fatigue (CFS) and lack of energy (burnout), all sorts of cardiovascular complaints, suprarenal gland deficiency, weight gain, allergies, skin diseases, problems with the small intestine, autoimmune diseases and Lyme disease in particular. Among these patients, FDOJs harbour large quantities of Borrelia, Babesia and Bartonella, to whom the FDOJ tissue is the perfect environment in which to multiply and transmit their toxins into the body via nerve fibers. Particularly if Bartonella are elevated, so is the risk of infection and wound healing disorders. These patients require additional protection by means of daily antibiotics infusions for the week after the FDOJ surgery. The FDOJ tissue not only contains viruses, fungi, bacteria, parasites, FGF-2, RANTES and fat cysts, but also large quantities of heavy metals such as mercury, arsenic and lead, aluminum and, ever more frequently over the last few years, glyphosate, found in pesticides.

Treatment now entails removing all soft material of this "chronic fatty degenerative inflammation" until only hard bone substance is left and the yellow coloration has completely disappeared, with no more fat droplets floating on

the blood. The significance of the treatment is further observed by having patients keep their eyes open and observing the size of their pupils: due to the chronic nature of the so-called "silent inflammation", the patients find themselves in permanent sympathetic nervous system mode and their pupils are dilated. Once the FDOJ has been fully eliminated, the pupils become smaller, as the patients now enter a state of relaxation, i.e. they switch into the parasympathetic nervous mode. Ozone is then used as sterilizing agent and the defect is filled with A-PRF membranes and sealed with absorbable sutures (Atramat), preventing contamination by saliva. To ensure maximum safety during the clearance of the FDOJ, a method was developed by Dr. Klinghardt, which has subsequently been optimized under his guidance at the SWISS BIOHEALTH CLINIC. It involves removing material from the FDOJ during cleaning and placing it in a sterile glass vial. To check the cleaning result, the practitioner can now project the information via a sterile glass rod in different directions into the FDOJ cavity and, at the same time, use the ART (autonomous response test) by Dr. Klinghardt to test whether the cavity was also perfectly cleaned, even at a microscopic scale. If the test is positive, the surgeon has to continue cleaning and clearing out in the direction of the glass rod until the test no longer responds in any direction.

Upper jaw FDOJ: Alveolar ridge incision without vertical relief and wedge-shaped incision below as a tuber plastic in order to reduce the thickness of the connective tissue on the tuber. Complete removal of the tuber and cleaning of the area using manual instruments and the piezo tool with the diamond-coated ball-shaped tip, ozone, possibly ART-TEST, A-PRF and absorbable sutures.

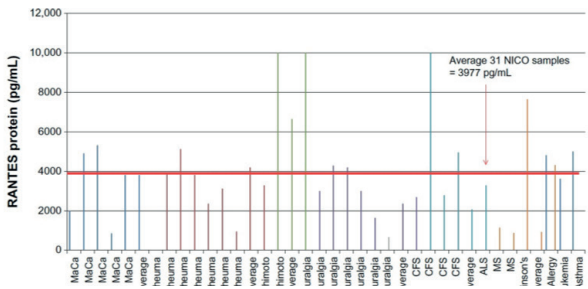


Figure 6: RANTES evidence in FDOJ tissue linked to several illnesses⁽¹⁾

Lower jaw FDOJ: Alveolar ridge incision at an angle of approximately 30° in the vestibular direction in order to protect the lingual nerve in a similar manner to the method used for wisdom tooth removal. No vestibular relief, fenestration with piezo saw, clearing of the FDOJ exclusively with piezo instruments in order to protect the nerve (piezo tool with diamond-coated ball-shaped tip). Possibly ART-TEST, filling and covering of the defect with A-PRF membranes following ozone application. A deep apical mattress suture (absorbable suture material) is placed over the covering material in order to absorb the tension and securely fix the covering membrane. The wound is then closed using a continuous suture or single button sutures.

The use of piezo instruments was introduced to the FDOJ treatment by Dr. Volz in 2013, revolutionizing it in the process, as it allows for the extremely quick, safe, gentle and, above all, complete removal of the necrotic material. Piezo is an ultrasound-based method in which the instrument vibrates/oscillates at great speed, meaning that damage is avoided in the event of potential contact with a nerve or vessel⁽¹⁹⁾. The piezo method has been used in the field of brain and spinal surgery for many years⁽²⁰⁻²²⁾.

Empty jaw sections

FDOJs not only occur in the wisdom tooth area, but also in other dental zones. They may be caused by foreign bodies such as overfilled root fillings, amalgam from fillings and root residues. However, a dry socket can also result in the formation of an FDOJ. The formation of a dry socket is countered by priming the bone with a round bur, using ozone (the strong electromagnetic field at the glass tip activates bleeding) and then protecting the socket from saliva. Saliva has a very strong haemostatic effect, which at this stage is extremely undesirable, as the socket then completely fills with saliva, thus keeping out blood. The most reliable way to fully seal the socket is by completely filling it with A-PRF membranes and / or preferably by immediately implanting ceramic implants.

Ankylotic root-canal-treated teeth

However, FDOJs are also frequently found in the sockets of ankylotically impacted teeth as the “ligament insulation layer” is no longer present and toxins can permeate the bone unimpeded. It is interesting to note here that the better and the more complex the root canal treatment is, the higher the risk of ankylosis and thus an FDOJ! The poorer

the quality of a root canal treatment and the more insufficient it is, the more likely it is that a cyst will be found. In contrast to the FDOJ, this indicates a reasonably intact immune system, as the cyst sac seals off emerging bacteria from the rest of the body and forms a kind of “prison wall”. Furthermore, the bone around the cyst sac is always very hard and well mineralized, as this increased mineralization is in turn supposed to seal off the body from the inflammation.

Therefore, even if immediate implantation is not planned, a “drilling test” should always be carried out through the socket wall, through the socket tip and into the septum. If the tissue underneath it is soft and there are fat droplets floating on the escaping blood, then an FDOJ is sure to be present and needs to be cleaned. It is often necessary to remove the entire socket wall. The fatty degenerative lacunae often spread deep beneath the adjacent teeth and only the oral and vestibular compacta of the jaw remain after cleaning or FDOJ treatment.

Towards the end of the treatment, the patient will begin to visibly relax; it is not uncommon for patients to fall asleep during the treatment. In around 50% of FDOJ treatments, patients feel a significant improvement even as they are getting up from the chair. Setting in no later than two to three days after the procedure, they experience relief, feelings of freedom, improvements on the associated meridians, etc.

Root canal treatment - extraction

Many root-treated teeth show some form of inflammation of the surrounding tissue. This can be observed particularly well with the help of three-dimensional X-ray images (DVT). The cyst at the root tip is nothing more than a kind of capsule that is formed around the infected area by the immune system itself in order to shield it from the rest of the body. Especially infected teeth often ankylose with the surrounding bone. Metabolic processes are shut down at a local level—like a kind of prison, the body walls the tooth in.

The only way to escape this chronic intoxication is to surgically remove the dead teeth. The surrounding inflamed or cystic tissues must be completely eliminated. Soft bone should be curetted without leaving any residue. The tissue is then disinfected using ozone. According to the authors Brisman et al., implants positioned next to existing root-treated teeth should be rigorously evaluated in order to avoid a possible failure due to focal infection⁽²³⁾.

When removing root-treated teeth, immunological pre- and post-treatment must be performed to ensure that the body is able to heal the wound, generate new and healthy bone and prevent infection. As a rule, extraction is always carried out as gently as possible—following the removal of the tooth, the gingiva and bone must be left completely intact. Where possible, the attached gingiva should not be removed. The ligament, the elastic fiber system that holds the root, must be completely removed, however, as the brain will otherwise not realize that the tooth has been removed and would only initiate the corresponding bone growth factors following a resorption period of a few days/weeks.

Extraction

The gingiva is carefully detached from the tooth with crescent-shaped surgical scalpel blade No. 12. Using the forceps, gentle and isostatic leverage forces are exerted on the tooth in the sense of a horizontal eight until it is loosened. There are two variants that make the extraction easier: If the tooth to be extracted is shortened a few days/weeks prior to the extraction date and is thus taken out of occlusion/no longer subjected to stress, it will grow upwards in the direction of the occlusal plane in the period prior to extraction and can then be removed much more easily. This is seen time and again during the extraction of

broken teeth and root remnants, which are, generally speaking, always very easy to remove. Another option is to start with the extraction and then, after a few minutes of applying force, leave the tooth for a while (15 to 30 minutes) and perform another planned treatment in the meantime, for example. The bleeding into the periodontal space that occurs during this time gives rise to considerable pressure on the root in the direction of extraction, meaning that the tooth can now be removed easier and with less force.

Root infracture

If the tooth cannot be removed by means of ordinary extraction (see a) above), under no circumstances, as is unfortunately still often the case, is an osteotomy to be performed. The removal of good and healthy bone using the so-called Lindemann bur in order to loosen a dead root is tantamount to physical injury and demonstrates a lack of dental skills and biological understanding. A logical method that is gentle on the tissue is root infracture, which involves the milling of a Mercedes star or a Swiss cross into the root. The root fragments are then removed bit by bit using a small lever. This method is easier to perform if slits are made along the root canal all the way down to the root tip or even slightly beyond (cave: roots close to the maxillary sinus or the nerve). This is usually very simple, as the root canal is either hollow or filled with a soft root-filling material.

Densotomy

If even the root infracture (see above) does not yet yield success, the root is then “pulverized” using a long, round bur and bored away completely. This is easier than expected because the drill rotates smoothly and evenly on the root dentine but immediately becomes very unsteady and has a “knocking” effect when it comes into contact with bone. This allows for a very precise differentiation to be made between bone and root. Here, it is helpful to work with a strong loupe and a bright light source as well as to attach the fine tip of the Surgitip® aspirator. In most cases, the root tip can be removed at some point using a fine instrument, for example the “papilla elevator”. Compared to a lever, this has the advantage that it is extremely thin and can be slid between the bone and root without causing any damage to the bone.

Separate removal of a cyst or a foreign body in the area of the root tip

These can be removed by folding the gingiva down from the socket margin, as no scars are formed here and the blood supply is not destroyed. To this end, however, the sulcus edge incision normally has to be extended over several teeth in order to be able to fold down to the root tip. Alternatively, the opening for the removal of the cyst or a foreign body in the area of the root tip (retrograde root filling with amalgam or cement, overfilled root filling, broken canal instrument, etc.) can also be made via a vertical incision in the area of the free gingiva alongside the surgical site, meaning that an undamaged periosteum is subsequently achieved over the defective area. Horizontal incisions must never be made, as the blood vessels and the meridians run vertically and their function would be impaired more than is absolutely necessary. The cyst or foreign body can now be removed by sight. Here, it is important to ensure that any bone discolored with amalgam or other metallic foreign bodies is completely removed and that any metal tattoos located in the soft tissue are cut out.

In the case of seriously ill patients, such as those with ALS, the complete removal of foreign bodies can be the difference between life and death. As we never know what state of health our patients will find themselves in ten or 20 years down the line, we must take precautions now in order to ensure that these deposits are fully removed. After the defect has been filled and covered with A-PRF membranes beforehand, the incision is then closed using very fine, continuous, saliva-proof sutures (better tension distribution compared to single button sutures and thus less scarring).

In all cases, the extraction socket is optimally cleaned, curetted and monitored for FDOJs (perform test drill), sterilized using ozone and filled with procaine. It is ensured that a complete filling is carried out with the blood clot.

Procaine is also injected into the fold by way of neural therapy. If the implant is not to be placed in the socket of the extracted tooth immediately or if there are still cavities between the implant and the socket following implantation, these are covered using A-PRF membranes made from growth factors. In the event of insufficient blood circulation (dry socket) or an opening in the maxillary sinus (Oroantral Communication = OAC) without immediate implantation, the socket should be closed in a saliva-proof and air-tight

manner with a Cytoplast/Tefgen membrane in addition to the filling with A-PRF membranes and protected against the impact of food residues.

By way of exception, the gingiva must be folded down approximately 5 mm in line with prioritization. The membrane is trimmed and approximately 3 mm is pushed under the gingiva, which is closed in the area of the papilla with single button sutures. The rough structure of the membrane is thereby positioned adjacent to the oral cavity, as this structure of the non-expanded Teflon membrane promotes the growth of soft tissue. If non-absorbable, the sutures are removed after about two weeks and the membrane after approximately four to six weeks. These can be removed very easily using a probe without the need for anesthesia.

Ozone treatment

There are various ozone devices on the market. We prefer the very powerful OZONE DTA devices, which are distributed by www.swissdentalsolutions.com. The strength is set to around seven to ten and the socket is aspirated at the same time, as the ozone should not be inhaled (exception: treatment of bronchitis) and as it can only take effect in the presence of atmospheric oxygen. At the tip of the probe, atmospheric oxygen is shot into oxygen radicals by a strong electromagnetic field; this atomic oxygen O1 has an extremely strong bactericidal, virucidal and fungicidal effect. As these oxygen radicals are very reactive, they combine with the oxygen to form ozone O3, which also has a bacteriostatic effect. The concentration at the tip of the probe is between 10 and 100 mg/ml. However, ozone is not stable and breaks down again into the now active oxygen and oxygen radicals. The sterilizing effect penetrates the bone up to a depth of 2.5 cm and is completely harmless to human cells, as neither O1 nor oxygen or ozone can harm the human respiratory chain. In the respiratory chains of bacteria, viruses and fungi, however, the presence of these three forms of oxygen results in a metabolic breakdown and thus to the death of these pathogens⁽²⁴⁾.

This provides the dentistry sector with a highly effective instrument for local sterilisation that is completely free of side effects. Herpes or oral aphthae on the palate, mucus membranes or lips can be treated very effectively with the surface probe. In most cases, this shortens the healing process from around a week to a few hours. A further positive

secondary effect is the short-term increase in blood flow due to the very strong electromagnetic field, thus meaning “dry sockets” are avoided.

PRGF, A-PRF, I-PRF

These are plasma components extracted from the patient’s blood, which are rich in growth factors and fibrin

PRGF = Plasma Rich in Growth Factors

Platelets (thrombocytes) are not only blood coagulation stimulators, but rather also contain the largest volume of human growth factors, which are bound to them. They therefore ensure that the tissue regenerates after an injury or following an operation. These growth stimulators can be used in a very specific way by separating them from the platelets or activating them together with the thrombocytes separated from the rest of the blood and introducing them to locations where growth and cell activation are to be stimulated on a targeted basis. The highly effective and side-effect-free PRGF therapy was developed in 1999 by the Spanish working group led by Dr Eduardo Anitua under the name Endoret® (Endogene Regenerative Technology⁽²⁵⁾). It is based on the activation of the patient’s own blood platelets with the aim of stimulating the tissue and accelerating its regeneration^(26, 27). This results in the shortening of the rehabilitation or convalescence period after fractures, muscle and tendon injuries and surgical procedures. Overall, the wound healing phase is shortened by the concentrated effect of growth factors and the risk of complications is significantly reduced. However, this is an open system in which calcium sulfate has to be added to produce membranes.

A-PRF = Advanced Platelet Rich Fibrin

This is a treatment which uses leukocytes and platelet-rich fibrin to promote wound and bone healing as well anabolic forces. In addition, the function of the leukocytes supports the immune response and the slow release behavior of the A-PRF has the advantage of allowing a constant release of growth factors (TGFβ1, PDGF-AB, VEGF)⁽²⁸⁾ and matrix proteins (fibronectin, vitronectin and thrombospondin1) over ten days. These growth stimulators can be used very specifically, do not require activation and can be applied at locations where growth and cell activation is to be stimulated in a targeted manner. These growth factors stimulate

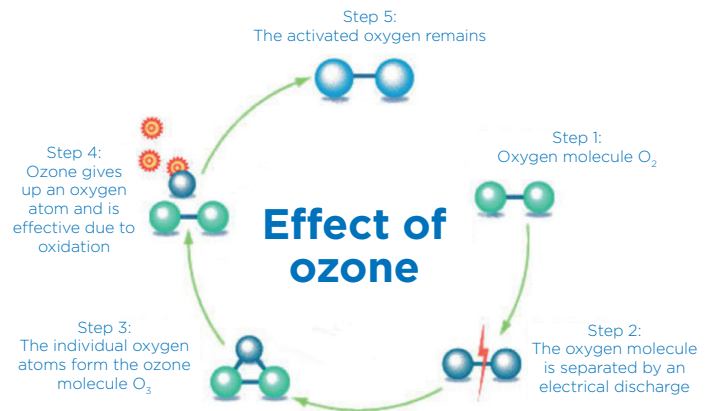


Figure 7: Effect of ozone

the fibroblasts in the tissue, which, in turn, stimulate collagen formation and hyaluronic acid, which softens the tissue. This is particularly effective where fibroblasts normally build tissue, such as in cartilage, bone, connective tissue, vessels and in subcutaneous tissue. Here again, what is involved is autologous cell extract therapy. The PRF therapy, which is likewise highly effective and free of side effects, was introduced to the market in 2009 by Prof. Joseph Choukron⁽²⁹⁾ and is patented and approved across Europe. Well over 200 scientific publications have confirmed the effectiveness and biological safety of this therapy. PRF has been shown to improve soft tissue healing and can prevent the risk of “dry sockets” following the removal of teeth⁽³⁰⁾.

I-PRF = Injectable Platelet Rich Fibrin

The injectable version of PRF, I-PRF, can be used for muscle, tendon and joint disorders, for the treatment of persistent tendon base pain (tennis elbow, achillodynia), for the treatment of injuries (muscle and tendon tears), for cosmetic and regenerative treatments of the skin and the corrective filling of scars and wrinkles, as well as for the treatment of skin ulcers⁽³¹⁾. In the SWISS BIOHEALTH CONCEPT, we prefer A-PRF, as its leukocyte content preserves the “good inflammation” responsible for tissue regeneration. A-PRF also contains 1.2% stem cells due to the slow and gentle centrifugation process. Furthermore, it is much quicker and easier to use and there is no limit to the number of membranes that can be produced without effort. Prof. Joseph Choukron has been personally teaching his techniques and concept at the SWISS BIOHEALTH EDUCATION CENTER since 2017.

Ceramic implants that meet the most discerning standards

Implants have long since established themselves as the most attractive form of dental prosthesis. They offer security and look good, while also boosting self-confidence and ensuring a greater quality of life. Implants are such a good replacement for lost teeth that they usually last longer than your own teeth. Whether it is just one tooth being replaced or several implants recreating a firm set of teeth—the material needs to function stably, neutrally and compatibly over a period of decades. The high-performance ceramic zirconia, long used in orthopaedics for artificial hip joints, fulfils these requirements like no other material⁽³²⁾. Zirconia ceramic is a white, metal-free, immunologically neutral and biocompatible material, which offers many advantages over metal⁽³³⁾. Whether it is an intolerance to titanium or general uneasiness about the prospect of having metal in your body that prompts the use of a metal-free solution—the esthetically-pleasing white ceramic implants made of the biocompatible, high-performance material zirconia are always an excellent choice and according to current studies are classified as equivalent to titanium implants⁽³⁴⁻⁴⁹⁾.

Beautiful white teeth and pink gums are an expression of health, energy, vitality and self-confidence. The ceramic

implants from SDS Swiss Dental Solutions are white through and through and come very close to the natural color of teeth, meaning they can contribute to preserving or restoring a radiant smile. In contrast to titanium implants, there are no gray tinges or annoying gray edges at the gingival cuff⁽⁵⁰⁾. Even if the overlaying gum is extremely thin or receding, the implant remains completely white. Not least for this reason, ceramic implants are ideal for use in the front teeth, in particular.

While the use of metal in the oral cavity can have a negative effect on the whole body, ceramic implants are outstanding in terms of their compatibility, as they are completely metal-free and fully biocompatible. Thanks to their optimal tissue compatibility,⁽³²⁾ the regeneration of the gingiva around the implant is very good and the gingiva even attaches to the zirconia. As ceramic allows for completely new and effective structures, the formation of bacteria and plaque^(32, 51-57) and therefore the risk of gingivitis are significantly reduced - the risk of inflammation is even lower than with natural teeth⁽⁵⁸⁾. The surface structures and the bone-adapted thread shapes of the SDS implants allow for their excellent integration and mean they can be loaded after just a few weeks. There are SDS implants for all requirements. This means that your dentist will always be able to select the perfect implant for you. What's more, your dentist can completely dispense with metal during the implant procedure, as SDS provides instruments made from the same high-tech ceramic as the implants and crowns. This also means that no traces of metal are left in the bone.

Founded by the ceramic pioneer and implantologist Dr. Ulrich Volz, SDS is today regarded as a leading innovator in the field of ceramic implants. The Swiss company boasts unique proficiency in ceramics, many years of expertise and outstanding treatment results. A key success factor is the “from the practice, for practice” concept. SDS places the highest of demands on its products - these are certified according to current standards, carry the CE mark and have also been approved by the FDA (Federal Drug Administration) since 2019.




Figure 8: PRF membranes

Ceramic implants made from high-tech zirconia

The introduction of high-performance zirconia ceramic implants by Dr. Volz revolutionized biological dentistry. For the first time, there was a biological solution for the increasing problem and the growing number of root-treated teeth. Zirconia is a material that is 100% metal-free, harder than steel and can only be machined with diamond-coated tools. Zirconia is a “fully inert material” and has no free surface electrons. It is therefore absolutely neutral, cannot bond and cannot act as an interference field. Zirconium dioxide implants combine optimum biocompatibility with perfect esthetics^(34, 59). The material can only be etched with hydrofluoric acid and has a melting point of over 2,680°C⁽⁶⁰⁾.

Zirconia might be very complex in terms of its production, but is the implant material par excellence—a fact that has now been recognized by Straumann, the global leader for titanium implants, who also introduced a zirconia implant to the market in 2014. The lifespan of a zirconia implant can be far higher than that of a natural tooth, since the implant, due to its inert surface, is less prone to gingivitis than natural teeth (see Volz, Schlömer, Sidharta, Haase, University of Ulm, 2006)⁽⁵⁸⁾, cannot be attacked by caries bacteria and does not have a nerve that could die and turn the tooth into an immunological problem.

Zirconia implants also significantly outperform titanium implants: Titanium implants have a slightly higher short-term healing rate⁽⁴¹⁾, since titanium heals by way of a chronic

inflammation and will thus also heal relatively reliably in poor-quality bone. By contrast, zirconia heals only in healthy bone. However, zirconium dioxide poses no risk whatsoever of peri-implantitis, which will occur in about 50% of titanium implants after approximately five years. Within this period, around 15% of titanium implants have to be removed as a result of peri-implantitis. In the long term, therefore, zirconia implants have a significantly better success rate than titanium implants. As well, they offer esthetic advantages⁽⁶¹⁾ over grey-black titanium and its immunological risks and corrosion behavior.^(53, 62-69)

With more than 19 years and about 20,000 zirconia implants placed (as per January 2020), Dr. Volz has by far the most comprehensive experience in this field and has developed several implant systems (including Z-Systems) that take into account the increasing know-how about this material. There is now a growing understanding of the advantages and disadvantages of zirconia (“Thinking in Ceramics”), which in turn has enabled the development of shapes and therapy protocols which eliminate—or at least reduce—its disadvantages and make maximum use of its advantages. Both the latest shapes and types of zirconia implants developed by SDS Swiss Dental Solutions AG (www.swissdental-solutions.com) and Dr. Volz’s SCC Short Cut Concept are based on this knowledge.

The main and most significant advantages of zirconia over titanium are the following:

- Zirconia is immunologically neutral, metal-free, has no free electrons, and its ivory color delivers excellent esthetic results^(70, 71). Zirconia poses no risk of peri-implantitis⁽⁵³⁾ and has therefore a significantly higher success rate in the long term than titanium.
- Soft tissue affinity: In contrast to titanium, zirconia implants⁽³²⁾ attach to both soft tissue (gingiva) and bone⁽⁷²⁾. As early as 20 years ago, Dr. Dr. Hans Rudelt (University of Hamburg - Eppendorf in cooperation with Tokyo University) was able to prove this by means of histological examinations of human material preparations sampled after an implant service life of 20 years. The research groups around Prof. Kniha from Munich⁽⁷³⁾ and Prof. Dr. Josep Oliva Damés from Barcelona also demonstrated this beyond any doubt. This affinity supports the attached gingiva, prevents bacteria from penetrating into the area between implant and tissue and - for the first time in the history of dentistry—not

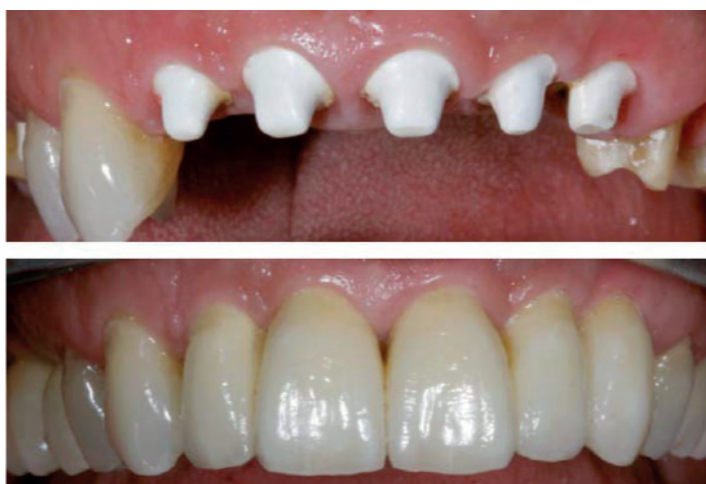

Figure 9: Ceramic implants with prosthetic restoration



Figure 10: ceramic implants from SDS Swiss Dental Solutions

only bone grafts but also ceramics can be used to replace lost bone. Until now, defects always had to be rebuilt with new bone, since soft tissue and esthetics depend on the bone available.

- However, since soft tissue also attaches to zirconia and thus “follows” this material, esthetics can, in many cases, be restored without the need for bone augmentation. With titanium implants, the entire implant must, in any case, be surrounded by at least 1 mm of bone in the mandible and at least 0.5 mm of bone in the maxilla⁽⁷⁴⁾. With zirconia implants, there is a flowing and variable transition, since both bone and gingiva attach to ceramics. Volz’s postulate: Whenever ceramics are in contact with bone, ceramics will act as an implant. Whenever ceramics are in contact with the gingiva, ceramics will act as an abutment. Titanium implantology tries to make use of these properties to some extent by placing zirconia abutments on titanium implants and recommending that they never be removed, as this

might destroy the bond created between the zirconia and the gingiva (“One Abutment, One Time”).

- The lack of ductility of zirconia ceramics has another major advantage: In contrast to titanium, which is a highly ductile material, ceramic implants are anchored in the jaw-bone in an extremely rigid and immobile fashion. As a result, any thin bone tapering off around the implant is not resorbed. In many cases, bone augmentation will not be necessary, or the implant can be placed in narrower bones than with titanium. In addition, it was demonstrated that in the event of buccal dehiscence, zirconia implants will heal significantly better compared to titanium implants⁽⁷⁵⁾.

Zirconia implants have been available as two-piece implants for all indications since 2013. Immediate implant placement with one-piece zirconia implants has proven to be the optimum solution for single-rooted teeth.

Over 60 scientific publications available on PubMed corroborate the successful placement of zirconia implants. In summary, the study by Apratim et al. from 2015 states: “Literature search showed that some of the properties of zirconia seem to be suitable for making an ideal dental implant, such as biocompatibility, osseointegration, favorable soft tissue response and esthetics due to light transmission and its color”⁽⁵⁹⁾.

Immediate implantation in line with Dr. Volz’s SCC Short Cut Concept

Replacing a diseased tooth in a single session with a ceramic implant and an immediate temporary crown constitutes a unique opportunity and a technique that should be applied whenever possible. It is difficult to understand why an extraction wound, which usually involves a large loss of bone and gingiva, should first be left to heal, making it necessary to then first augment the lost bone before implant placement is even possible. In addition, osteogenetic activity is highest immediately after extraction, comes to a complete standstill after a few months and needs to be reactivated again. Since the tooth socket (the extraction alveolus) of the removed tooth will be filled with new bone anyway—as the stem cells contained in the blood know exactly where to form bone and gingiva—it makes a great deal of sense to place the implant at exactly this particular point in time, so that the new bone will automatically grow around it. Titanium implants heal by way of a chronic inflammation by

releasing TNF- α and IL-1 β —similar to the way a foreign body in the skin is encapsulated by connective tissue (bone is a special type of connective tissue). Therefore, immediate implantation with titanium implants is usually very risky and can lead to severe infections with enormous bone loss. Since zirconia—an oxidized and thus completely inert material—does not have any free electrons, no infections will occur if THE SWISS BIOHEALTH CONCEPT is observed. In the worst case, the implant will not integrate with the bone (osseointegrate), but no bone will be lost. In most cases, the extremely aggressive thread in the lower part (only present in SDS implants) makes it possible to retighten the implant. In all probability, this procedure will be successful once 35 Ncm is reached again.

This was proven by a study conducted by Dr. Volz in cooperation with Prof. Dr. Dr. Ralf Smeets and doctoral student cand. med. dent. Leon Neuhöffer at Hamburg-Eppendorf University. This prospective immediate ceramic implant study was the biggest of its kind and involved 112 immediate implants using one-piece implants which, in nearly all cases, were immediately restored with long-term temporaries (material: Luxatemp[®]) and firmly cemented (Durelon[™]).

The resulting bone loss amounted to only 0.7 mm on average, which corresponds to the average bone loss associated with a late implant, i.e. the placement of an implant in “healed bone”, where 1 to 10 mm of bone have already been

lost. The “Pink Esthetic Score”(PES) achieved a value of 12.3 out of a maximum possible 14 points, which, in most cases, resulted in an increase (!) in gingival tissue.⁽⁷⁷⁾

Sick teeth can cause severe chronic diseases—but until now, removing these teeth took a heavy toll, resulting in loss of bone and gingiva, esthetics, comfort, time, money and ability to socialize. Thanks to their unique Dynamic Thread[®] design, SDS Swiss Dental Solutions’ one-piece ceramic implants are suited for immediate replacement of extracted teeth - even in the posterior teeth region - in almost all cases. A temporary restoration with fixed and esthetic plastic crowns is always possible, at least in the visible area. As a result, patients will usually receive fixed and esthetic teeth on the same day and can resume their normal social activities. Nevertheless, we recommend a postsurgical resting period of 3-4 days to provide the immune system with the energy required for healing (“My BIOHEALTH Week”).

A smart integration of basic immunological principles according to the BTP Biological Treatment Protocol within THE SWISS BIOHEALTH CONCEPT will allow for an activation of the immune system and an acceleration of wound and bone healing and ensure that patients not only suffer neither pain nor swelling, but also look and feel better as early as the first postoperative day.

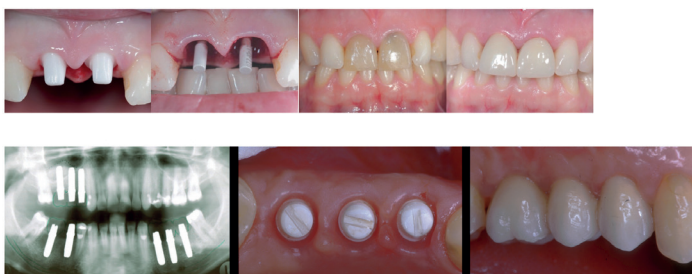

Figure 11: Dr. Volz was able to demonstrate the outstanding esthetic properties of ceramics by means of his first eight prototypes implanted as early as 2000. These implants remain in situ even today (2019) without any bone loss having occurred.

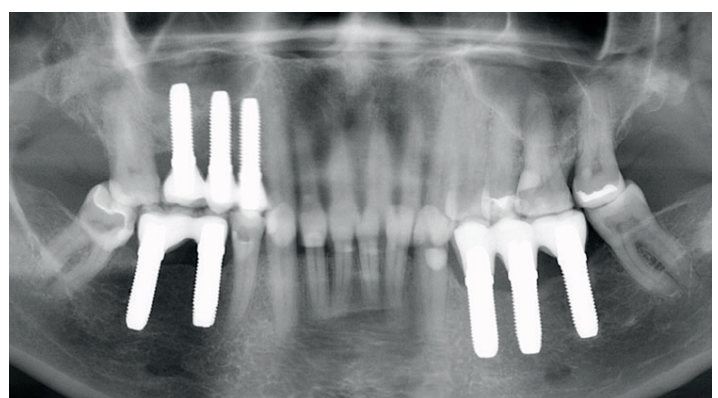


Figure 12: OPG x-ray taken in March 2019 showing the absence of bone loss around the eight implants.

By contrast, the usual tooth removal sequence, three to four months healing, 3D X-ray, possibly bone augmentation (= additional five months lost), covering the implant site with a removable temporary denture and a fixed crown restoration after another two to six months - would be equivalent to taking a (an expensive) “detour”.

Even the slightest stimulation of the immediate implant by the tongue encourages tissue metabolism and activates the meridians running through the rows of teeth. This “principle of stable restlessness” is known from orthopedics and is another reason why it makes sense to replace every tooth that has to be removed with an implant, because otherwise not only the “meridian would atrophy”, but bone and gingiva in the respective area would also degrade as a result of a reduction or complete cessation of metabolism in this area (immobilization osteoporosis).

Dentists consider it normal to extract teeth and to then let these regions “heal”, which means nothing other than that letting the papilla, gingiva and surrounding bone collapse, thus irrevocably and significantly compromising the esthetic appearance. It is astonishing to see that this approach is still adopted—to the detriment of patients—as it neglects the principle of “physical integrity” resulting in patients having to accept massive losses in esthetics and bone volume frequently involving the necessity of later bone augmentation. Irreversible disadvantages of this type can only be prevented by placing immediate implants, whereby zirconia performs significantly better than tita-

nium: It is not only neutral and biocompatible and therefore less susceptible to infections, but can be shaped in a more voluminous fashion in the upper section of the implant, the so-called tulip, which emerges from the gingiva. The surrounding gingiva will integrate with it, sealing the cavity and will in turn be supported and retain its volume by integrating with the ceramic implant.

Immediate implant placement will result in the tooth socket healing faster and better than if no implant was placed, and the implant will heal faster in the extraction socket because the extraction will trigger the system’s “healing and bone formation” process. Therefore, immediate implant placement according to the SCC protocol is considered the best and most biological “socket preservation” method.

Late implantation

Late implantation differs from immediate implantation in that the bone has already “healed”. The focus here is on (re)-generating a healthy, widely attached gingiva during implant placement. An implant is only placed in a “flapless” fashion if the attached gingiva is very wide and if there is a seam of at least 5 mm of attached gingiva around the implant after punching or after “flapless surgery”. Otherwise, a so-called wave-shaped incision is made which follows the oral position of the implant tulip in the shape of a wave. The attached gingiva thus obtained from the cervical area is shifted in a vestibular direction and supported by the high tulip of the SDS implant, ensuring the growth of a broad seam of attached gingiva after healing. Thanks to the drilling protocol for SDS implants in conjunction with the “Dynamic Thread” developed by Dr. Volz, implants will—for the first time— have the same primary stability (max. 35 Ncm insertion torque) in all bone classes. This is extremely important when it comes to ceramic implants, since one of the disadvantages of ceramics is that they do not dissipate the frictional heat generated when the implant is screwed in, and because there is a risk of bone overheating and denaturation when the implant is screwed into hard class I bone⁽⁷⁸⁾. This is particularly relevant when it comes to cortical bone, which has poor blood supply and can therefore die and resorb very quickly when compressed. For this reason, 0 Ncm is the optimum torque to be applied in the cortical bone area. We virtually always achieve this torque when placing immediate implants through the alveolar gap and have therefore not observed any bone loss in that area⁽⁷⁷⁾.




Figure 13: “Tulip”

The drilling protocol provides for an over-extended drilling in hard bone, thereby creating cavities between the implant core and the bone, which, on the one hand, reduces friction and thus heating of the bone, and on the other hand, creates space for blood and growth factors (bioactive containers, stem cell niches, healing chambers). This triggers callus formation, resulting in the faster growth of higher quality bone⁽⁷⁹⁻⁸¹⁾, namely vascularized lamellar bone (10-50 μm per day). If the implant is in contact with the bone (independent of the implant material), the bone will switch to poorly vascularized and slow (1 to 3 μm per day) appositional growth^(82, 83). In soft bone class III and IV, the drilling protocol also always ensures an insertion torque of more than 35 Ncm, which means that these implants can usually also be immediately provided with long-term temporaries—a huge advantage for patients. However, when drilling in soft bone, it is always important to check whether there are grease drops floating on the blood. This would be a sign of an FDOJ, which must be completely removed during implantation and then closed with the implant as if by a cork.

Bone augmentation measures

Bone augmentation measures should always be performed in the most atraumatic, minimally invasive and tissue-conserving fashion possible in order to avoid damaging the blood flow and losing esthetics. Even though bone aug-

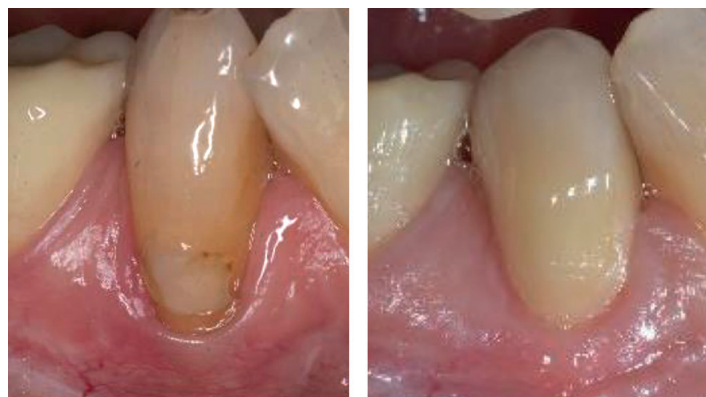

Figure 14: Left-hand side: the diseased tooth to be removed, right-hand side: the final crown on the SDS immediate implant with significantly better, healthier and more voluminous gingiva

mentation measures can virtually always be avoided by means of immediate implant placement according to the SCC protocol, augmentation is often necessary in patients who have undergone alio loco extraction:

- Widening of the alveolar ridge: the “Angle Modulation Technique developed by Dr. Ernst Fuchs”⁽⁸⁴⁾ is a method for a bone spread during which the gingiva is not folded down. Instead, the piezo technique is used to make vertical and sagittal bone incisions below the intact periosteum. After some gentle stretching and spreading of the gingiva, this technique will result in a so-called “greenstick fracture” leading to the release of growth factors and triggering callus formation. The cavity between the implants must bleed in and must not be filled with bone replacement material, as this would disturb the extremely fast callus formation inside the “bioactive container” created. However, the cavity can/should be filled with A-PRF membranes.

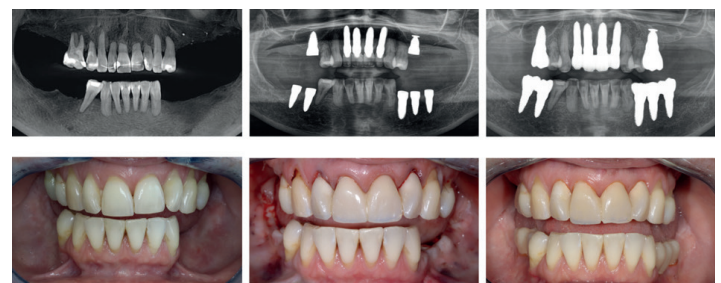


Figure 15: Upper left: The four anterior teeth with resorbed (dissolved) roots, which were replaced with SDS immediate implants and restored with final ceramic crowns (upper row). Bottom left: The clinical starting point with exposed tooth necks on the lateral incisors. Middle: The long-term temporaries on the day of implantation, with the temporaries ending at the “target gingival level”. Bottom right: More than 1 mm of gingiva has grown up to the edge of the long-term temporaries. The SCC Shortcut Concept has clearly resulted in a significantly healthier and more esthetic outcome than the initial situation.

- Internal sinus lift: Here, drilling is only carried out to just below the cortical maxillary sinus floor which, using appropriate instruments, is then mobilized in a cranial direction together with the Schneiderian membrane situated above it. Since the flexibility and (one-dimensional) extensibility of the membrane amounts to about 132 %⁽⁸⁵⁾, approximately 2.5 to 4.5 mm bone height can thus be gained⁽⁸⁶⁾.

- Intralift™: If a large amount of bone is missing in the maxillary sinus area, this particularly gentle procedure can be used to build up bone easily and safely in some cases. A special set (SCA® = Sinus Crestal Approach) is used to open the bone all the way up to the mucosa of the maxillary sinus (Schneiderian membrane) without damaging it. We prefer our specially developed method - namely an internal lift using Summers osteotomes - which has the advantage that the Schneiderian membrane is additionally protected by a bone flap. The Acteon™ piezo method is then used to pump sterile Ringer's solution via a "trumpet" and spread by means of piezo vibrations, into the area between the maxillary sinus floor and the mucous membrane, resulting in its detachment. Now the A-PRF and the patient's endogenous bone can be introduced into the newly created space via the small bore hole. Unfortunately, however, this method only works with U-shaped cross-sections of the maxillary sinus, since tension from the Schneiderian membrane must never be applied to the augmentation material and/or the bone. This would lead to expulsive forces being exerted and a potential loss of the augmentation material and/or the implant. This technique is also indicated if the Schneiderian membrane can only be removed with difficulty and is strongly attached to the sinus floor bone. This can be determined very easily beforehand, since this particular characteristic is always analogous to the condition of the gingiva: if it can be easily detached, the Schneiderian membrane will be easily detachable as well (and vice versa).

- External sinus lift: Here, the intervention area will be defined by means of a straight alveolar ridge and gingival margin incision running over the maxillary tuber without vertical relief, and a piezo saw used to cut a window. The cavity is filled with a mixture of A-PRF membranes and autologous bone obtained by means of the safe Scrapper™ prior to the window cutting. Additional bone may also be harvested during the FDOJ surgery in the adjacent wisdom tooth region, which is usually performed in a first surgical step. However, the bone harvested must be carefully freed from any degenerative fatty parts. The bone should never

be stored in a sterile saline solution prior to its use, as this will lead to bone cell destruction. It is better to store PRF membranes in exudate or patient blood. If at all possible, an implant should always be placed immediately according to the tent-pole principle in order to support the Schneiderian membrane cranially and prevent a collapse of the cavity⁽⁸⁷⁾. This can be optimally achieved with the sinus implant developed by Dr. Volz, which has a wide plate at its tip that will gently and securely support the mucosa and thus significantly reduce the risk of perforation.

In addition, this enables the creation of a larger cavity, since the implant now not only acts as a tent pole, but also has a kind of umbrella at its tip. An external sinus lift will be always performed in the event of difficult or unsafe conditions in the maxillary sinus. This is the safest method, as it provides a direct view of the intervention area. Hundreds of interventions of this type have demonstrated that this revolutionary implant design results in healthy new callus being formed without secondary materials - whether of synthetic, human or animal origin - becoming necessary.

This constitutes another milestone in biological dentistry: New, endogenous bone always performs best in terms of angiogenesis, i.e. formation of new blood vessels, this being the main criterion for whether bone quality and quantity will be preserved in the long term⁽⁸⁸⁾. Bone replacement material will in principle always represent an obstacle to new bone formation, as it reduces the size of the remaining cavities and thus the possibility of vascularization. Apart from that, a loss of the implant would lead to a "restitutio ad integrum", i.e. a complete regression to the initial situation. If secondary materials are used during implant placement and the implant is lost, the mucosa of the maxillary sinus tends to usually get irreversibly damaged and compromised for the rest of a patient's life.

Systemic conditions

- A strong immune system: The immune system can be strengthened by taking supplements such as D3, K2/mk7, magnesium, zinc, Omega-3 fatty acids, vitamin C, by following an optimized, sugar-reduced alkaline diet and by abstaining from harmful habits such as smoking, heavy drinking and excessive use of mobile phones, while reducing EMF exposure in general.

- A strong ability to form bones: Again, vitamin D3, K2/mk7, magnesium, zinc, Omega-3 fatty acids and the osteoclast blocker aspirin (acetylsalicylic acid) make a major contribution to strengthening our ability to form new bone.

Most importantly, the parasympathetic mode needs to be activated and the sympathetic mode inhibited. This is achieved by the intake of vitamin D3, which has an anti-depressant effect and thus relaxes and brightens the mood, and an alkaline diet, alkaline baths and infusions. In addition, patients should refrain from working for at least one day prior to and at least 4 days after surgery, reduce EMF - including microwave radiation and receive Procaine as part of their IV infusion during each check-up appointment.

Local conditions

- Reduced bad inflammation (associated with multinuclear giant cells): This reduction is achieved by IV administration of cortisone and antibiotics and by taking vitamins D3 and C as well as acetylsalicylic acid.
- Activated good inflammation: Good inflammation, which results in tissue formation (bone and gingiva), needs to be activated by means of the leukocytes contained in A-PRF and by means of atraumatic, minimally invasive, but radically clean surgical interventions.

- Reduced contamination by breath and saliva, etc.: This is achieved by adding metronidazole to the augmentation material or the membrane. Furthermore, the bone can be stimulated and the bleeding activated by “refreshing” the bone. The oversized preparation prescribed by the biological SDS drilling protocol enables the growth of stem cells and the creation of bioactive containers and healing chambers. The same effect is achieved in the area of the cortical bone by reducing it in terms of volume, i.e. by preparing the socket in an oversized fashion.

The extracellular matrix will improve as a result of traction relief achieved by using apical mattress sutures, as well as by the creation of cavities under the periosteum and Schneiderian membrane, and by leaving the sutures in place for 3-6 weeks (monofilaments: Atramat). Spacers can be placed by means of screws, plates, the Choukroun Fast System or the BISS Bilateral Implant Stabilization System developed by Dr. Volz, or in an automated way by using implants with the wide SDS Tulip, the sinus disk or the disk abutments, etc. If blood flow is to be preserved (Mammotto’s Law), the cortical bone must not be compressed in any way, since this bone—which has poor blood flow by nature—would be additionally compromised.

The aforementioned BONE MANAGEMENT protocol represents the Holy Grail of biological dentistry, so to speak, since all measures serve only one purpose: to build up healthy and well vascularized endogenous bone and keep it healthy for life! This can be done mechanically by means of SDS implants in general and in particular. From a bio-immunological point of view, all preparatory, accompanying and follow-up surgical intervention measures described here in



Figure 16: SDS Swiss Dental Solutions implantation set

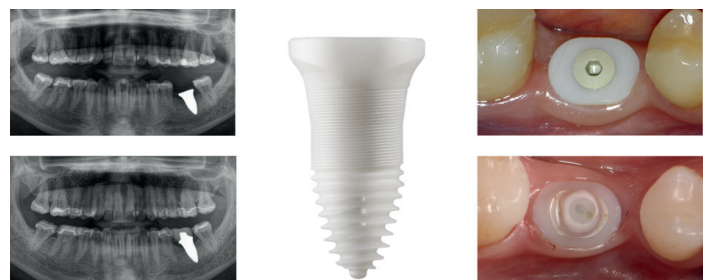

Figure 17: Oval implants from SDS Swiss Dental Solutions

THE SWISS BIOHEALTH CONCEPT serve this one purpose. Therefore, all the minute pieces making up the mosaic of this concept have a deeper meaning and should never be ignored or, worse, disregarded!

In order to avoid slitting the periosteum, which entails a destruction of many blood vessels and damaging of meridians as a result of the long and deep horizontal slit, it is essential to use the “brushing technique” developed by Prof. Alain Simonpieri. Its purpose is to stretch the gingiva during bone augmentation measures. During this procedure, the intrinsically rigid periosteum is brushed with the various tools contained in the “brushing kit”, leading to a vertical separation of fibers without blood vessels being destroyed or meridians damaged. This technique is based on the finding that the periosteum, which was originally thought to be non-elastic, consists of millions of rubber fibers which are vertically bonded together and which are separated from each other during the brushing process. After a few minutes of brushing, the initially rigid gingiva can be stretched by up to 1.5 cm. Patients will experience no pain or swelling, since no blood vessels or meridians are damaged. Prof. Simonpieri has been personally teaching this revolutionary technique in workshops held at the SWISS BIOHEALTH EDUCATION CENTER since 2018.

The apical mattress suture was further perfected by Simonpieri and Choukroun, and represents an extremely simple and safe technique to generate keratinized “attached gingiva” purely by using a special suture technique in combination with the brushing technique and A-PRF membranes, without a so-called “free mucosa transplantation” being performed.

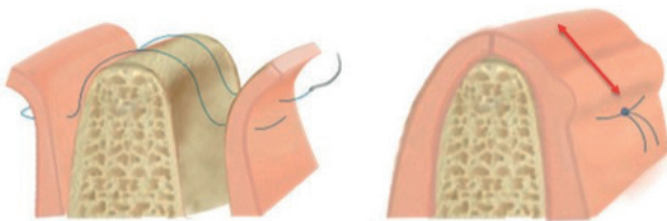


Figure 18: apical mattress suture

Always starting at the facial aspect, the resorbable (!) suture (preferably Atramat®) is placed by inserting the needle through the periosteum and along the bone in an oral direction. From there, to prevent the suture from tearing, the needle is inserted again in a facial direction at a distance of 2-3 mm in order to exit the gingiva 2-3 mm from the insertion site. The suture is now tightened with a slow and even pull to prevent the suture or gingiva from tearing. This pulls the periosteum towards the bone at the level of the puncture site and removes any traction from the incision area. As a result, keratinized “attached gingiva” will develop between this point and the incision area. This technique must be used for all sutures to avoid traction on the incision area and thus the risk of dehiscence with subsequent infection. For this reason, the surgeon must exert a strong pull on the lip in the intervention area at the end of each intervention in order to ensure that no traction is transferred from the lip or “free gingiva” onto the incision area.

This technique is also suitable for treating dehiscences on natural teeth in a fast, simple and safe fashion by first detaching the gingiva with a gingival margin incision and then flapping it open in an apical direction as a “full flap”. The brushing technique is then used to stretch the periosteum, which is subsequently lined with several layers of A-PRF to introduce growth factors and stem cells into this area. In a next step, an “apical mattress suture” is applied in each interdental space and the gingiva is closed with traction-free single button sutures or so-called esthetic sutures as used by Dr. Volz. In very rare cases, for example in the event of a substantial bone defect resulting from an extraction involving a very large cyst, infection or FDOJ, which cannot be filled and restored with the largest diameter SDS implant in a stable fashion, or in the absence of a vestibular lamella or in the event of extremely thin bone (less than 2 mm) in the sinus region, we have so far been dependent on the use of bone. If bone cannot be obtained in sufficient quantity from the patient, we use human donor bone. This type of bone is obtained from femoral heads removed and replaced with implants during hip joint surgeries. It is therefore not cadaver bone, but bone from living donors. This bone is processed into granules, completely demineralized and cleaned of all organic matter, which means that there is no risk of infection. The safety of this bone is additionally guaranteed by blood tests carried out on the donors for all conceivable diseases.

Every medium or medium rare steak, every blood bag and every handshake carries a risk of infection, which is a million times higher. This particular material is the only one that can actually lead to the formation of new and living bone. If we were conducting an organ transplant, we would always give preference to human organ donors and never consider transplanting the heart of a cow or a monkey.

The “dome technique” developed by Simonpieri and Choukroun in 2018 is another promising new technique. It consists of introducing a flattened and folded equine collagen sponge into the maxillary sinus in such a way that the rather stable structure ends up creating a “dome”. First results show that within a few weeks, a stable bone layer starts growing along this collagen membrane, thus shaping and maintaining a cavity in the maxillary sinus.

By hopefully mid-2020, an entirely new and unprecedented system will close the last gap and enable one-session implantation even in the most hopeless situations, namely the so-called BISS BILATERAL IMPLANT STABILIZATION SYSTEM developed by Dr. Volz in November 2018. This system enables the safe stabilization of any conventional SDS implant in any defect, no matter how great, promoting the integration of new bone with the implant according to the “Tent pole umbrella principle”. The first 20 pilot surgeries in 2019 were exceedingly successful and promising in terms of this system’s broad and reliable applicability.

Final restoration

The final restoration will of course always be made with zirconia ceramic and will be preceded by a temporomandibular joint analysis and, possibly, gnathological therapy. It is of the utmost importance to compensate for any previous

loss of bite height. Even a minor loss of bite height (and reduced jaw movements / masticatory muscle activity) will reduce cerebral blood flow^(92, 93) (1 mm loss of bite height resulting in 50 % less cerebral blood flow!) as well as venous outflow which is immensely important for detoxification. This is due to the fact that a loss of bite height always leads to a compression of the temporomandibular joint which is located in direct proximity to the large vessels and “pinches” them off. This is not a pathology, but a principle intended by evolution: Once a human being has fulfilled its reproductive role, it must age and die as quickly as possible so that it does not unnecessarily burden the ecosystem. This process is triggered by the loss and wear of teeth. Of course we have come to reject this principle, opting instead for anti-aging measures of all kinds and striving for longevity, because we would like to live as long as possible, maintaining our health and quality of life to the greatest extent possible.

II- and III-surface defects should be treated with ceramic inlays, e.g. based on the CEREC procedure, which has the advantage of allowing the restoration of defects in one session, once old fillings or caries have been removed. This means that patients do not have to come back for additional appointments. Furthermore, the risk of temporary loss, fracture of tooth cusps and pulp infection is reduced. Crowns and bridges are restored with zirconia and fixed with glass ionomer cement (Ketac™)—a fully biocompatible material. Any excess material can be easily and reliably removed en bloc during the curing phase. A newer approach involves making sure that the surfaces which are in contact with the papilla are made of pure zirconia and neither polishing nor overlaying them, but rather irradiating them with 20–50 µm of corundum at 1.2 bar. Gingival tissue will attach to it in the same way as it attaches to the implant margin and become perfectly stabilized, which leads to an even better result in the long term. However, patients should then no longer destroy this bond by flossing their teeth. The rapid development of so-called monolithic zirconia restorations with entire crowns made of colored zirconia is facilitating this approach. During the impression stage, no retraction cords should be inserted under any circumstances, since they—as their name suggests—will lead to retraction, i.e. loss of gingiva. This outdated technique dates back to the last millennium and was used with teeth and implants ground by means of tangential preparation. The retraction cord destroys the bond between the tooth or implant and the gingiva during insertion and is only used

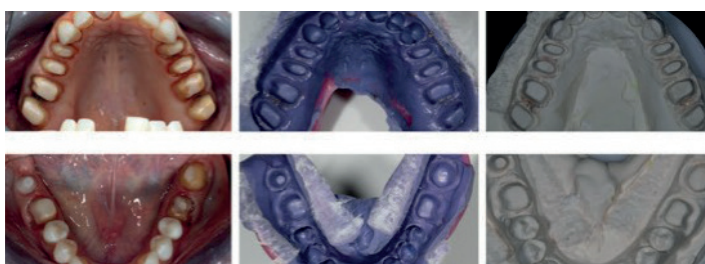

Figure 19: Preparations, impressions and plaster model making

to take an impression of subgingival preparations. Subgingival preparations, in turn, are used to compensate for the retraction caused by the retraction cord. The retraction cord is therefore the solution to a problem caused by the retraction cord. If the retraction cord is simply omitted, as Dr. Volz has been putting forward for many years, no retraction will occur and preparations can be made at gingival level (equigingivally) without any risk whatsoever. This means that impressions can be taken safely and easily without using a cord, creating perfectly shaped restorations.

Zirconia implants are placed as described in the prosthodontics manual (www.swissdentalsolutions.com), taking account of the following important principles: Reduced occlusal contacts need to be created, since implants, unlike natural teeth, are not suspended in a fibrous apparatus and therefore do not give way under load. If crowns and bridges on implants had the same strong occlusal contact as natural teeth, they would be subjected to much greater loading. This can be examined very easily: The occlusion foil—which has a thickness of approximately 10 µm—should only get stuck when the patients bites firmly, but not when there is only light contact in the area of implant crowns.

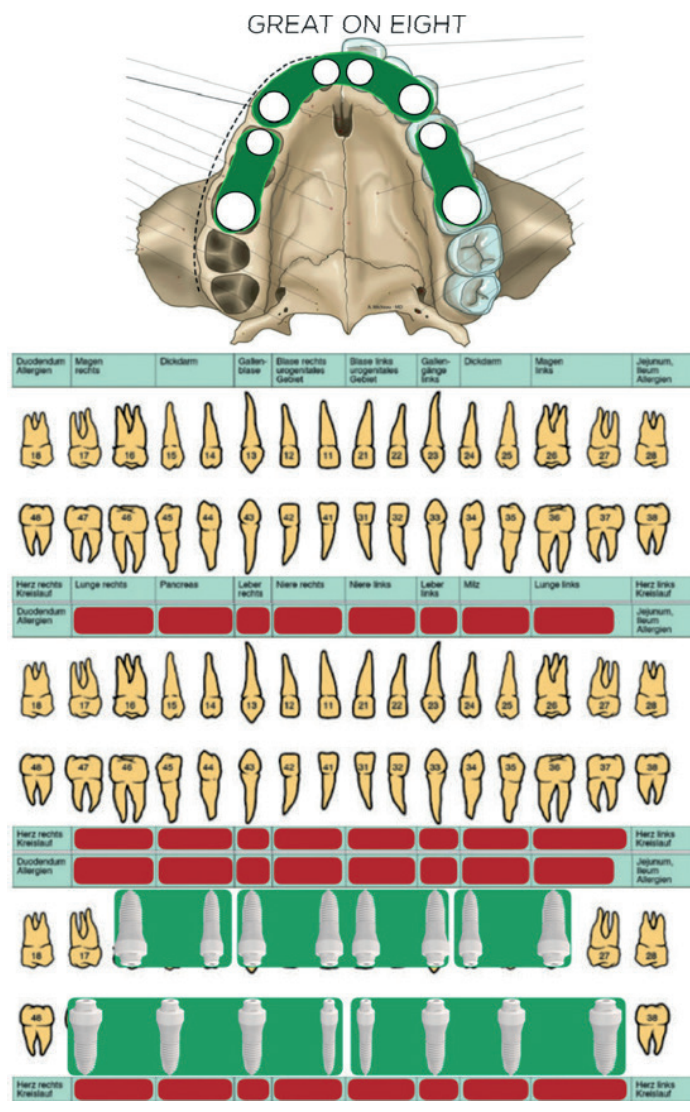


Abbildung 27: „Great-on-eight“

Splinting

For the same reason, implants are never splinted with natural teeth, but always with other implants, since fractures are only known to occur on single-tooth implants. Splints must never be placed across symphyses, as this might result in the patient suffering from tension, headaches and migraines. The symphyses (lines of junction) are located in the median line of the mandible and in the area of the maxillary canines. This is why large, splinted maxillary implants are separated by the median line. In the mandible, they are made up of an anterior segment and two posterior segments. Therefore, 8 implants (“Great on Eight”) will always be required for the restoration of an entire jaw, preventing a blocking of the symphyses and, at the same time, activating all meridians. A PEEK restoration is only indicated if a splinting of the symphyses cannot be prevented as a result of the number and position of the implants. We do, in principle, recommend that all materials remaining permanently in the patient be tested in advance with the ART technique developed by Dr. Klinghardt.

Dental hygiene

Once the restoration has been completed, patients are advised to only brush their teeth, ceramic crowns and ceramic implants with a soft toothbrush, using healthy, fluoride-free toothpaste. Under no circumstances should they use dental sticks, interdental brushes, oral irrigators, superfloss or normal dental floss, as these would destroy the firm bond between the zirconia ceramic of the crown or implant and the gingiva. This theory, postulated by Dr. Volz many years ago, was confirmed when the American Dental Association withdrew its recommendation of dental floss in October 2017!⁽⁹⁴⁾ In addition, we recommend the so-called

“oil-slurping” or “oil-pulling” advanced by Dr. Karach, preferably with virgin coconut oil in the morning before brushing the teeth. Furthermore, it is extremely important to keep all micronutrients at a high level by regularly taking DAILY USE and, in times of stress, BASIC IMMUNE, as gingivitis is always a symptom of micronutrient deficiency⁽⁹⁵⁾ and not of inadequate dental hygiene.

It goes without saying that dental hygienists or prophylaxis assistants must only remove and polish superficial concretions and plaque when performing regular professional dental cleaning. Under no circumstances should scalers and curettes be introduced under the gingiva, as they would destroy the firm bond created. It is much more effective to measure 25-OH vitamin D3 levels (storage vitamin D3 in the blood) instead of determining the SBI (sulcus bleeding index) or the PI (plaque index). In 2017, a simple vitamin D3 chairside test became available that makes it possible to determine vitamin D3 levels in just 15 minutes.

References

1. Lechner J, Baehr V v. RANTES and fibroblast growth factor 2 in jawbone cavitations: triggers for systemic disease? *Int J Gen Med*. 2013;6:277–90. doi:10.2147/IJGM.S43852
2. Mutter J. *Gesund statt chronisch krank!: Der ganzheitliche Weg: Vorbeugung und Heilung sind möglich*. 3rd ed. Weil der Stadt: Fit fürs Leben Verlag; 2014. 456 Seiten. (Gesundheit).
3. Mutter J, Klinghardt D. *Amalgam: Risiko für die Menschheit; Quecksilbervergiftungen richtig ausleiten, neue Fakten und Hilfe, auch nach der Amalgamentfernung!* 3rd ed. Weil der Stadt: Fit-fürs-Leben-Verl. in der NaturaViva-Verl.-GmbH; 2013. 169 Seiten. (Gesundheit).
4. Warwick D, Young M, Palmer J, Ermel RW. Mercury vapor volatilization from particulate generated from dental amalgam removal with a high-speed dental drill – a significant source of exposure. *Journal of Occupational Medicine and Toxicology*. 2019;14(1):22. doi:10.1186/s12995-019-0240-2
5. Wang X-t, Ge L-h. Influence of feeding patterns on the development of teeth, dentition and jaw in children. *Beijing Da Xue Xue Bao*. 2015;47(1):191–5. chi.
6. Lechner J. Validation of dental X-ray by cytokine RANTES - comparison of X-ray findings with cytokine overexpression in jawbone. *Clin Cosmet Investig Dent*. 2014;6:71–9. doi:10.2147/CCIDE.S69807
7. Arend WP. The balance between IL-1 and IL-1Ra in disease. *Cytokine Growth Factor Rev*. 2002;13(4-5):323–40. doi:10.1016/s1359-6101(02)00020-5
8. Lechner J, Bouquot JE, Baehr Vv. *Histologie und Immunologie der kavitätenbildenden Osteolysen des Kieferknochens: Orale und systematische Manifestation einer Maxillo-Mandibulären Osteoimmunologie ; pathomechanismen chronischer Entzündungserkrankungen*. 1st ed. München: Selbstverl.; 2015. 320 Seiten. (Kavitätenbildende Osteolysen des Kieferknochens; vol. / J. Lechner ; 2).
9. Bouquot JE, Roberts AM, Person P, Christian J. Neuralgia-inducing cavitation osteonecrosis (NICO). Osteomyelitis in 224 jawbone samples from patients with facial neuralgia. *Oral Surg Oral Med Oral Pathol*. 1992;73(3):307-19; discussion 319-20. doi:10.1016/0030-4220(92)90127-c
10. Lechner J, Baehr V v. Chemokine RANTES/CCL5 as an unknown link between wound healing in the jawbone and systemic disease: is prediction and tailored treatments in the horizon? *EPMA J*. 2015;6(1):10. doi:10.1186/s13167-015-0032-4
11. Lechner J, Rudi T, Baehr V v. Osteoimmunology of tumor necrosis factor-alpha, IL-6, and RANTES/CCL5: a review of known and poorly understood inflammatory patterns in osteonecrosis. *Clin Cosmet Investig Dent*. 2018;10:251–62. doi:10.2147/CCIDE.S184498
12. Lechner J, Baehr V v. Hyperactivated Signaling Pathways of Chemokine RANTES/CCL5 in Osteopathies of Jawbone in Breast Cancer Patients-Case Report and Research. *Breast Cancer (Auckl)*. 2014;889–96. doi:10.4137/BCBCR.S15119
13. Azenshtein E, Luboshits G, Shina S, Neumark E, Shahbazian D, Weil M, Wigler N, Keydar I, Ben-Baruch A. The CC chemokine RANTES in breast carcinoma progression: regulation of expression and potential mechanisms of promalignant activity. *Cancer Res*. 2002;62(4):1093–102.
14. Luettichau I v., Nelson PJ, Pattison JM, van de Rijn M, Huie P, Warnke R, Wiedermann CJ, Stahl RA, Sibley RK, Krensky AM. RANTES chemokine expression in diseased and normal human tissues. *Cytokine*. 1996;8(1):89–98. doi:10.1006/cyto.1996.0012
15. Rentzos M, Nikolaou C, Rombos A, Boufidou F, Zoga M, Dimitrakopoulos A, Tsoutsou A, Vassilopoulos D. RANTES levels are elevated in serum and cerebrospinal fluid in patients with amyotrophic lateral sclerosis. *Amyotroph Lateral Scler*. 2007;8(5):283–7. doi:10.1080/17482960701419232
16. Singh SK, Mishra MK, Eltoun I-EA, Bae S, Lillard JW, Singh R. CCR5/CCL5 axis interaction promotes migratory and invasiveness of pancreatic cancer cells. *Sci Rep*. 2018;8(1):1323. doi:10.1038/s41598-018-19643-0
17. An G, Wu F, Huang S, Feng L, Bai J, Gu S, Zhao X. Effects of CCL5 on the biological behavior of breast cancer and the mechanisms of its interaction with tumor-associated macrophages. *Oncol Rep*. 2019;42(6):2499–511. doi:10.3892/or.2019.7344
18. Bischoff SC, Krieger M, Brunner T, Rot A, Tschärner V v., Baggiolini M, Dahinden CA. RANTES and related chemokines activate human basophil granulocytes through different G protein-coupled receptors. *Eur J Immunol*. 1993;23(3):761–7. doi:10.1002/eji.1830230329
19. Stübinger S, Stricker A, Berg B-I. Piezosurgery in implant dentistry. *Clin Cosmet Investig Dent*. 2015;7:115–24. doi:10.2147/CCIDE.S63466
20. Grauvogel J, Scheiwe C, Kaminsky J. Use of piezosurgery for internal auditory canal drilling in acoustic neuroma surgery. *Acta Neurochir (Wien)*. 2011;153(10):1941-7; discussion 1947. doi:10.1007/s00701-011-1092-4
21. Crosetti E, Battiston B, Succo G. Piezosurgery in head and neck oncological and reconstructive surgery: personal experience on 127 cases. *Acta Otorhinolaryngol Ital*. 2009;29(1):1–9.
22. Spinelli G, Mannelli G, Zhang YX, Lazzeri D, Spacca B, Genitori L, Raffaini M, Agostini T. Complex craniofacial advancement in paediatric patients: Piezoelectric and traditional technique evaluation. *J Craniomaxillofac Surg*. 2015;43(8):1422–7. doi:10.1016/j.jcms.2015.07.012
23. Brisman DL, Brisman AS, Moses MS. Implant failures associated with asymptomatic endodontically treated teeth. *J Am Dent Assoc*. 2001;132(2):191–5. doi:10.14219/

jada.archive.2001.0154

24. DentaTec. Ozontherapie beim Zahnarzt – Nutzen und Anwendungsmöglichkeiten [Internet]. Available from: <https://denta-tec.com/ozontherapie-zahnarzt-nutzen-anwendungsmoeglichkeiten>

25. bti® human technology. Endoret® (prgf®) Technology [Internet]. Available from: <http://bti-biotechnologyinstitute.com/regenerative-medicine/>

26. Anitua E, Prado R, Troya M, Zalduendo M, La Fuente M de, Pino A, Muruzabal F, Orive G. Implementation of a more physiological plasma rich in growth factor (PRGF) protocol: Anticoagulant removal and reduction in activator concentration. *Platelets*. 2016;27(5):459–66. doi:10.3109/09537104.2016.1143921

27. Anitua E. Plasma rich in growth factors: preliminary results of use in the preparation of future sites for implants. *Int J Oral Maxillofac Implants*. 1999;14(4):529–35.

28. Kobayashi E, Flückiger L, Fujioka-Kobayashi M, Sawada K, Sculean A, Schaller B, Miron RJ. Comparative release of growth factors from PRP, PRF, and advanced-PRF. *Clin Oral Investig*. 2016;20(9):2353–60. doi:10.1007/s00784-016-1719-1

29. Ghanaati S, Booms P, Orlowska A, Kubesch A, Lorenz J, Rutkowski J, Landes C, Sader R, Kirkpatrick C, Choukroun J. Advanced platelet-rich fibrin: a new concept for cell-based tissue engineering by means of inflammatory cells. *J Oral Implantol*. 2014;40(6):679–89. doi:10.1563/aaid-joi-D-14-00138

30. Miron RJ, Zucchelli G, Pikos MA, Salama M, Lee S, Guillemette V, Fujioka-Kobayashi M, Bishara M, Zhang Y, Wang H-L, Chandad F, Nacopoulos C, Simonpieri A, Aalam AA, Felice P, Sammartino G, Ghanaati S, Hernandez MA, Choukroun J. Use of platelet-rich fibrin in regenerative dentistry: a systematic review. *Clin Oral Investig*. 2017;21(6):1913–27. doi:10.1007/s00784-017-2133-z

31. Miron RJ, Fujioka-Kobayashi M, Hernandez M, Kandalam U, Zhang Y, Ghanaati S, Choukroun J. Injectable platelet rich fibrin (i-PRF): opportunities in regenerative dentistry? *Clin Oral Investig*. 2017;21(8):2619–27. doi:10.1007/s00784-017-2063-9

32. Hisbergues M, Vendeville S, Vendeville P. Zirconia: Established facts and perspectives for a biomaterial in dental implantology. *J Biomed Mater Res Part B Appl Biomater*. 2009;88(2):519–29. doi:10.1002/jbm.b.31147

33. Fischer J, Benic G, Fischer Carolin. Zirkonoxidimplantate - wieso, weshalb, warum [Internet]. 2016. Available from: https://www.zmk-aktuell.de/fachgebiete/implantologie/story/zirkonoxidimplantate--wieso-weshalb-warum__4830.html

34. Sivaraman K, Chopra A, Narayan AI, Balakrishnan D. Is zirconia a viable alternative to titanium for oral implant? A

critical review. *J Prosthodont Res*. 2018;62(2):121–33. doi:10.1016/j.jpor.2017.07.003

35. Manzano G, Herrero LR, Montero J. Comparison of clinical performance of zirconia implants and titanium implants in animal models: a systematic review. *Int J Oral Maxillofac Implants*. 2014;29(2):311–20. doi:10.11607/jomi.2817

36. Özkurt Z, Kazazoğlu E. Zirconia dental implants: a literature review. *J Oral Implantol*. 2011;37(3):367–76. doi:10.1563/AAID-JOI-D-09-00079

37. Payer M, Heschl A, Koller M, Arnetzl G, Lorenzoni M, Jakse N. All-ceramic restoration of zirconia two-piece implants--a randomized controlled clinical trial. *Clinical Oral Implants Research*. 2015;26(4):371–6. doi:10.1111/clr.12342

38. Möller B, Terheyden H, Açil Y, Purcz NM, Hertrampf K, Tabakov A, Behrens E, Wiltfang J. A comparison of biocompatibility and osseointegration of ceramic and titanium implants: an in vivo and in vitro study. *Int J Oral Maxillofac Surg*. 2012;41(5):638–45. doi:10.1016/j.ijom.2012.02.004

39. Koch FP, Weng D, Krämer S, Biesterfeld S, Jahn-Eimermacher A, Wagner W. Osseointegration of one-piece zirconia implants compared with a titanium implant of identical design: a histomorphometric study in the dog. *Clinical Oral Implants Research*. 2010;21(3):350–6. doi:10.1111/j.1600-0501.2009.01832.x

40. Kohal RJ, Weng D, Bächle M, Strub JR. Loaded custom-made zirconia and titanium implants show similar osseointegration: an animal experiment. *J Periodontol*. 2004;75(9):1262–8. doi:10.1902/jop.2004.75.9.1262

41. Roehling S, Schlegel KA, Woelfler H, Gahlert M. Zirconia compared to titanium dental implants in preclinical studies--A systematic review and meta-analysis. *Clinical Oral Implants Research*. 2019;30(5):365–95. doi:10.1111/clr.13425

42. Bormann K-H, Gellrich N-C, Kniha H, Schild S, Weingart D, Gahlert M. A prospective clinical study to evaluate the performance of zirconium dioxide dental implants in single-tooth edentulous area: 3-year follow-up. *BMC Oral Health*. 2018;18(1):181. doi:10.1186/s12903-018-0636-x

43. Hashim D, Cionca N, Courvoisier DS, Mombelli A. A systematic review of the clinical survival of zirconia implants. *Clin Oral Investig*. 2016;201403-17. doi:10.1007/s00784-016-1853-9

44. Roehling S, Schlegel KA, Woelfler H, Gahlert M. Performance and outcome of zirconia dental implants in clinical studies: A meta-analysis. *Clinical Oral Implants Research*. 2018;29 Suppl 16135–53. doi:10.1111/clr.13352

45. Oliva J, Oliva X, Oliva JD. Five-year success rate of 831 consecutively placed Zirconia dental implants in humans: a comparison of three different rough surfaces. *Int J Oral Maxillofac Implants*. 2010;25(2):336–44.

46. Roehling S, Gahlert M, Janner S, Meng B, Woelfler H,

- Cochran DL. Ligature-Induced Peri-implant Bone Loss Around Loaded Zirconia and Titanium Implants. *Int J Oral Maxillofac Implants*. 2019;34(2):357–65. doi:10.11607/jomi.7015
- 47.** Janner SFM, Gahlert M, Bosshardt DD, Roehling S, Milz S, Higginbottom F, Buser D, Cochran DL. Bone response to functionally loaded, two-piece zirconia implants: A preclinical histometric study. *Clinical Oral Implants Research*. 2018;29(3):277–89. doi:10.1111/clr.13112
- 48.** Mueller CK, Solcher P, Peisker A, Mtsariashvilli M, Schlegel KA, Hildebrand G, Rost J, Liefeth K, Chen J, Schultze-Mosgau S. Analysis of the influence of the macro- and microstructure of dental zirconium implants on osseointegration: a minipig study. *Oral Surg Oral Med Oral Pathol Oral Radiol*. 2013;116(1):e1-8. doi:10.1016/j.oooo.2011.10.041
- 49.** Bormann K-H, Gellrich N-C, Kniha H, Dard M, Wieland M, Gahlert M. Biomechanical evaluation of a microstructured zirconia implant by a removal torque comparison with a standard Ti-SLA implant. *Clinical Oral Implants Research*. 2012;23(10):1210–6. doi:10.1111/j.1600-0501.2011.02291.x
- 50.** Mellinshoff. Qualität des periimplantären Weichgewebeattachments von Zirkondioxid-Implantaten (Abutments): Vergleich der Ergebnisse einer Literaturrecherche mit den Erfahrungen aus der eigenen Praxis. *Deutscher Ärzte Verlag zzi Z Zahnärztl Impl* [Internet];2010(26 (1)):8–17. Available from: <https://dr-mellinshoff.de/wp-content/uploads/dokumente/veroeffentlichungen/ZZI-2010-Periimplantaere-Weichgewebe.pdf>
- 51.** Roehling S, Astasov-Frauenhoffer M, Hauser-Gerspach I, Braissant O, Woelfler H, Waltimo T, Kniha H, Gahlert M. In Vitro Biofilm Formation on Titanium and Zirconia Implant Surfaces. *J Periodontol*. 2017;88(3):298–307. doi:10.1902/jop.2016.160245
- 52.** Holländer J, Lorenz J, Stübinger S, Hölscher W, Heidemann D, Ghanaati S, Sader R. Zirconia Dental Implants: Investigation of Clinical Parameters, Patient Satisfaction, and Microbial Contamination. *Int J Oral Maxillofac Implants*. 2016;31(4):855–64. doi:10.11607/jomi.4511
- 53.** Cionca N, Hashim D, Mombelli A. Zirconia dental implants: where are we now, and where are we heading? *Periodontol 2000*. 2017;73(1):241–58. doi:10.1111/prd.12180
- 54.** Kajiwara N, Masaki C, Mukaibo T, Kondo Y, Nakamoto T, Hosokawa R. Soft tissue biological response to zirconia and metal implant abutments compared with natural tooth: microcirculation monitoring as a novel bioindicator. *Implant Dent*. 2015;24(1):37–41. doi:10.1097/ID.0000000000000167
- 55.** Rimondini L, Cerroni L, Carrassi A, Torricelli P. Bacterial colonization of zirconia ceramic surfaces: an in vitro and in vivo study. *Int J Oral Maxillofac Implants*. 2002;17(6):793–8.
- 56.** Scarano A, Piattelli M, Caputi S, Favero GA, Piattelli A. Bacterial adhesion on commercially pure titanium and zirconium oxide disks: an in vivo human study. *J Periodontol*. 2004;75(2):292–6. doi:10.1902/jop.2004.75.2.292
- 57.** Nascimento Cd, Pita MS, Fernandes FHNC, Pedrazzi V, Albuquerque Junior RF de, Ribeiro RF. Bacterial adhesion on the titanium and zirconia abutment surfaces. *Clinical Oral Implants Research*. 2014;25(3):337–43. doi:10.1111/clr.12093
- 58.** Volz U, Schlömer G, Sidharta J, Haase St. Klinische Nachuntersuchung von Zirkondioxidkeramik-Implantaten - Funktion als Kalzium-Kathode. *Dissertation Universität Ulm*;2006.
- 59.** Apratim A, Eachempati P, Krishnappa Salian KK, Singh V, Chhabra S, Shah S. Zirconia in dental implantology: A review. *J Int Soc Prev Community Dent*. 2015;5(3):147–56. doi:10.4103/2231-0762.158014
- 60.** chemie.de. Zirkondioxid [Internet]. Available from: <https://www.chemie.de/lexikon/Zirkondioxid.html>
- 61.** Cosgarea R, Gasparik C, Ducea D, Culic B, Dannewitz B, Sculean A. Peri-implant soft tissue colour around titanium and zirconia abutments: a prospective randomized controlled clinical study. *Clinical Oral Implants Research*. 2015;26(5):537–44. doi:10.1111/clr.12440
- 62.** Delgado-Ruiz R, Romanos G. Potential Causes of Titanium Particle and Ion Release in Implant Dentistry: A Systematic Review. *Int J Mol Sci*. 2018;19(11). doi:10.3390/ijms19113585
- 63.** Safioti LM, Kotsakis GA, Pozhitkov AE, Chung WO, Daubert DM. Increased Levels of Dissolved Titanium Are Associated With Peri-Implantitis - A Cross-Sectional Study. *J Periodontol*. 2017;88(5):436–42. doi:10.1902/jop.2016.160524
- 64.** Apaza-Bedoya K, Tarce M, Benfatti CAM, Henriques B, Mathew MT, Teughels W, Souza JCM. Synergistic interactions between corrosion and wear at titanium-based dental implant connections: A scoping review. *J Periodont Res*. 2017;52(6):946–54. doi:10.1111/jre.12469
- 65.** Lechner J, Numbissi S, Baehr V v. Titanium implants and silent inflammation in jawbone—a critical interplay of dissolved titanium particles and cytokines TNF- α and RANTES/CCL5 on overall health? *EPMA J*. 2018;9(3):331–43. doi:10.1007/s13167-018-0138-6
- 66.** Berryman Z, Bridger L, Hussaini HM, Rich AM, Atieh M, Tawse-Smith A. Titanium particles: An emerging risk factor for peri-implant bone loss. *The Saudi Dental Journal*. 2019. doi:10.1016/j.sdentj.2019.09.008
- 67.** Mombelli A, Hashim D, Cionca N. What is the impact of titanium particles and biocorrosion on implant survival and complications? A critical review. *Clinical Oral Implants Research*. 2018;29 Suppl 1837–53. doi:10.1111/clr.13305
- 68.** Barão VAR, Yoon CJ, Mathew MT, Yuan JC-C, Wu CD,

- Sukotjo C. Attachment of *Porphyromonas gingivalis* to corroded commercially pure titanium and titanium-aluminum-vanadium alloy. *J Periodontol.* 2014;85(9):1275–82. doi:10.1902/jop.2014.130595
- 69.** Degidi M, Artese L, Scarano A, Perrotti V, Gehrke P, Piattelli A. Inflammatory infiltrate, microvessel density, nitric oxide synthase expression, vascular endothelial growth factor expression, and proliferative activity in peri-implant soft tissues around titanium and zirconium oxide healing caps. *J Periodontol.* 2006;77(1):73–80. doi:10.1902/jop.2006.77.1.73
- 70.** Beekmans DG. The pink and white aesthetics of a new zirconia implant. *Nederlands Tijdschrift voor Tandheelkunde.* 2018;125:389–95. doi:10.5177/ntvt.2018.07/08.18134
- 71.** Jum'ah A, Beekmans B, Wood D, Maghaireh H. Zirconia Implants: The New Arrival in the Armoury of Successful Aesthetic Implant Dentistry. *Smile Dental Journal.* 2012;7:12–26.
- 72.** Hempel U, Hefti T, Kalbacova M, Wolf-Brandstetter C, Dieter P, Schlottig F. Response of osteoblast-like SAOS-2 cells to zirconia ceramics with different surface topographies. *Clinical Oral Implants Research.* 2010;21(2):174–81. doi:10.1111/j.1600-0501.2009.01797.x
- 73.** Kniha H, Kniha K, Milz S, Hicklin S, Brägger U, Gahler M. Full ceramic monotype implants: papilla formation and retrospective clinical and radiographic 1-year results in the aesthetic zone. *Clinical Oral Implants Research;*2014(25 (Suppl.10)).
- 74.** Schwenzler N. *Zahnärztliche Chirurgie.* 4th ed. Stuttgart: Thieme; 2009. xii, 320. (Zahn-Mund-Kiefer-Heilkunde).
- 75.** Thoma DS, Lim H-C, Paeng K-W, Jung U-W, Hämmerle CHF, Jung RE. Tissue integration of zirconia and titanium implants with and without buccal dehiscence defects-A histologic and radiographic preclinical study. *Clinical Oral Implants Research.* 2019;30(7):660–9. doi:10.1111/clr.13451
- 76.** Rudelt H.G. 25 Jahre Liegedauer im Menschen [Internet]: Universität HH-Eppendorf - Uni Tokyo.
- 77.** Volz U, Henningsen A, Neuhöffer L, Stolzer C, Gosau M, Smeets R. Erfolg von dentalen Keramikimplantaten und Patientenzufriedenheit nach Sofortimplantation. *Dissertation Universität Hamburg;*2017.
- 78.** Stocchero M, Jinno Y, Toia M, Ahmad M, Papia E, Yamaguchi S, Becktor JP. Intraosseous Temperature Change during Installation of Dental Implants with Two Different Surfaces and Different Drilling Protocols: An In Vivo Study in Sheep. *J Clin Med.* 2019;8(8). doi:10.3390/jcm8081198
- 79.** Berglundh T, Abrahamsson I, Lang NP, Lindhe J. De novo alveolar bone formation adjacent to endosseous implants. *Clinical Oral Implants Research.* 2003;14(3):251–62. doi:10.1034/j.1600-0501.2003.00972.x
- 80.** Coelho PG, Suzuki M, Marin C, Granato R, Gil LF, Tovar N, Jimbo R, Neiva R, Bonfante EA. Osseointegration of Plateau Root Form Implants: Unique Healing Pathway Leading to Haversian-Like Long-Term Morphology. *Adv Exp Med Biol.* 2015;881:111–28. doi:10.1007/978-3-319-22345-2_7
- 81.** Leonard G, Coelho P, Polyzois I, Stassen L, Claffey N. A study of the bone healing kinetics of plateau versus screw root design titanium dental implants. *Clinical Oral Implants Research.* 2009;20(3):232–9. doi:10.1111/j.1600-0501.2008.01640.x
- 82.** Lemons JE. Biomaterials, biomechanics, tissue healing, and immediate-function dental implants. *J Oral Implantol.* 2004;30(5):318–24. doi:10.1563/0712.1
- 83.** Lemons JE. Biocompatibility of implant materials. *Proceedings of the 3rd Annual Indiana Conference, Indiana School of Dentistry, Medical Education Resource Program, Indianapolis, IN79–89.;*2002.
- 84.** Komet. Angle Modulation System.: zur minimalinvasiven Verbreiterung des Alveolarkamms nach Dr. Ernst Fuchs Schaller [Internet]. 2014. Available from: https://www.zwp-online.info/files/32520/410092v1_bro_de_angle-modulation.pdf
- 85.** Pommer B, Unger E, Sütö D, Hack N, Watzek G. Mechanical properties of the Schneiderian membrane in vitro. *Clinical Oral Implants Research.* 2009;20(6):633–7. doi:10.1111/j.1600-0501.2008.01686.x
- 86.** Pérez-Martínez S, Martorell-Calatayud L, Peñarrocha-Oltra D, García-Mira B, Peñarrocha-Diago M. Indirect sinus lift without bone graft material: Systematic review and meta-analysis. *J Clin Exp Dent.* 2015;7(2):e316–9. doi:10.4317/jced.51716
- 87.** Cricchio G, Palma VC, Faria PEP, Olivera JA de, Lundgren S, Sennerby L, Salata LA. Histological outcomes on the development of new space-making devices for maxillary sinus floor augmentation. *Clin Implant Dent Relat Res.* 2011;13(3):224–30. doi: 10.1111/j.1708-8208.2009.00208.x
- 88.** Mammoto A, Connor KM, Mammoto T, Yung CW, Huh D, Aderman CM, Mostoslavsky G, Smith LEH, Ingber DE. A mechanosensitive transcriptional mechanism that controls angiogenesis. *Nature.* 2009;457(7233):1103–8. doi:10.1038/nature07765
- 89.** Palma VC, Magro-Filho O, Oliveria JA de, Lundgren S, Salata LA, Sennerby L. Bone reformation and implant integration following maxillary sinus membrane elevation: an experimental study in primates. *Clin Implant Dent Relat Res.* 2006;8(1):11–24. doi: 10.2310/j.6480.2005.00026.x
- 90.** Srouji S, Ben-David D, Lotan R, Riminucci M, Livne E, Bianco P. The innate osteogenic potential of the maxillary sinus (Schneiderian) membrane: an ectopic tissue transplant model simulating sinus lifting. *Int J Oral Maxillofac Surg.* 2010;39(8):793–801. doi:10.1016/j.ijom.2010.03.009

- 91.** Srouji S, Kizhner T, Ben David D, Riminucci M, Bianco P, Livne E. The Schneiderian membrane contains osteoprogenitor cells: in vivo and in vitro study. *Calcif Tissue Int.* 2009;84(2):138–45. doi:10.1007/s00223-008-9202-x
- 92.** Miyamoto I, Yoshida K, Tsuboi Y, Iizuka T. Rehabilitation with dental prosthesis can increase cerebral regional blood volume. *Clinical Oral Implants Research.* 2005;16723–7. doi:10.1111/j.1600-0501.2005.01171.x
- 93.** Hasegawa Y, Ono T, Hori K, Nokubi T. Influence of human jaw movement on cerebral blood flow. *J Dent Res.* 2007;86(1):64–8. doi:10.1177/154405910708600110
- 94.** ADA American Dental Association. Floss and peri-implantitis risk [Internet]. 2017. Available from: https://www.ada.org/en/publications/jada/jada-specialty-scans/prosthodontics/prosthodontics_042817
- 95.** Woelber JP, Bremer K, Vach K, König D, Hellwig E, Ratka-Krüger P, Al-Ahmad A, Tennert C. An oral health optimized diet can reduce gingival and periodontal inflammation in humans - a randomized controlled pilot study. *BMC Oral Health.* 2016;17(1):28. doi:10.1186/s12903-016-0257-1

Copyright:

Any copy or reprint - also in extracts - of THE SWISS BIOHEALTH CONCEPT without the explicit and written permission of the author or SWISS BIOHEALTH AG is prohibited!

SWISS 
BIOHEALTH®
ACADEMY

SWISS BIOHEALTH AG
Brückenstrasse 15 . 8280 Kreuzlingen . Switzerland

Tel. +41 71 678 2000
Fax +41 71 678 2019
reception@swiss-biohealth.com
www.swiss-biohealth.com